Residência RP Pediátrica
Publicação Oficial da Sociedade Brasileira de Pediatria
ISSN-Online: 2236-6814

Submitted on: 12/13/2019
Approved on: 01/30/2020

CASE REPORT

Kawasaki disease with hepatic attack: case report of a patient with cholestatic syndrome

Kellen Cristina Kamimura Barbosa Silva[1], Joao Henrique Amaral Silva[2], Paula Aragão Coimbra[1], Vírgina Resende Silva Weffort[1], Valéria Cardoso Alves Cunali[1], Augusto Ventura Ceranto[1], Lucas Alves Berzotti[3], Mariana dos Santos Teixeira[3]

Keywords:
Kawasaki Disease, Mucocutaneous Lymph Node Syndrome, Cholestasis, Diagnosis.

Abstract

Kawasaki disease (KD) is characterized by vasculitis in medium-caliber arteries, mainly in children under 5-years-old. The diagnosis should be made by clinical criteria, since there is no specific laboratory test. However, some laboratory and histopathological findings may help to corroborate the diagnosis, especially in inconclusive cases. The objective of this study is to report a case of a patient with a classic DK, who developed cholestatic syndrome and lymphadenopathy, requiring laboratory and pathological investigations (lymph node and hepatic biopsies) to rule out other etiologies. The clinical case described in this study exemplifies how complementary investigation can be used to rule out other etiologies and contribute to the early diagnosis and treatment of KD, which may prevent the disease from developing with complications and severe sequelae, such as coronary aneurysms.

[1] Federal University of Triângulo Mineiro, Discipline of Pediatrics - Uberaba - Minas Gerais - Brazil.
[2] Federal University of Triângulo Mineiro, Discipline of Pathology - Uberaba - Minas Gerais - Brazil.
[3] Federal University of Triângulo Mineiro, Medicine Course - Uberaba - Minas Gerais - Brazil.

Correspondence to:
Lucas Alves Berzotti.
Federal University of Triângulo Mineiro. Av. Frei Paulino, 30 - Nossa Sra. da Abadia, Uberaba/MG, 38025-180. E-mail: lucasberzotti@gmail.com

Residência Pediátrica; 2021: Ahead of Print.
DOI: 10.25060/residpediatr-2021.v11n3-236

This work is licensed under a Creative Commons Attribution 4.0 International License.

INTRODUCTION

Kawasaki disease (KD) is characterized by vasculitis in medium-sized arteries, mainly in children under 5 years of age. The disease has a worldwide distribution, but it is much more common in children of Asian origin and in males. Genomic wide association studies (GWASs) identified the FCGR2A, BLK, CD40 and human leukocyte antigen (HLA) class II regions as susceptibility loci. The exact etiology of KD remains unknown, although several hypotheses about the role of microorganisms and superantigens have already been postulated[1].

The clinical diagnosis of KD is based on fever for at least five days and four or more of the main clinical manifestations that include: polymorphic exanthema, changes in the extremities (palmoplantar erythema and edema of the hands and feet in the acute phase; periungal desquamation in the subacute phase) , changes in the lips and oral cavity (erythema, fissures, "raspberry" or "strawberry" tongue and diffuse hyperemia of the oral and pharyngeal mucosa), bilateral non-suppurative conjunctivitis and cervical lymphadenopathy. These signs tend to appear as a sequential cascade of events and underlie the clinical diagnosis of KD[2]. The clinical course of KD can be divided into three phases:

(a) Acute phase lasting 10-14 days, characterized by fever, mucocutaneous changes, gallbladder hydrops, sterile pyuria and myocarditis;
(b) Subacute phase that lasts 2-4 weeks after the onset of symptoms and is characterized by periungal scaling and coronary abnormalities together with resolution of clinical manifestations;
(c) Convalescence phase that is characterized by the complete resolution of clinical signs and normalization of laboratory tests.

Although the main manifestations of KD are mucocutaneous alterations, this disease is characterized by systemic inflammation in medium-sized arteries and may affect other organs to a greater or lesser extent during the acute febrile phase. Depending on this degree of damage and the injured organ, the patient may have other signs, symptoms or laboratory abnormalities. In this sense, one can find clinical conditions marked by hepatitis, interstitial pneumonitis, abdominal pain, vomiting, diarrhea, gallbladder hydrops, aseptic meningitis, irritability, myocarditis, pericarditis, valvulitis, aseptic pyuria, pancreatitis and lymphadenopathy.

Although there is no pathognomonic laboratory test, certain laboratory alterations are associated with KD, for example: leukocytosis with neutrophilia and left shift, elevation of erythrocyte sedimentation rate (ESR), C-reactive protein (CRP), serum transaminases and gamma glutamyl transpeptidase (GGT), in addition to anemia, dyslipidemia, hypoalbuminemia, hyponatremia, thrombocytosis after the 1st week, sterile pyuria, cerebrospinal fluid pleocytosis and leukocytosis in synovial fluid.

Children with an unusual clinical picture are said to have atypical KD and children who have fever and less than four of the other clinical criteria are said to have incomplete KD. Due to the non-specificity of KD manifestations, especially in the first days of illness, the list of differential diagnoses is extensive. In this way, the diagnosis of KD tends to be concluded during the course of the disease[3]. However, early diagnosis should be prioritized, since only 5% of patients treated with acetylsalicylic acid (ASA) and human immunoglobulin in the first 10 days of illness will have coronary aneurysms, the most dangerous complication. On the other hand, up to 25% of untreated cases may develop this dreaded complication[4]. Careful monitoring of the patient, including serial echocardiograms, is essential for proper follow-up.

Occasionally, lymph node biopsies can be performed, especially in cases marked by fever and lymphadenopathy that make a differential diagnosis with lymphomas. Patients treated with various medications and who present laboratory alterations in liver enzymes may have a liver biopsy indicated for suspected hepatotoxicity, for example. Although at the histological level there is also no pathognomonic sign, certain nonspecific alterations in conjunction with the clinical and laboratory findings help to support the diagnosis of KD.

There are few studies in the literature on KD with correlated laboratory and pathological aspects, especially on pathologies in lymph nodes and liver. The objective of this study is to report the case of a patient with KD who presented with cholestatic syndrome and lymphadenopathy, who underwent liver and lymph node biopsies, whose histopathological findings, together with clinical and laboratory alterations, corroborated the clinical hypothesis and helped to exclude other etiologies.

CASE REPORT

Male patient, two years old, white, born and coming from Uberaba. The mother reported the onset six days ago of unmeasured fever, right cervical ganglion and diffuse rash. He sought another service two days after the onset of the condition, when hospital admission and treatment with Crystalline Penicillin was indicated. Fever persisted after 48 hours of antibiotic therapy, when conjunctival hyperemia, labial and bipalpebral edema, irritability and sweating were noted. In view of this clinical picture, it was decided to change the antibiotic therapy to Ceftriaxone associated with Oxacillin. Due to no improvement in symptoms, the patient was transferred to a tertiary university hospital.

The patient was previously healthy and had no noteworthy obstetric, family and personal pathological antecedents.

The general physical examination at admission revealed a eutrophic child, weighing 16.4 kg, axillary temperature of 37.6 °C, in good general condition, agitated, sweating, with pale mucous membranes (2+/4+), hydrated, acyanotic and

anicteric. Cervical palpation revealed adenomegaly on the right, with fibroelastic consistency, mobile, painless, without phlogistic signs measuring approximately 3x2 cm. Facial (2+/4+) and bipalpebral (3+/4+) edema was noted, in addition to hyperemia and hypertrophy of palatine tonsils, dry and swollen lips and bilateral conjunctival hyperemia. Pulmonary auscultation, as well as respiratory rate and oxygen saturation by pulse oximetry were normal. Cardiac auscultation was normal despite tachycardia with up to 120 beats per minute. The abdomen was flat, with bowel sounds present, normotensive, painless and without visceromegaly. The genitalia were normal. In the limbs, edema of the feet and hands was observed with local hyperemia and good peripheral perfusion. Neurological examination was within normal limits.

In view of this clinical picture, the diagnostic hypothesis of Kawasaki disease was raised and the course of action was hospital admission in conjunction with Rheumatology, maintenance of antibiotic therapy and request for laboratory tests (Tables 1 and 2).

The following day, the child showed complete improvement of the rash, but the other signs and symptoms persisted, including fever. Therefore, treatment with human immunoglobulin associated with AAS was initiated. In addition, echocardiography, cervical and abdominal ultrasounds, and type I urinalysis were requested for a better assessment of the condition (Tables 2 and 3).

On the 3rd day of hospitalization, the patient presented hepatomegaly on physical examination and a pattern of cholestatic syndrome was noted in laboratory tests. Therefore, renal (24-hour proteinuria) and hepatic investigations were initiated to better assess the condition. In addition, serologies were requested and causes for cholestasis were investigated.

The patient showed significant improvement in the edema and remained afebrile for 48 hours on the following days. Therefore, the dose of AAS was reduced. On the 9th day of hospitalization, lymph node and liver biopsies were scheduled to exclude other etiologies, such as lymphoma and drug hepatotoxicity. In addition, other laboratory tests were requested for better elucidation of cholestasis. Due to the high values of liver damage markers, ursodeoxycholic acid was started and the dose of Ceftriaxone was reduced, in addition to having requested a new abdominal ultrasound.

On the 12th day of hospitalization, the patient had shown significant clinical improvement and, as a result, was discharged with an outpatient return. A gradual reduction in AAS and repetition of the echocardiography two weeks after the first one were advised.

Two weeks after discharge, in an outpatient consultation, the patient was asymptomatic, with hepatomegaly in regression and laminar desquamation on the hands. She continued to use AAS and ursodeoxycholic acid. Pending test results at hospital discharge: ceruloplasmin: 31.3 mg/dL (RV: 30-70 mg/dL), copper: 161 µg (RV: 90-190 µg); FAN: 1:80 with dotted pattern; Anti-LMK: negative; anti-smooth muscle: negative; protein electrophoresis: polyclonal increase in gammaglobulins.

Liver biopsy revealed a liver fragment with preserved architecture and portal spaces slightly expanded by an inflammatory infiltrate composed of neutrophils that attacked the bile ducts and accompanied by eosinophils, lymphocytes and plasma cells, characterizing a generic histological picture of acute cholangitis (Figure 1). The lobular compartment showed mild lobular inflammation associated with mild hydropic degeneration of hepatocytes. There was no hepatocytic necrosis.

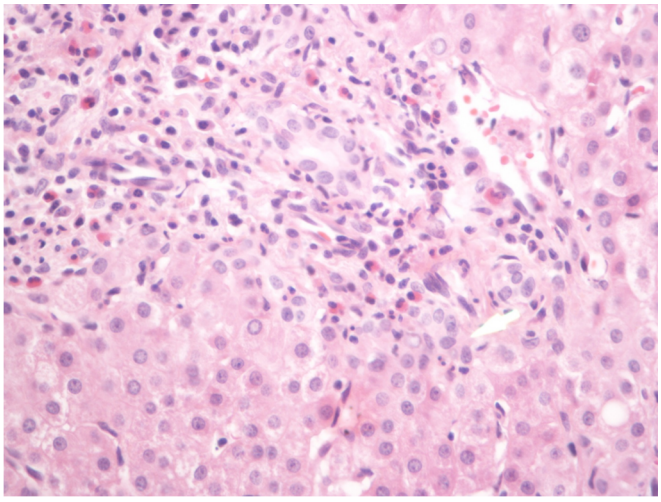

Figure 1. Liver biopsy, HE, 400x, acute cholangitis. Portal space with polymorphonuclear infiltrate involving the bile duct.

Lymph node biopsy revealed lymphatic tissue with follicular and paracortical reactive hyperplasia, prominent epithelioid venules and an area of peripheral and capsule fibrous thickening accompanied by infiltration of eosinophils, lymphocytes, plasma cells and neutrophils involving small blood vessels with endothelium swelling (Figure 2) .

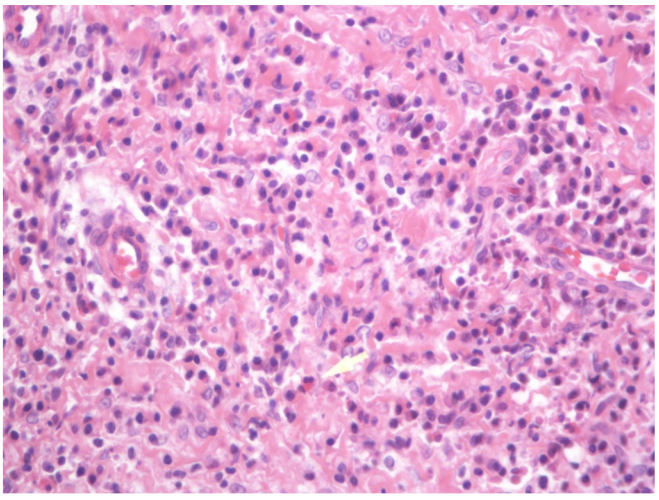

Figure 2. Lymph node biopsy, HE, 400x, peripheral area of fibrosis with lymphoplasmacytic and polymorphonuclear inflammatory infiltrate and evidence of vasculitis.

Table 1. Laboratory tests.

days of hospitalization	3rd day pre--hospitalization	1st day pre--hospitalization	1st day post--hospitalization	4th day post--hospitalization	5th day post--hospitalization	8th day post--hospitalization	11th day post--hospitalization
Red blood cells (millions/mm³)	4.3	4	4.07	3.41	3.56	4.15	
Hemoglobin (g/dL)	11.6	10	10.2	8.7	9.1	10.3	
Hematocrit (%)	35.4	31.2	28.8	24.6	25.8	31.6	
Platelets (/mm³)	397,000		309,000	304,000	308,000	689,000	
Leukocytes (/mm³)	19,000	21300	21220	17,520	17,310	8,770	
Myelocytes (%)					two	02	
Metamyelocytes (%)					9	02	
Rods (%)	18	15	05	07	13	12	
Segmented (%)	71	67	37	67	54	35	
Eosinophils (%)	0	1	02	03	3	04	
Basophils (%)	0	0	0	0	0	0	
Lymphocytes (%)	9	10	14	20	13	41	
Monocytes (%)	two	7	02	03	6	04	
C-reactive protein (CRP) (mg/dL)	142.5		30.4	10.5	7.1	1.7	0.4
Urea (mg/dL)	13.6			10.8	7.4		20.1
Creatinine (mg/dL)	0.22			0.21	0.25		0.31
Albumin (g/dL)			2.29				3.75
Aspartate transaminase (AST) (U/L)	138.9			141	136	200	177
Alanine transaminase (ALT) (U/L)	204.9			101.3	98	121	147.6
Erythrocyte sedimentation rate (ESR) (mm/h)	93				110	30	20

The patient continued using ASA until the next return visit. A new echocardiography was requested (six weeks after the first one) and the routine of collecting liver function control tests was maintained. At the time of the present report, he is well and is being followed up at the outpatient clinic.

DISCUSSION

According to data from several studies, changes in the lips and oral cavity are seen in approximately 90% of cases of KD, polymorphic exanthema in 70 to 90%, changes in the extremities in 50 to 85%, ocular changes in more than 75% and cervical lymphadenopathy in 25% to 70%.[5-7]. As a result, a considerable number of cases may not be initially diagnosed as KD, being confused with other diseases, which delays treatment and can lead to undesirable consequences. In these cases, further investigation is necessary so that other etiologies can be ruled out and allow for a timely diagnosis.

In the case presented, despite the diagnostic hypothesis of KD having been pointed out right on admission, clinical and laboratory data led to the suspicion of other etiologies, which justified the histopathological investigation.

Histological findings in lymph node and liver biopsies were nonspecific. But there is no pathognomonic histological change. Giesker et al. (1982)[8] and Katano et al. (2012)[9] cite the finding of multifocal coagulative necrosis and microthrombosis as alterations in lymph nodes of patients with KD. In the present case, no necrosis was found. On the other hand, reactive lymphatic hyperplasia, fibrosis and polymorphonuclear inflammatory infiltration compatible with KD were found. In the liver biopsy, a pattern of acute cholangitis compatible with KD was found, as described by Bader-Meunier et al. (1992)[10] The absence of hepatocytic necrosis did not favor the possibility of toxic injury.

Regarding the laboratory evaluation, the findings were also nonspecific, as there are no tests of high specificity for the disease. However, some tests can support the diagnosis, especially in inconclusive cases. Due to the systemic inflammation characteristic of KD, typical changes include elevation of acute phase reactants (CRP and ESR) and leukocytosis with a left shift. The platelet count usually increases until the second week of illness and can reach 1,000,000/mm³ (reactive thrombocytosis) in the most severe cases. Children with KD often have normocytic and normochromic anemia, with hemoglobin concentrations below average for age in half of patients within the first two weeks of illness[11]. These changes were observed in the patient under study.

The medical literature also describes other laboratory changes associated with KD. In a retrospective series of 259 patients, 45% had at least one abnormal liver function test[12]. In another case series, approximately 30% of 280 patients with KD had a mild to moderate elevation of tran-

Table 2. Laboratory tests (continued).

Days of hospitalization		2nd day post--hospitalization	5th day post--hospitalization	8th day post--hospitalization	9th day post--hospitalization	11th day post--hospitalization
International Normalized Ratio (INR)		1.2	1.2		1.09	
Patient/control APTT ratio		1.01	1		0.79	
Fibrinogen (mg/dL)		598	110		390	
Gammaglutamyl transpeptidase (GGT) (U/L)			403.8	1112		789
Alkaline Phosphatase (FA) (U/L)			550.2	1324		902.4
Total cholesterol (mg/dL)			161.2		447	
Triglycerides (mg/dL)					163	
LDL-cholesterol (mg/dL)					400,4	
HDL cholesterol mg / dl)					14	
Direct bilirubin (BD) (mg/dL)			2.05	2,068		1.21
Indirect bilirubin (BI) (mg/dL)			0.2	0.25		0.291
Total bilirubin (mg/dL)			2.3	2,321		1,504
Sodium (mEq/L)				136		140
Potassium (mEq/L)				5.69		4.58
Calcium (mg/dL)				9.53		9.42
Magnesium (mg/dL)						2.06
Phosphorus (mg/dL)						4.55
antistreptolysin O		non-reactive				
C3		Normal				
	pH	7				
	Density	1.01				
urine 1	proteinuria	2+				
	Leukocytes (cells/field)	1500				
	Red blood cells (cells/field)	750				
24-hour proteinuria (mg/day)			164			
Blood culture		Negative				Negative
cytomegalovirus IgG			Reagent			
Cytomegalovirus IgM			non-reactive			
IgG toxoplasmosis			Reagent			
IgM toxoplasmosis			non-reactive			
IgG rubella			Reagent			
Rubella IgM			non-reactive			
anti-HIV			non-reactive			
Epstein-Barr IgG virus			Reagent			
Epstein-Barr IgM virus			non-reactive			
Anti-Hepatitis A IgG			Reagent			
Anti-Hepatitis A IgM			non-reactive			

saminases due to intrahepatic congestion[13]. Several studies have reported significant changes in lipid profiles, with an increase in triglycerides and low-density lipoproteins (LDL) and a decrease in high-density lipoproteins (HDL)[1,14,15]. It was also possible to find these changes in the clinical case reported in this study.

Tabela 3. Imaging tests.

days of hospitalization	imaging exam	Result
2nd day post-hospitalization	cervical ultrasound	Bilateral cervical lymph node enlargement without signs of lymph node necrosis. The largest measuring on the right 3.0 x 2.5 cm and on the left measuring the largest 2.4 x 2.2 cm
	Total abdomen ultrasound	Without changes
9th day post-hospitalization	Total abdomen ultrasound	mild hepatomegaly
3rd day, 2 and 6 weeks after interaction	Echocardiography	Without changes. There was no evidence of changes in the proximal portion of the coronary arteries.

In short, the clinical case described in this work exemplifies how complementary investigation can be used to rule out other etiologies and contribute to the early diagnosis and treatment of KD, which can prevent the disease from evolving with serious complications and sequelae, such as coronary aneurysms.

REFERENCES

1. Son MB, Sundel RP. Kawasaki disease. In: Petty RE, Laxer RM, Lindsley CB, Wedderburn LR, eds. Textbook of pediatric rheumatology. Philadelphia: Elsevier Saunders; 2015. p. 467-83.
2. Newburger JW, Takahashi M, Gerber MA. Diagnosis, treatment, and long-term management of Kawasaki disease: a statement for health professionals from the Committee on Rheumatic Fever, Endocarditis, and Kawasaki Disease, Council on Cardiovascular Disease in the Young, American Heart Association. Pediatrics. 2004 Out;114(17):1708-33.
3. Son MBF, Newburger JW. Kawasaki disease. Pediatr Rev. 2018 Fev;39(2):78-90.
4. Newburger JW, Takahashi M, Burns JC. Kawasaki disease. J Am Coll Cardiol. 2016 Abr;67(14):1738-49.
5. Ozdemir H, Ciftçi E, Tapisiz A, Ince E, Tutar E, Atalay S, et al. Clinical and epidemiological characteristics of children with Kawasaki disease in Turkey. J Trop Pediatr. 2010 Ago;56(4):260-2.
6. Fukushige J, Takahashi N, Ueda Y, Ueda K. Incidence and clinical features of incomplete Kawasaki disease. Acta Paediatr. 1994 Out;83(10):1057-60.
7. Sung RYT, Ng YM, Choi KC, Mol GCF, Cheng YW, Ho MHK, et al. Lack of association of cervical lymphadenopathy and coronary artery complications in Kawasaki disease. Pediatr Infect Dis J. 2006 Jun;25(6):521-5.
8. Giesker DW, Pastuszak WT, Forouhar FA, Krause PJ, Hine P. Lymph node biopsy for early diagnosis in Kawasaki disease. Am J Surg Pathol. 1982 Set;6(6):493-501.
9. Katano H, Sato S, Sekizuka T, Kinumaki A, Fukumoto H, Sato Y, et al. Pathogenic characterization of a cervical lymph node derived from a patient with Kawasaki disease. Int J Clin Exp Pathol. 2012;5(8):814-23.
10. Bader-Meunier B, Hadchouel M, Fabre M, Arnoud MD, Dommergues JP. Intrahepatic bile duct damage in children with Kawasaki disease. J Pediatr. 1992 May;120(5):750-2.
11. Burns JC, Glodé MP. Kawasaki syndrome. Lancet. 2004 Ago;364(9433):533-44.
12. Eladawy M, Dominguez SR, Anderson MS, Glodé MP. Abnormal liver panel in acute Kawasaki disease. Pediatr Infect Dis J. 2011 Fev;30(2):141-4.
13. Burns JC, Mason WH, Glode MP, Shulman ST, Melish ME, Meissner C, et al. Clinical and epidemiologic characteristics of patients referred for evaluation of possible Kawasaki disease. United States Multicenter Kawasaki Disease Study Group. J Pediatr. 1991;118:680-6.
14. Newburger JW, Burns JC, Beiser AS, Loscalzo J. Altered lipid profile after Kawasaki syndrome. Circulation. 1991 Ago;84(2):625-31.
15. Cabana VG, Gidding SS, Getz GS, Chapman J, Shulman ST. Serum amyloid A and high density lipoprotein participate in the acute phase response of Kawasaki disease. Pediatr Res. 1997;42:651-5.