Residência RP Pediátrica
Publicação Oficial da Sociedade Brasileira de Pediatria
ISSN-Online: 2236-6814

Submitted on: 02/18/2020
Approved on: 04/06/2021

CASE REPORT

Cutaneous xanthomas: warning sign for hyperlipidemia

Francisca Regina Oliveira Carneiro[1], Alline Neves Mota[1], Juliana Bacellar Nunes de Brito[1], Mayara Silva Nascimento[1], Bruna Cavaleiro de Macêdo Souza[1], Josie Eiras Bisi dos Santos[2], Maria Amelia Lopes Santos[1], Franciheli Oliveira da Costa[3]

Keywords:
Xanthomatosis,
Lipid Metabolism,
Hypercholesterolemia.

Abstract

Xanthomas are tumors that occur due to the accumulation of lipids in the skin or subcutaneous tissue. Primary or secondary changes occur without lipid metabolism, activated or not associated with hyperlipoproteinemias. Whether or not driven by obesity, it is known that there has been an increase in the prevalence of metabolic syndrome in the pediatric population in recent years. Among the factors included in this syndrome are visceral obesity, atherogenic dyslipidemia, hypertension, and insulin resistance. Its main complication is the increase in cardiovascular risk. Laboratory findings of hypercholesterolemia and hypertriglyceridemia are relatively common in patients with this syndrome. Henceforward the importance of assessing indirect signs of hyperlipoproteinemias, such as eruptive xanthomas, corneal palpebral arch, xanthomas in the ankles, anterior region of the hands, and knees, especially in patients with other known risk factors. Case report: male, 13-years-old, brown, elevated changes, of varying sizes, well-defined edges with a yellowish-white surface, mandatory on the knees and elbows, with the previous diagnosis of familial hypercholesterolemia, already being followed-up with a pediatric endocrinologist.

[1] State University of Pará, Pediatric Dermatology - Belém - PA - Pará - Brazil.
[2] Paulo Azevedo Laboratory, Dermatopathology - Belém - PA - Pará - Brazil.
[3] Dermatologist, Dermatology - Belém - Pará - Brazil.

Correspondence to:
Alline Neves Mota.
State University of Pará. Rua do Úna, nº 156, Telegrafo, Belém, PA, Brazil. CEP: 66050-540. E-mail: alline_neves@hotmail.com

DOI: 10.25060/residpediatr-2022.v12n1-267

This work is licensed under a Creative Commons Attribution 4.0 International License.

INTRODUCTION

Like obesity, metabolic syndrome has become a serious problem among children and adolescents[1]. Among the factors included in this syndrome are visceral obesity, atherogenic dyslipidemia, hypertension and insulin resistance[1]. In addition to the data obtained through laboratory tests and clinical history, it is possible to evaluate the patient for the presence of dyslipidemia by looking for indirect signs, such as: cutaneous xanthomas, which preferentially affect the ankles, knees and dorsal surface of the hands, in addition to the palpebral corneal arch. , especially in those patients with known risk factors [2] . A thorough physical examination allows the detection of these signs and an early diagnosis[2].

Cutaneous xanthomas are tumors that occur due to the accumulation of lipids in the skin or subcutaneous tissue[3]. They may occur as a result of primary or secondary alterations in lipid metabolism, and may or may not be associated with hyperlipoproteinemia. They can be classified according to dermatological semiology as: verrucous, eruptive, flat, tendinous, tuberous and inflammatory[2-4]. Biopsy is only necessary in cases of diagnostic doubt[1]. In the histopathological analysis, the most common finding is the presence of foamy macrophages[3]. Treatment should preferably be done through non-drug therapy, with changes in lifestyle and patient and family understanding of the importance of this measure. Those that are extensive or that cause aesthetic and functional damage can be removed by surgical excision[2,5].

CASE REPORT

A minor, male, appears at a dermatology outpatient clinic, 13 years old, accompanied by his mother who reports the appearance of lesions on the elbows and knees at 2 years of age. He reports that over the years the lesions increased in number and size, reaching the point of invading the anterior region of the thighs. He also highlighted the fact that the lesions occasionally become swollen and reddened. At 6 years of age, therefore, already presenting the skin lesions, he was diagnosed with hypercholesterolemia. He had a family history of familial hypercholesterolemia and hypothyroidism. He was using levothyroxine 88mcg a day, atorvastatin 80mg a day and ezetimibe 10mg a day. Dermatological examination showed raised, yellow-orange plaques of varying dimensions, ill-defined limits and irregular contours, symmetrically and bilaterally distributed on the knees and elbows (Figures 1A and 1B). At the time, a sensitivity test was performed for differential diagnosis with leprosy, which was negative.

The hypotheses of cutaneous xanthoma and Virchowian-type leprosy were raised.

An incisional skin biopsy was performed, which showed anatomopathological examination, with hematoxylin and eosin staining, epidermis with discrete irregular acanthosis. In the dermis, there was an accumulation of histiocytic cells with xanthomatous cytoplasm, which dissociated non-inflamed collagen (Figure 2), compatible with a diagnosis of cutaneous xanthoma.



Figure 1. Clinical presentation. A. Yellow-orange raised plate at elbow; B. Bilateral yellow-orange raised plate in knees.

He also brought results of laboratory tests that attested: total cholesterol 567mg/dL, HDL 24mg/dL, LDL 531mg/dL, VLDL 12mg/dL and triglycerides 59mg/dL. The mother and the patient were duly oriented about the clinical and histopathological findings and both chose, at this moment, for clinical follow-up and not removal of the lesions.

DISCUSSION

The importance of early diagnosis of xanthomas in childhood by dermatologists and pediatricians is highlighted, as the prevalence of dyslipidemia in this age group is between 28 and 40% in Brazil[1], when the criterion of total cholesterol above 170mg/dL is adopted. Since the clinical expression of

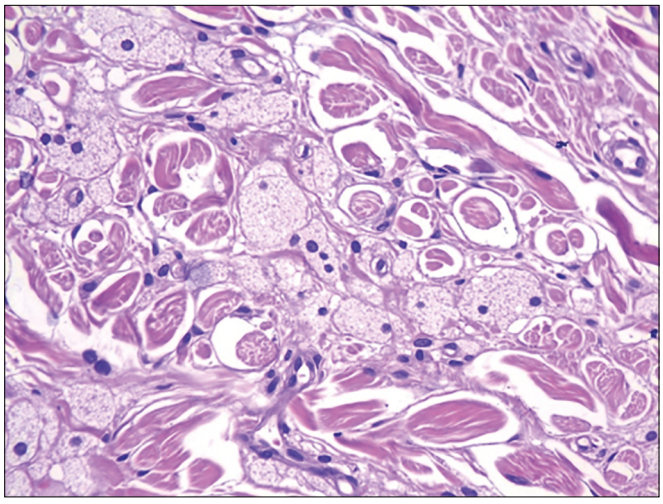

Figure 2. HE: dermis with accumulation of histiocytic cells and xanthomatous cytoplasm.

xanthoma occurs, in most cases, when there are high levels of circulating lipids, as in the present case, its suspicion and confirmation implies the investigation of metabolic disorders and comorbidities associated with lipids and cholesterol, for example. of metabolic syndrome, familial dyslipidemia, arterial hypertension and visceral obesity[5,6]. The assessment of the dyslipidemic profile allows classifying the patient with isolated hypercholesterolemia: isolated elevation of LDL-C (≥160mg/dl), associated with low HDL-C: reduction of HDL-C (men <40mg/dl and women <50mg/dl) alone or in association with an increase in LDL-C or TG, according to the V Brazilian Guideline on Dyslipidemia and Prevention of Atherosclerosis[7].

After all, the high prevalence of poor lipid profiles in children and adolescents, even without a family history of cardiovascular disease, indicates that screening should begin during childhood, as it can early identify patients at risk of prematurely developing arterial disease. coronary artery disease and will help to reduce the high mortality rates from diseases of the circulatory system[8]. In the present report, the patient is being followed up with the pediatric endocrinology team for adequate monitoring of the treatment of dyslipidemia, aiming to minimize possible complications.

Cutaneous xanthomas are indicators of these abnormalities, even though they may arise in normolipemic patients. They may present different morphologies, their clinical presentations are: verrucous, which are solitary plaques located mainly in the mouth[9]. Eruptives, which are more associated with hypertriglyceridemia, can reach 4,000mg/dL of plasma triglycerides. The planes, which are flat or slightly raised yellowish plates, with xanthelasma as the main representative. These, located in the eyelid region, may occur without any abnormalities in serum lipoproteins[3]. Tendinous xanthomas, which form along the tendons, fascia and periosteum, especially on the back of the hands, elbows, knees and ankles[4,9]. Tuberous xanthomas, which are another group of representatives of xanthomas and may appear: grouped or isolated, variable sizes, located on the surfaces of the elbows, phalangeal joints, buttocks, knees and ankles[3,4,9]. Finally, inflammatory xanthomas, which consist of secondary xanthotomization in previous scars, which is associated with the process of phagocytosis of lipids by cells of the monocytic-macrophagic system[2-4]. The patient in the present clinical case presents the tuberous form, with involvement of the elbows and knees.

The diagnosis is essentially clinical, based on the characteristic pattern of multiple yellowish or orange papules, isolated or grouped, forming papulonodular or plaque lesions, outlining lesions with a lacy or linear appearance, in predominantly extension areas[9,10]. In addition, it can be complemented with histopathological study, being found: foam cells, compatible with macrophages that contain lipids and are characteristic of xanthomas, found in the dermis and its cytoplasm of foamy pink or granular color, containing cholesterol (free and esterified), phospholipids and triglycerides[9]. Description is compatible with the histopathological findings presented in this clinical case. Thus, it is necessary to emphasize the importance of clinical recognition of xanthomas, since it is an alert to the possibility of an underlying metabolic disorder not yet diagnosed[5].

Treatment is focused on the underlying clinical-endocrinological condition[5,11]. Non-drug therapies such as regular physical exercise and dietary adjustments (hypocholesterolemic). Multiprofessional monitoring should be encouraged, especially with nutritional and sports support[5]. Drug therapies have been reported in the literature with a good response to the use of fibrates[11]. Surgical treatment is characterized as an alternative for patients who complain about aesthetic aspects, through surgical removal of lesions, laser ablation, dermabrasion, cryotherapy and chemical cauterization[2,3]. The disappearance of xanthomas occurs slowly and depends on the reduction to normal or close to normal levels of triglycerides, and clinical dermatological recurrence is not uncommon if there is metabolic deterioration and return to high levels of triglycerides[9,11].

CONCLUSION

In view of the above, it is important to pay attention to the finding of cutaneous xanthomas during the physical examination. Its presence makes it imperative to investigate serum lipoproteins. This measure helps in early diagnosis and intervention, so relevant in those conditions that culminate in unfavorable cardiovascular outcomes. Thus, requiring early intervention with changes in life habits, and even drug therapy in severe or refractory cases.

REFERENCES

1. Cook S, Kavey REW. Dyslipidemia and pediatric obesity. Pediatrician Clin N Am [Internet]; [Accessed: 2011, December 1]; 58 (6):1363-73. Available at: https://www.pediatric.theclinics.com/article/S0031-3955(11)00107-6/abstract

2. Pergher RNQ, Melo MED, Halpern A, Mancini MC. Is the diagnosis of metabolic syndrome applicable to children?. J Pediatr [Internet]. 2010 Apr ; [Accessed: 2010, April 1]; 86(2):101-8. Available at: https://www.scielo.br/scielo.php?pid=S0021-75572010000200004&script=sci_arttext
3. Junior WB, Di Chiacchio N, Creator PR. Textbook of Dermatology. São Paulo: Atheneu; 2014.
4. Rivitti EA. Dermatology of Sampaio and Rivitti. 4th ed. São Paulo: Medical Arts; 2018
5. Brazilian Society of Pediatrics (SBP). Scientific Department of Nutrology. Guidance manual – obesity in childhood and adolescence. 3rd ed. São Paulo: Brazilian Society of Pediatrics (SBP); 2019
6. Marques SA, Pelafsky VPC, Marques MEA. Eruptive xanthoma: case report with exuberant clinical and laboratory manifestations. Diagnosis Treatment.[Internet]; [Accessed: 2009, March, 16]; 14(2):70-3. Available: http://files.bvs.br/upload/S/1413-9979/2009/v14n2/a0005.pdf
7. Xavier HT, Izar MC, Faria Neto JR, Assad MH, Rocha VZ, Sposito AC, et al. V Brazilian guideline on dyslipidemias and prevention of atherosclerosis. Arq Bras Cardiol [Internet]; [Accessed: 2013, October, 1]; 101(4 Suppl 1):1-20. Available at: https://www.scielo.br/scielo.php?pid=S0066--782X2013004100001&script=sci_arttext
8. Araújo ES, Costa SHN. Studies on dyslipidemia in children in Brazil: literature review. Arch Bras Cardiol. 2012;1-11.
9. Sacchi AE, Olivares L, Leiro V. Xanthomatosis and dyslipoproteinemias. Dermatol Argent. 2013;19(3):174-82.
10. Silva DMD, Chacha JJ, Wiziack NC, Takita LC, Hayashi FK. Idiopathic diffuse normolipemic plane xanthoma with hypersplenism. An Bras Dermatol [Internet] ; [Accessed: 2010, February 6]; 85(1):73-6. Available at: https://www.scielo.br/scielo.php?pid=S0365-05962010000100010&script=sci_arttext&tlng=pt
11. Bárzaga V, Oscar H, Cabrera RA, Sánchez LL. Eruptive xanthomas associated with type II diabetes mellitus and hypertriglyceridemia: a case report. Arch Med Camaguey [Internet]; [Accessed: 2008, February, 13] ; 13(2). Available at: http://scielo.sld.cu/scielo.php?script=sci_arttext&pid=S1025-02552009000200015