Residência RP Pediátrica
Publicação Oficial da Sociedade Brasileira de Pediatria

Submitted on: 04/27/2020
Approved on: 06/05/2020

CASE REPORT

Hypertrofic pyloric stenosis in a premature newborn: case report and brief review

Daniel Albiero Pielak[1], Luiz Felipe Ferreira Ribeiro[1], Samara Vilela da Mata Nunes[1], Bruna Diniz Neiva[1], Marina Rodoy Bertol[1], Milene de Moraes Sedrez Rover[1], Carolina Talini[1]

Keywords:
Pyloric Stenosis, Hypertrophic, Infant, Newborn, Diseases, Premature Birth.

Abstract

Hypertrofic pyloric stenosis is one of the main causes of non-biliary vomiting in newborn and is typically found between 3 and 4 weeks old babies. It is rarely found in early neonatal period., especially in prematures. The case here reported is a male, premature born with 34 gestational weeks, with 3180 grams of weight admitted to the neonatal ICU due to respiratory discomfort and prematurity. With 3 days old presented non-biliary vomiting, abdominal distention and difficulty to feed. Radiography demonstrated hyperdistended stomach. Remained symptomatic for the next 48 hours and a contrast study demonstrated slow gastric emptying and pyloric and duodenal narrowing. As the findings suggested duodenal obstruction exploratory laparotomy was indicated. During surgery hypertrofic pyloric stenosis was found with no signs of malrotation or duodenal obstruction. Pyloromiotomy was performed and 12 hours after surgery oral feeding was restarted. Patient presented good outcome, is now with 9 months old, good development and adequate weight gain. As demonstrated, even though it is an unusual cause, hypertrofic pyloric stenosis must be considered as an important differential diagnosis when facing a digestive obstruction in newborn.

[1] Hospital Universitário do Oeste do Paraná (HUOP), Department of Pediatrics & Pediatric Surgery - Cascavel - Paraná - Brazil.

Correspondence to:
Carolina Talini.
University Hospital of the West of Paraná (HUOP). Av. Tancredo Neves, 3224 - Santo Onofre, Cascavel - PR, Brasil. CEP: 85806-470. E-mail: caroltalini@yahoo.com.br

Residência Pediátrica; 2022: Ahead of Print. DOI: 10.25060/residpediatr-2022.v12n2-302

This work is licensed under a Creative Commons Attribution 4.0 International License.

INTRODUCTION

Hypertrophic pyloric stenosis (HPS) is the most common neonatal surgical disorder, with a prevalence of approximately 2 for every 1,000 live births[1]. It is characterized by idiopathic hypertrophy of the pyloric muscles and results in partial obstruction of the gastric outlet[2]. It was initially described as an uncommon condition in preterm newborns, but improvements in patient support and survival have allowed a clearer definition of the patterns of occurrence of the disease and demonstrated that preterm birth may be a risk factor for the development of HPS[3]. However, the clinical symptoms of this condition tend to appear later in preterm neonates when compared to full-term babies[4].

This article aimed to describe an uncommon case of early HPS affecting a three-day-old preterm neonate born after 34 weeks of gestation.

CASE REPORT

A preterm male baby born after 34 weeks of gestation had an Apgar score of 7/8 and weighed 3180 grams at birth. His mother had a history of gestational diabetes, which explained the categorization of the baby as large for gestational age (LGA). No complications were registered during pregnancy. The mother did not have infections or take antibiotics during prenatal care; she was not an active smoker and this was her first child. After birth, the newborn was taken to the neonatal intensive care unit (NICU) in respiratory distress. Management did not require invasive ventilation. The baby was only breastfed at first, but required supplementation with formula milk due to low breast milk supply. Three days after birth, the newborn started having episodes of nonbilious vomiting, upper abdominal bloating, and difficulty feeding. Abdominal X-ray images showed a large gastric bubble. The patient was kept fasting and within the next 48 hours attempts to feed the baby led to the resumption of symptoms. Contrast-enhanced imaging of the bowel revealed delayed gastric emptying and tapering in the pyloric portion and at the start of the duodenum (Figure 1).

Findings suggestive of duodenal obstruction prompted the indication of an exploratory laparotomy. Signs of hypertrophic pyloric stenosis were observed during the procedure, accompanied by an intact patent duodenum without signs of intestinal malrotation. A Fredet-Ramstedr pyloromyotomy was performed and 12 hours after surgery breast milk was reintroduced with good acceptance. The patient improved and was discharged four days after the procedure, nine days after birth. The infant is nine months old today. He has been brought regularly to follow-up visits. The infant is developing well, has gained weight and has not had issues feeding since the procedure.

DISCUSSION

First described by Hirschprung in 1888, HPS is primarily treated with surgery. Ramstedt originally described the procedure, considered the gold standard therapy to this day, in 1912[5]. As illustrated in this case report, it preferentially affects male individuals at a ratio of 4 to 6:1[5]. The exact etiology is unknown, with the causes of the disease probably being multifactorial[2].

The disease usually affects newborns aged between two and 12 weeks, with incidence peaking at five weeks of age[6]. Although rare, reports of the disease occurring on the first day after birth have been published[7]. Our patient developed symptoms earlier than the average patient in the literature. Another element to consider is that, in addition to experiencing symptoms early on, our patient was a preterm infant. Previously published studies and a large retrospective cohort study performed in 2015 concluded that the chronologic age at which symptoms occur usually increases as gestational age at birth decreases[3]. Apparently, HPS in preterm infants is related to degree of development of the digestive tract, in such a way that preterm infants tend to present symptoms at a later moment when compared to full term babies[4], differently from what happened in our case report.

A number of risk factors tied to the development of this condition have been established, such as male sex, family history of disease, maternal smoking, first child, history of use of erythromycin and macrolides, and feeding with formula milk[8,9]. Feeding with breast milk only is a proven protective factor against HPS[10]. Since preterm infants on average to stay in intensive care for longer, exposure to some of these risk factors may increase the risk of HPS[8]. Rusk factors male sex, being the first child, prematurity, and supplementation with formula milk were present in our patient.

Classical symptoms include post-feeding projectile nonbilious vomiting[2], possibly accompanied by weight loss and dehydration with severe metabolic alkalosis when patients are undiagnosed or not treated early on[8]. Physical examination often involves the identification of a palpable pyloric olive in the epigastrium, a sign of pyloric hypertrophy that carries a positive predictive value of 99% for HPS[2]. The only signs and symptoms our patient presented were vomiting and upper abdominal bloating.

The gold standard in diagnostic imaging is abdominal ultrasound scans showing pyloric wall thickening greater than 3mm in a transverse view (more specific measurement) and pylorus elongation greater than 15 mm in a longitudinal view[4,9]. In abdominal ultrasound imaging, the orientation of the superior mesenteric artery and vein as a sign or intestinal malrotation is an important element in differential diagnosis in patients with HPS[9]. Contrast-enhanced X-ray images of the upper digestive tract can also show an elongated pylorus with a narrow lumen and a serrated outline on the duodenal bulb[9]. We first suspected the patient had a duodenal obstruction, and thus chose contrast-enhanced X-ray, which revealed findings consistent with a condition requiring surgery, although a diagnosis of HPS was not defined at this time.

HPS is a medical emergency, not a surgical emergency. Before surgery, patients must be stabilized and offered proper fluid replacement. Electrolytic anomalies are frequent and dangerous, recurring vomiting leads to hypokalemic and hypochloremic metabolic alkalosis, a condition that must be promptly addressed[2]. As mentioned previously, extramucosal pyloromyotomy, also known

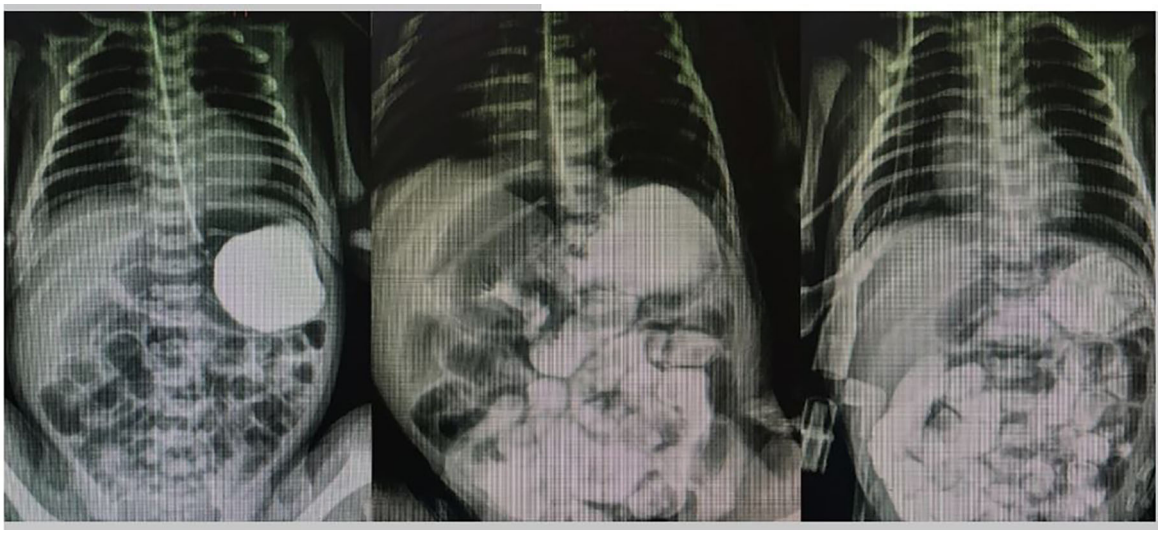

Figure 1. Serial bowel transit images.

as Fredet-Ramstedt pyloromyotomy, is the procedure of choice. It is traditionally performed via a laparotomy with a right subcostal incision, or with a minimally invasive approach through an umbilical incision, or with video laparoscopy[1,2,5]. The main intraoperative complications are mucosal perforation, more commonly seen in areas close to the duodenal border; and incomplete pyloromyotomy, more commonly seen in the gastric border of the pyloric incision, which may cause early recurrence of symptoms[2]. The patient operated in our service did not have complications during surgery or short- or long-term adverse events. He recovered well after surgery and improved after discharge.

Morbidity appears to me more significant in preterm than full-term infants, possibly on account of the greater incidence of chronic pulmonary and heart disease in the first group of subjects[3]. Mortality is low, around 1%, and has been associated with delayed diagnosis leading to severely depleted newborns not adequately stabilized before surgery[5].

CONCLUSION

Although rare and occasionally a subject of surprise among neonatal care teams, hypertrophic pyloric stenosis is an important condition in the differential diagnosis of newborns with upper digestive tract obstruction.

REFERENCES

1. Zhu J, Zhu T, Lin Z, Qu Y, Mu D. Perinatal risk factors for infantile hypertrofic pyloric stenosis: a meta-analysis. J Ped Surg. 2017;52:1389-97.
2. El-Gohary Y, Abdelhafeez A, Paton E, Gosain A, Murphy AJ. Pyloric stenosis: an enigma more than a century after the first successful treatment. Pediatr Surg Int. 2018;34(1):21-7.
3. Costanzo C, Vinocur C, Berman L. Prematurity Affects Age of Presentation of Pyloric Stenosis. Clin Pediatr (Phila). 2017; 56(2):127-31.
4. Katumba-Lunyenya J, Misra I, Chawda N, Erumbala G. Can you be too premature to develop pyloric stenosis? BMJ Case Rep. 2012;24:1-3. DOI: 10.1136/bcr-2012-006592.
5. Ndongo R, Tolefac PM, Tambo FFM, Abanda MH, Ngowe MN, Fola O, et al. Infantile hypertrophic pyloric stenosis: a 4-year experience from two tertiary care centres in Cameroon. BMC Res Notes. 2018;11(1):1-5. DOI: 10.1186/s13104-018-3131-1.
6. Kapoor R, Kancherla V, Cao Y, Oleson J, Suhl J, Canfield MA, et al. Prevalence and descriptive epidemiology of infantile hypertrophic pyloric stenosis in the United States: A multistate, population-based retrospective study, 1999-2010. Birth Defects Res. 2019;111(3):159-69.
7. Ali KI, Haddad J. Early Infantile Hypertrophic Pyloric Stenosis: Surgery at 26 Hours of Age. Eur J Pediatr Surg. 1996;6(4):233-4.
8. Stark CM, Rogers PL, Eberly MD, Nylund CM. Association of prematurity with the development of infantile hypertrophic pyloric stenosis. Pediatr Res. 2015; 78(2):218-22.
9. Naffaa L, Barakat A, Baassiri A, Atweh LA. Imaging Acute Non-Traumatic Abdominal Pathologies in Pediatric Patients: A Pictorial Review. Radiol Case Rep. 2019;13(7):29-43.
10. Ezomike UO, Ekenze SO, Amah CC, Nwankwo EP, Obianyo NE. Infantile Hypertrophic Pyloric Stenosis - Our Experience and Challenges in a Developing Country. Afr J Paediatr Surg. 2018;15(1):26-30.