Residência RP Pediátrica
Publicação Oficial da Sociedade Brasileira de Pediatria

Submitted on: 11/06/2020
Approved on: 20/09/2020

CASE REPORT

A patient with primary ciliary dyskinesia associated with Kartagener syndrome

Giulia Beatriz Correia Matos[1], Mariana Soares Faria[1], Tiago Almeida Costa[1], Larissa Dantas Sobral[1], Isabella Santana Santos Chagas[2], Mariana Soares Faria[1]

Keywords:
Respiratory Disease, Ciliary Motility Disorders, Kartagener Syndrome, Dextrocardia, Sinusitis.

Abstract

Introduction: Primary ciliary dyskinesia is a condition that causes motile cilia dysfunction, which translates into reduced or uncoordinated motility of the cilia present in the respiratory epithelium. Impaired mucociliary function in the respiratory tract makes patients more susceptible to infection and causes stasis of recurrent secretions and secretory cell hyperplasia in later stages of involvement. **Case report:** This article describes the case of a patient with primary ciliary dyskinesia associated with Kartagener syndrome. All significant elements that led to the early diagnosis of the condition (the patient was aged less than 3 years) are discussed, including signs and symptoms, imaging findings, and genetic tests. **Discussion:** Half of the patients with this autosomal recessive disease also present with Kartagener syndrome, a condition characterized by chronic sinusitis, situs inversus, and bronchiectasis. Patients with the disease often develop a persistent cough, dyspnea, otitis media, mouth breathing, nasal polyps, and present with heart defects. Differential diagnosis for ciliary dyskinesia is important so that possible additional damage to the patient's health arising from the condition is considered. Medical examination along with X-ray images, computed tomography scans, and cytology tests are the main tools used in the analysis of structural variations. This condition is usually diagnosed in later stages of development. Therefore, studies are needed to aid in the early diagnosis of the disease and preserve patient lung function.

[1] Tiradentes University, School of Medicine - Aracaju - Sergipe - Brazil.
[2] HU/UFS/EBSERH, Pulmonologist - Aracaju - Sergipe - Brazil.

Correspondence to:
Mariana Soares Faria.
Universidade Tiradentes. R. Lagarto, 236 - Centro, Aracaju - SE, Brazil. Zip Code: 49010-390. E-mail: marianasfaria.msf@gmail.com

Residência Pediátrica; 2022: Ahead of Print. DOI: 10.25060/residpediatr-2022.v12n2-330

This work is licensed under a Creative Commons Attribution 4.0 International License.

INTRODUCTION

Primary ciliary dyskinesia (PCD) is a genetic disorder that compromises ciliary structure and/or function[1]. The defect arises from a deficit in the number of dynein arms, which results in reduced or uncoordinated motility of the cilia in the respiratory epithelium[1]. Consequently, mucociliary clearance is impaired in the respiratory tract of patients with the disease, which makes them susceptible to infection, stasis of recurrent secretions, and secretory cell hyperplasia in later stages of involvement. PCD is an autosomal recessive disease in which proteins involved in the structure and motility of the cilia of the respiratory epithelium are altered[2]. Half of the patients with PCD also have Kartagener syndrome (KS), a condition characterized by the classic triad dextrocardia, bronchiectasis, and chronic rhinosinusitis[3].

Other findings may include otitis media, nasal polyps, and heart malformations[4]. Patients with this condition require specialized care[5]. Analysis of patient medical history, screening tests (exhaled nitric oxide and saccharin test), specific function tests (ciliary beat frequency and waveform), ultrastructure analysis, immunofluorescence, and genetic tests are in order[4]. Imaging tests that aid diagnosis include ultrasound, plain X-ray images, and computed tomography. Differential diagnosis for ciliary dyskinesia is important so that possible additional damage to the patient's health arising from the condition is considered.

Few countries possess records of prevalence, diagnosis, and prognosis of PCD, and published data present significant variation. Prevalence ranges from 1:2200 to 1:40000, with increased rates in cases of marital consanguinity. Evidence suggests that diagnosis is often performed in later stages of involvement, mainly due to failure to recognize the disease and the lack of sophisticated technical investigative resources.[4] In Brazil, most pulmonology services lack the resources to investigate cases of PCD, which leads to few cases of the disease being described in the literature[4,6] and lack of significant data on the prevalence of PCD in Brazil.

This article describes the case of a patient with PCD associated with KS. All significant elements that led to the early diagnosis of the condition (the patient was aged less than 3 years) are discussed, including signs and symptoms, imaging findings, and genetic tests.

CASE REPORT

A female patient aged three years with a history of dyspnea and wheezing within 24 hours of birth was admitted to the maternity hospital of Estância, Sergipe, Brazil. A chest X-ray was ordered and she was diagnosed with pneumonia. The patient was hospitalized for 14 days and prescribed treatment with antibiotics. She developed recurrent respiratory infections and had to be hospitalized another four times in five months in the same town.

The patient was then taken to Aracaju, the State Capital of Sergipe, to see an allergist, who suspected she had dextrocardia. Echocardiography confirmed the suspicion, and abdominal ultrasound images and computed tomography (CT) scans revealed she had situs inversus totalis. The CT report described fibroatelectasis in the inferior lingular segment of the right lung, diffuse bronchial wall thickening, and non-calcified nodular opacities of up to 0.4 cm in both lungs. The patient was referred to the Sergipe University Hospital.

A genetic test (gold standard) found she had Kartagener Syndrome. The test report specified she had a pathogenic homozygous mutation in exon 18 of gene CCDC40. Her mother had not been exposed to teratogens during pregnancy. The patient has been followed for three years in the pediatric pulmonology, pediatric gastrology, and general pediatrics outpatient clinics of the University Hospital and at the genetics clinic of the Federal University of Sergipe at Lagarto.

Treatment currently provided to the patient was designed to prevent infection and future development of bronchiectasis. She has had respiratory physiotherapy sessions and a prescription for the following drugs: budesonide and formoterol, azithromycin, and inhaled budesonide. She has also been given nasal washes regularly and hypertonic saline nebulization. She was prescribed lactulose solution for bowel constipation.

The patient has improved to satisfaction, with good weight and height gains based on her growth charts and z-score, and has not needed additional hospitalization.

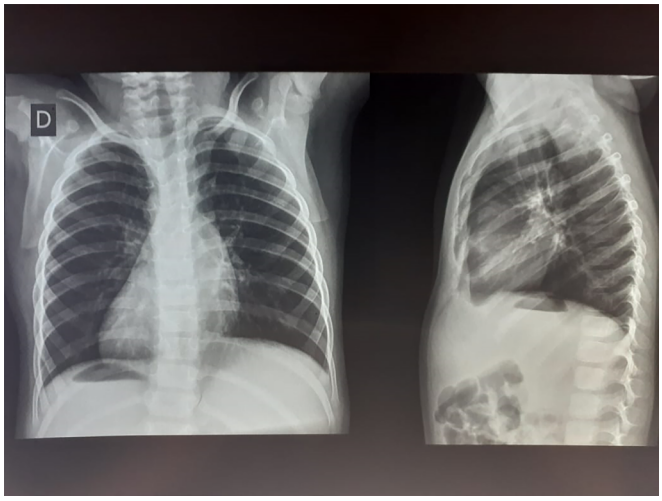

Figure 1. PA Chest X-ray showing dextrocardia. A gastric bubble is seen to the right, along with an elevated left diaphragmatic dome, and a liver with signs consistent with dullness to percussion to the left.

DISCUSSION

PCD is not a widely recognized condition. Therefore, the presence of signs applicable to all ages (general signs) and specific signs applicable to specific ages must raise suspicion of PCD associated with KS[4].

General signs include situs anomalies (dextrocardia, isomerism) and family history of ciliopathy[4]. Only half of the patients with PCD develop all symptoms, in a condition called complete KS; the other half does not present with situs inversus, and have a condition named incomplete KS. Physical examination and plain X-ray images found the patient had dextrocardia. Abdominal ultrasound examination performed at a later moment confirmed she had situs inversus totalis. The patient did not have a family history of the disease, but had a mutation on exon 18 of gene CCDC 40.

Specific signs are divided into antenatal (situs anomalies seen on ultrasound examination), neonatal (rhinorrhea since birth, neonatal respiratory distress without an apparent cause affecting a full-term newborn, abnormal situs, complex congenital heart disease - particularly laterality disorders - and family history of disease), childhood (chronic productive cough, atypical asthma non-responsive to treatment, idiopathic bronchiectasis, rhinosinusitis - presence of nasal polyps is rare - agenesis of one or more sinuses, severe otitis media with effusion, prolonged otorrhea after the insertion of ventilation tubes, and family history of disease), and adult (all infant signs plus male infertility due to immotile sperm, ectopic pregnancy, and subfertility due to static cilia in the fallopian tubes) presentation of symptoms. Prenatal tests did not find any anomalies in our patient, although she experienced respiratory distress after birth and had dextrocardia (neonatal signs), productive cough, rhinosinusitis and asthma (childhood signs). Late manifestations such as bronchiectasis and infertility were not detected in our patient, probably because of her young age and the administration of proper treatment.

Patients with chronic recurrent infection of the respiratory tract should be suspected for PCD in differential diagnosis. Cystic fibrosis is the first condition to be ruled out when a patient is suspected for PCD[7], since it also presents with mucociliary disorder and infertility. Congenital and/or acquired cellular and humoral immunodeficiency should also be considered, since they are often linked to respiratory infection and may mimic the symptoms of PCD[7].

Since PCD is a condition with significant genetic variability, each patient may develop different symptoms[4]. However, the later individuals with the disease are diagnosed and treatment is started, the more complications such as growth deficit, bronchiectasis, digital clubbing, subfertility and infertility, severe lung disease, respiratory failure, pulmonary hypertension, and right heart failure may develop[4,8]. Few studies have looked into the prognosis of individuals with PCD.

In conclusion, PCD is a rare condition with few articles discussing it in medical literature. More publications are needed so that healthcare workers become more aware of its signs and symptoms and able to diagnose patients in the early stages of disease, mainly when dextrocardia is not present. The probability of diagnosing individuals with PCD increases when patients present with chronic respiratory infection since birth and situs inversus.

REFERENCES

1. TOLEDO, Maristella F.; FV, Adde. Discinesia ciliar primária na infância. J Pediatr (Rio de J), v. 76, n. 1, p. 9-16, 2000.
2. Kuehni CE, Frischer T, Strippoli MP, Maurer E, Bush A, Nielsen KG, et al. Factors influencing age at diagnosis of primary ciliary dyskinesia in European children. Eur Respir J. 2010;36:1248-58.
3. DE QUEIROZ, Ana Paula Lima et al. Tradução do questionário de qualidade de vida para pacientes adultos com discinesia ciliar primária no Brasil. Jornal Brasileiro de Pneumologia, v. 45, n. 3, p. e20170358-e20170358, 2019.
4. Olm Mary Anne Kowal, Caldini Elia Garcia, Mauad Thais. Diagnóstico de discinesia ciliar primária. J. bras. pneumol. [Internet]. 2015 June.
5. Barbato A, Frischer T, Kuehni CE, Snijders D, Azevedo I, Baktai G, et al. Primary ciliary dyskinesia: a consensus statement on diagnostic and treatment approaches in children. Eur Respir J. 2009;34:1264-76.
6. Olm MA, Kögler JE Jr, Macchione M, Shoemark A, Saldiva PH, Rodrigues JC. Primary ciliary dyskinesia: evaluation using cilia beat frequency assessment via spectral analysis of digital microscopy images. J Appl Physiol (1985). 2011;111:295-302.
7. CAMPOS, Sarah Emanuelle Viana. Discinesia ciliar primária: Relato de Caso. 2016.
8. GOUVEIA, Gina Patrícia Paradela. Discinésia ciliar primária: novos conceitos na abordagem diagnóstica. 2017. Tese de Doutorado.