Residência RP Pediátrica
Publicação Oficial da Sociedade Brasileira de Pediatria
ISSN-Online: 2236-6814

Submitted on: 05/28/2020
Approved on: 06/05/2020

CASE REPORT

Osteoporosis and laryngeal involvement secondary to juvenile idiopathic arthritis: case report

Rayana Camille Leichtweis de Oliveira[1], Angélica Luciana Nau[1], Rafaela Rossi Assmann[1], Marcia Bandeira[2]

Keywords:
arthritis,
juvenile,
osteoporosis,
arytenoid cartilage.

Abstract

Objective: Juvenile idiopathic arthritis (JIA) is a systemic inflammatory condition and the most common chronic rheumatological disease in childhood. Among complications, patients may have osteoporosis induced by treatment with glucocorticoids or the evolution of the disease. Another rare complication is the involvement of laryngeal cartilage, which may present with stridor or respiratory failure. The purpose of this report is to present a case of JIA with osteoporosis and laryngeal manifestations. **Case Report:** Female, 15 years old, diagnosed with JIA 12 years ago with irregular treatment that evolved with severe and limiting disease. The patient had stridor and dyspnoea. Laryngoscopy showed involvement of arytenoid cartilage requiring tracheostomy. In addition, the patient was diagnosed with osteoporosis and bilateral coxarthrosis, requiring bilateral total hip arthroplasty.

[1] Pequeno Príncipe Hospital, Pediatrics - Curitiba - Paraná - Brazil.
[2] Pequeno Príncipe Hospital, Pediatric Rheumatology - Curitiba - Paraná - Brazil.

Correspondence to:
Rayana Camille Leichtweis de Oliveira.
Hospital Pequeno Príncipe. Rua Desembargador Motta, nº 1070, Água Verde, Curitiba, PR, Brazil. CEP: 80250-060. E-mail: rayleichtweis@gmail.com

Residência Pediátrica; 2022: Ahead of Print.
DOI: 10.25060/residpediatr-2022.v12n2-317

This work is licensed under a Creative Commons Attribution 4.0 International License.

INTRODUCTION

Juvenile Idiopathic Arthritis (JIA) makes up a heterogeneous group of autoimmune diseases, characterized by chronic arthritis and systemic manifestations, being the most common rheumatic disease in children[1,2]. It can be classified into seven subtypes: oligoarticular JIA, seropositive polyarticular, seronegative polyarticular, systemic, enthesitis-related arthritis, psoriatic and undifferentiated juvenile arthritis. Systemic JIA manifests as persistent arthritis and intermittent fever for at least two weeks, associated with skin rash, generalized lymph node enlargement, hepatosplenomegaly and/or serositis[3].

Patients may develop osteoporosis due to disease activity and treatment involving the use of glucocorticoids[4-6]. The diagnosis and investigation of osteoporosis include a history of fractures in long bones or vertebrae, low bone mineral density and laboratory tests that are markers of bone formation and resorption[5]. Imaging tests, such as radiography, are relevant in the evaluation of vertebral morphology, but loss of height of vertebral bodies is a late finding[7]. In children, the diagnosis of osteoporosis is a challenge because physical examination is usually normal, although some patients have pain, changes in joint mobility, spinal and/or chest deformities, or short stature[8].

Laryngeal involvement, although rare, may be present in JIA. One of the most involved regions is the cricoarytenoid cartilage, which is important for breathing and phonation, which impairment can manifest as hoarseness, pharyngeal globus sensation, difficulty in speech and swallowing[1]. In children, the involvement of this cartilage can be even more severe, manifesting with stridor and dyspnea, and, although rare, it can be a life-threatening condition[9].

The objective of this study is to describe the case of a patient who developed osteoporosis secondary to the activity and treatment of JIA, in addition to severe involvement of the cricoarytenoid cartilage.

Female patient, 15 years old, diagnosed with systemic JIA at 3 years of age, when she presented with pericardial effusion with cardiac tamponade and fluid with inflammatory characteristics associated with a history of previous arthritis. He remained in irregular follow-up until the age of 6 years, using corticosteroids (prednisolone 1mg/kg/day), and when she started the follow-up at our service, she had severe and limiting disease, with significant joint conditions, difficulty in walking, equinus foot , lower limb dysmetria, hip dislocation, with subsequent diagnosis of osteopenia in the spine, hands, wrists, ankles, knees and feet, in addition to bilateral coxarthrosis.

The patient again maintained irregular follow-up, not returning to consultations for a year, when she presented bone pain in the thoracolumbar spine, associated with difficulty walking, low-appetite and fever. Investigation with MRI of the spine revealed vertebral fractures, and the hypothesis of a myeloproliferative process was ruled out after bone marrow aspirate and lumbar vertebral body biopsy, both normal. Bone densitometry was performed (Table 1), with a diagnosis of low lumbar bone mass - osteoporosis secondary to the activity and treatment of the disease. Then, treatment with calcium carbonate, cholecalciferol and sodium alendronate was started, the latter being replaced by intravenous pamidronate after 1 year of use, since the patient had significant pain in the right lower limb with muscular dystrophy, thoracic deformity, limitation of in wrists, elbows, hips and knees.

On evolution, the patient presented inspiratory stridor when sleeping and dyspnea. Laryngoscopy was performed, which showed whitish material occluding the larynx with involvement of the cricoarytenoid joint. On histopathology, it was interpreted as synovial pannus and the patient required tracheostomy. Due to bilateral coxarthrosis, with severe symptoms, bilateral total hip arthroplasty was also performed (Figure 1).

Table 1. Bone densitometry.

Bone densitometry	Bone mass g/cm²	Standard deviation *Z-score*	Reference values
Lumbar spine	0.561	-2.9	*Z-score* up to -2.0
Total body	0.890	-1.1	*Z-score* up to -2.0

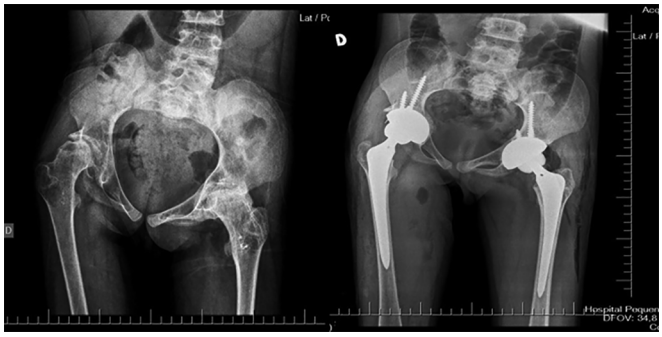

Figure 1. Radiograph of the pelvis and hip joints, before and after bilateral total hip replacement. In the first image we see: bone texture reduction; bilateral hip joint space reduction; pelvis weigher; deformities of the femoral heads with irregular contours.

Densitometria óssea (31/03/2015) indicando baixa massa óssea em coluna lombar e massa óssea normal em corpo total.

DISCUSSION

JIA is a disease with a variable clinical spectrum, with onset before the age of 16 years and the presence of arthritis (synovial inflammation with thickening of the lining and accumulation of synovial fluid)[2]. Both evolution and treatment can lead to complications. Osteoporosis is characterized by loss of bone mass and deterioration of its microarchitecture, predisposing and increasing the risk of fractures[4].

In pediatrics, secondary causes of osteoporosis are more frequent, especially osteoporosis caused by the use of glucocorticoids, in addition to systemic inflammatory diseases such as JIA, endocrine disorders and neoplastic diseases[6,10]. In the present case, the patient had systemic JIA with 9 years of evolution, severe involvement of multiple joints and osteoporosis secondary to the activity and inadequate disease treatment. She began treatment for osteoporosis with oral calcium, vitamin D and alendronate, which, after one year of use, was replaced by intermittent intravenous use of pamidronate. Bisphosphonates such as alendronate and pamidronate are synthetic analogues of pyrophosphate, a natural inhibitor of bone resorption. They are known to increase bone strength and decrease the activity and duration of osteoclasts, ensuring a quantitative tissue improvement[10,11].

In the first two decades of life, the assessment of bone mass is impaired by the physiological changes that occur in the bone structure of this age group. Dual X-ray absorptiometry (DXA) is influenced by bone size - and younger children appear to have low bone mineral density[12]. The estimation of total body bone mineral content (BMC), also measured by densitometry, is more sensitive to longitudinally assess the acquisition of bone tissue by this group of patients[13]. Another difficulty is the comparison of the values obtained with the average of young adults (T score), which results in a diagnosis of low bone mass. Thus, according to the International Society for Children Densitometry[14]. Osteoporosis is defined by the occurrence of one or more vertebral compression fractures in the absence of local disease or high-energy trauma or in the presence of low bone mineral density for the age and a significant history of fracture. Also remembering that the diagnosis of osteoporosis in children and adolescents should not be based exclusively on bone densitometry[14].

Autoimmune diseases can affect different parts of the upper airways, due to their structural complexity[1]. The cricoarytenoid joint is multiaxial, enabling movement of the arytenoid and cricoid cartilages during phonation and breathing[15]. In adults with rheumatoid arthritis, for example, the cricoarytenoid cartilage may be clinically compromised in 17-54% of cases, but the manifestations are milder, and respiratory failure is uncommon[15]. In the pediatric age group, on the other hand, cricoarytenoiditis is a rare and potentially life-threatening condition. This condition has already been described as an isolated manifestation of JIA exacerbation, and it is more common in patients with systemic JIA, as in the case presented, although there are few reports in patients with oligoarticular JIA[1].

Cricoarytenoiditis symptoms are a sensation of pressure in the throat that worsens with swallowing, hoarseness, odynophagia, pain when speaking and coughing, pain radiating to the ears, dyspnea and stridor[9,15]. These symptoms can lead to the misdiagnosis of croup, a common disease in the pediatric age group that progresses with stridor and respiratory failure. Both conditions respond well to corticosteroid drug therapy, which can perpetuate misdiagnosis. In more severe cases, early tracheostomy or intubation may be necessary[9]. The definitive diagnosis is made by laryngoscopy, which, in adults, reveals arytenoid edema and hyperemia, swollen vocal cords with variable mobility, immobility and laxity of the arytenoid cartilage on palpation. In the chronic phase, laryngoscopic findings include mucosal thickening around the arytenoid, immobile arytenoid cartilage, and narrowing of the cleft between the vocal cords[15].

The case presented reveals two complications of JIA, with different severity and prevalence, but which leads to limitations and decrease in quality of life, and which must be promptly recognized and correctly managed for the benefit of the patient.

REFERENCES

1. Abdel-Aziz M, Azab NA, Bassyouni IH, Hamdy G. Laryngeal involvement in juvenile idiopathic arthritis patients. Clin Rheumatol. 2011 Sep;30(9):1251-6.
2. Kindgren E, Fredirikson M, Ludvigsson J. Early feeding and risk of Juvenile idiopathic arthritis: a case control study in a prospective birth cohort. Pediatr Rheumatol Online J. 2017 May 26;15(1):46.
3. Barut K, Adrovic A, Sahin S, Kasapçopur O. Juvenile Idiopathic Arthritis. Balkan Med J. 2017 Mar; 34(2): 90–101.
4. Mantravadi M, DiMeglio L, Woerner S. Pediatric osteoporosis. Medscape, May 2016.
5. Hartman C, Hochberg Z, Shamir R. Osteoporosis in pediatrics. IMAJ 2003; 5: 509-515.
6. Hansen K, Kleker B, Safdar N, Bartels C. A systematic review and meta-analysis of glucocorticoid-induced osteoporosis in children. Seminars in arthristis and rheumatism, 2014, vol 44.
7. Rodd C et al. Incident Vertebral Fractures among Children with Rheumatic Disorders 12 Months Post-Glucocorticoid Initiation: A National Observational Study. Arthritis care & research 64.1 (2012): 122–131.
8. Costa H, Ribeiro M, Marques S, Castro H, Palhau L. Osteoporose pediátrica: revisão de aspectos diagnósticos e terapêuticos. Rev. SPMFR. Vol 18, n 2. 2009.
9. Masilamani K, Gandhi A. Cricoarytenoid arthritis presenting as croup. J R Soc Med. 2009 Nov 1; 102(11): 491–492.
10. Uziel Y, Eyal Z, Hashkes P. Osteoporosis in Children: Pediatric and Pediatric Rheumatology Perspective: a review. Pediatr Rheumatol Online J. 2009; 7: 16.
11. Pereira, RM et al. Diretrizes para prevenção e tratamento da osteoporose induzida por glicocorticoide. Rev. Bras. Reumatol. Vol 52. N 4. São Paulo, 2012.
12. Harrington J, Holmyard D, Silverman E, Sochett E, Grynpas M. Bone histomorphometric changes in children with rheumatic disorders on chronic glucocorticoids. Pediatr Rheumatol Online J, 2016.
13. Roth J, Bechtold S, Borte G, Dressler F, Girschick HJ, Borte M. Osteoporosis in juvenile idiopathic arthritis- a practical approach to diagnosis and therapy. Eur J Pediatr. 2007 Aug;166(8):775-84.

14.International Society for Clinical Densitometry. Official Positions of the International Society for Clinical Densitometry: Skeletal Health Assessment in Children From Infancy to Adolescence. 2019 ISCD Official Positions - Pediatric. Available at https://www.iscd.org/official-positions/2019-iscd--official-positions-pediatric/. 2019 May 28.

15.Futran ND, Sherris D, Norante JD. Cricoarytenoid arthritis in children. Otolaryngology - Head and Neck Surgery, 1991, 104(3): 366-370.