Residência RP Pediátrica
Publicação Oficial da Sociedade Brasileira de Pediatria

Submitted on: 04/13/2020
Approved on: 07/13/2020

ORIGINAL ARTICLE

Frequency of uveitis in pediatric patients with juvenile idiopathic arthritis in a tertiary hospital

Vivian London[1], Adriana Rodrigues Fonseca[2], Rozana Gasparello de Almeida[2], Marta Cristine Félix Rodrigues[2],Sheila Knupp Feitosa de-Oliveira[2], Monick Goecking[3], Flavio Sztajnbok[2], Julia Dutra Rossetto[3]

Keywords:
Arthritis,
Juvenile,
Uveitis,
Rheumatology,
Ophthalmology,
Eye Manifestations.

Abstract

Objective: observe the profile and the frequency of juvenile idiopathic arthritis-associated uveitis (JIA-U) in patients followed at a tertiary pediatric hospital. **Methods:** Retrospective study of patients with JIA attended from January to July 2019 at the Pediatric Rheumatology Department. **Results:** 41 charts were reviewed, from which four (9,75%) presented uveitis, all of them being diagnosed with JIA before seven years old and all of them with ocular complications. Concerning the subtype of JIA, two patients had persistent oligoarticular subtype and two had the negative rheumatoid factor poliarticular subtype. Three patients (75%) with JIA-U were antinuclear-antibody (ANA) positive. All patients presented uveitis within the first 4 years of JIA. **Conclusion:** Around 10% of the patients with JIA presented uveitis. In the JIA-U group, the following were observed: ANA positivity, JIA diagnosis before 7 years old and development of uveitis within the first 4 years of articular disease. The presence of ocular complications in all of the patients with JIA-U reveals the severity and the importance of tracking back this ocular manifestation.

[1] Federal University of Rio de Janeiro, Graduation in Medicine - Rio de Janeiro - RJ - Brazil.
[2] Institute of Childcare and Pediatrics Martagão Gesteira/UFRJ, Department of Rheumatology - Rio de Janeiro - RJ - Brazil.
[3] Institute of Childcare and Pediatrics Martagão Gesteira/UFRJ., Department of Ophthalmology - Rio de Janeiro - RJ - Brazil.

Correspondence to:
Vivian London.
Federal University of Rio de Janeiro. Av. Carlos Chagas Filho, 373, Rio de Janeiro - RJ, Brazil. CEP: 21941-590. E-mail: vivianlond@gmail.com

DOI: 10.25060/residpediatr-2022.v12n2-296

This work is licensed under a Creative Commons Attribution 4.0 International License.

INTRODUCTION

Juvenile idiopathic arthritis (JIA) represents a heterogeneous group of disorders, which have in common the clinical manifestation of chronic arthritis - lasting more than 6 weeks, of unknown origin and starting before 16 years of age. It is the most common chronic rheumatologic disease in childhood, and one of the most common chronic diseases in the pediatric population.[1] The most common extra-articular manifestation in JIA is uveitis, which is an intraocular inflammation. The combined prevalence of JIA-related uveitis (JIA-U) is estimated at 11.8% (95% CI: 11.2 to 12.4%) of patients.[2] JIA-U is characterized by being anterior and bilateral, persistent or chronic. It is usually asymptomatic and has no overt signs of inflammation, except in the enthesitis-related arthritis subtype, in which uveitis is acute and symptomatic. Upon initial presentation, 30-50% of JIA-U patients already demonstrate ocular complications. The rate of complications increases with disease duration, having been reported in up to 84% of patients with follow-up time between 6-10 years.[3,4] Among the most common complications are band keratopathy, cataract, posterior synechiae, glaucoma and cystoid macular edema - with the possibility of severe vision loss in up to 38% of these children.[5]

The literature reports the following risk factors associated with the onset of JIA-U: oligoarthritis, polyarthritis (with negative rheumatoid factor), psoriatic arthritis, positive antinuclear factor (ANA), female sex, children under 7 years of age at the onset of the first symptoms of JIA and JIA duration less than or equal to 4 years.[5,6]

Early detection - through ophthalmic screening with adequate intervals and appropriate treatment - can improve the child's visual prognosis and prevent ocular complications.[5] For the treatment of JIA-U, topical corticosteroids are used as a first line. However, chronic therapy with this drug class is associated with unwanted adverse effects, including increased intraocular pressure and cataracts. Methotrexate (MTX) is an immunomodulatory drug that is used as a second line. Another class of drugs that has been gaining prominence in treatment is biological drugs, in particular anti-TNFalpha.[3]

This investigation aimed to study and characterize uveitis in JIA patients treated at our institution, and to review the literature regarding the most current recommendations on screening, monitoring and treatment of U-JIA.

METHODS

We ran a retrospective study of data obtained from medical records of a tertiary pediatric hospital. We assessed the medical records of 44 children seen consecutively from January to July 2019 with suspected JIA diagnosis and who had an ophthalmological evaluation properly recorded in the medical record during the course of the disease. Patients who presented with idiopathic uveitis without diagnostic confirmation of JIA, those who had a confirmed diagnosis of another rheumatologic disease and those whose data could not be located in the medical records were excluded.

Child identification data (age and sex), JIA characterization (classification, presence of rheumatoid factor, antinuclear factor and HLA-B27 markers, age at disease diagnosis, treatment, disease activity) and data regarding the onset of the disease were collected. uveitis (age at first diagnosis of uveitis, type, location, laterality, recurrence, treatment and associated ocular complications).

We plotted the data in a Microsoft Excel 2010® spreadsheet, consisting of the number assigned to the patient and thus preserving their identity. We ran a descriptive analysis of the frequencies of the variables studied.

The study was approved by the Research Ethics Committee of the institution (CAAE: 09521419.5.0000.5264) and the Free and Informed Consent Form was waived as it was a retrospective study of data collection from medical records, without identifying the patients.

RESULTS

We reviewed the medical records of 44 children with JIA followed up at the rheumatology service. Three patients were excluded from the study because they had idiopathic uveitis without clinical or laboratory confirmation of JIA.

Table 1 shows data on patients' age at diagnosis of JIA, current age at the time of the study and follow-up time, in addition to the distribution of clinical forms of JIA:

Regarding gender, there was a distribution: 27 female patients (65.8%), 14 male (34.1%).

Of this sample of JIA patients studied, 9.75% (n=4) had some episode of uveitis during follow-up. The characteristics of each of them are explained in the table below (Table 2).

Of the 4 JIA-U patients, 2 (50%) had the oligoarticular form of JIA and 2 (50%) had the polyarticular form of rheumatoid factor negative; the antinuclear factor was positive in 3 patients (75%).

The diagnosis of JIA was established before the age of 7 years in all patients and all had the diagnosis of ocular manifestation within the first 4 years of evolution of the joint disease. Regarding the characterization of uveitis, there were: 3 (75%) with bilateral chronic anterior uveitis and 1 (25%) with sequelae of unilateral uveitis upon slit lamp examination. All the patients had eye complications from JIA-U, with the following distribution: band keratopathy (n=2; 50%), posterior synechiae (n=2; 50%), cataract (n=1; 25%), presence of pigment in the lens (n=1; 25%).

DISCUSSION

Based on the data obtained from this sample of JIA patients (n=41) regularly monitored at the rheumatology outpatient clinic, 4 (9.75%) children had uveitis as an extra-articular manifestation in the course of the disease. The prevalence of JIA-U found in this population was close to the prevalence

Table 1. Data on age upon diagnosis; current age; mean follow-up time and JIA types among the 41 patients with and without uveitis.

	Without uveitis		With uveitis	
	Mean(years)	Standard deviation	Mean(years)	Standard deviation
Mean age upon JIA diagnosis	5.22	3.63	3.75	1.48
Mean current age in the study	10.14	4.26	14.5	4.03
Mean follow-up time of patients	4.92	3.87	10.75	3.49
JIA type	**Without Uveitis**		**With uveitis**	
	N	%	N	%
Systemic	14	34.1	0	0.00
Negative rheumatoid factor polyarticular	12	29.2	2	4.8
Oligoarticular	8	19.5	2	4.8
Psoriatic arthritis	2	4.8	0	0.00
Positive polyarticular rheumatoid factor	1	2.4	0	0.00

Table 2. Characteristics of each patient with JIA-U in the studied sample.

Patient	sex	Age upon JIA diagnosis (years)	Time until 1st uveitis episode (years)	JIA type	ANF	Introduction of biologic agent for treatment	Type of uveitis	Ocular complications
1	M	6	4	Oligoarticular	+	Yes	Chronic bilateral anterior uveitis	Pigment in the anterior chamber
2	F	2	4	RF polyarticular	+	Yes	Chronic bilateral anterior uveitis	Strip keratopathy
3	F	3	1	Oligoarticular	+	No	Signs of prior unilateral uveitis	Posterior synechiae
4	F	4	1	RF polyarticular	-	No	Chronic bilateral anterior uveitis	Cataract, strip keratopathy, posterior synechiae

Legend: JIA-U juvenile idiopathic arthritis-related uveitis; ANF: antinuclear factor; M: male; F: Female: RF: rheumatoid factor.

estimated in the literature.[7] JIA-U has the characteristic of appearing in the first years of joint disease and, as it is asymptomatic and causes eye complications, it can, unfortunately, be diagnosed only when there is already established visual loss. In patients with severe uveitis, 50 to 75% of children will develop visual impairment secondary to complications.[4]

According to the criteria established by Jabs D. et al for the standardization of uveitis nomenclature, the ocular inflammation associated with JIA is usually characterized by being anterior, non-granulomatous, bilateral and persistent, which consists of an inflammation lasting more than 3 months.[8] Its course can be recurrent - with periods of remission, without treatment, greater than or equal to 3 months - or chronic - with periods of remission, without treatment, less than 3 months. Even with early diagnosis and adequate follow-up of treatment, many patients will not have remission of uveitis, which can persist into adulthood.[9]

It is interesting to note that one of the excluded patients had uveitis and systemic arthritis with an immunological panel, which confirmed the diagnosis of Blau syndrome. Also called juvenile autosomal granulomatosis, it is an autosomal dominant condition characterized by granulomatous inflammation of the skin, eyes, and joints. Patients present with an erythematous papular rash, which may be transient. Arthritis develops in the first decade of life, usually involving wrists, ankles, knees, and/or elbows with progressive flexion contractures of the fingers (camptodactyly). Biopsy usually reveals synovial granulomas. Granulomatous uveitis can occur in the natural course of the disease. Atypical manifestations include fever, cranial neuropathies, arteritis, and granulomatous involvement of visceral organs.[10]

In the population studied, 3 patients (75%) were diagnosed with the classic uveitis in the course of JIA - bilateral chronic anterior uveitis, and 1 patient (25%) was diagnosed after the acute course of uveitis, presenting signs on of unilateral prior uveitis. Regarding the types of JIA, it is described in the literature that U-JIA can be observed more frequently in patients with oligoarthritis with an extended course (cumulative incidence of 25-30%), followed by the oligoarticular type with a persistent course (16-18%), rheumatoid factor-negative polyarthritis (4-14%) and psoriatic arthritis (10-12%). Uveitis can also occur in systemic JIA, but it is rare.[9] In the present study, the oligoarticular form was not the majority in those who had uveitis (n=2; 50%).

The results obtained were not compatible with the data found in the literature, since uveitis in patients with the oligoarticular form had a prevalence equal to that of those with the polyarticular form with negative rheumatoid factor (50%). This data is probably due to the small number of cases evaluated in this study. In our study, we found a relationship

between the positivity of the antinuclear factor (ANA) and the appearance of U-JIA (n=3; 75%). There was still an important relationship between the diagnosis of JIA before 7 years of age (n=4; 100%) and the onset of uveitis. All the patients manifested and were diagnosed with JIA-U within the first 4 years of joint disease. Arthritis typically precedes uveitis, but in 3-7% of cases, the ophthalmologic condition may precede the joint involvement.

JIA-U has an oligosymptomatic presentation and may go unnoticed by family members. When symptomatic, blurred vision is the main complaint, and eye pain is infrequent. However, it is worth mentioning that the perception of visual blurring usually only occurs in older children. The signs are discreet and generally imperceptible to ectoscopy; and evaluation by anterior biomicroscopy with a slit lamp is essential.

Ophthalmological evaluation of these children is mandatory and should be performed as soon as possible, preferably within 6 weeks of JIA diagnosis; it includes the monocular visual acuity test, the slit lamp biomicroscopy, the intraocular pressure measurement and the fundus examination. Inflammation in the anterior chamber of the eye, if present, is assessed by slit lamp examination and is characterized by the presence of inflammatory cells in this compartment. The quantification of these cells was recently established as the most sensitive measure to assess the response to treatment and the quality of life of patients. It is also correlated with the presence of ocular complications and increased risk of visual loss[7].

Slit-lamp biomicroscopy also allows the identification of ocular complications, such as band keratopathy (deposition of calcium on the cornea; Figure 1), cataracts (clouding of the lens) and posterior synechiae (adhesion of the iris to the lens), which will impair visual accommodation mainly at night and far away. The fundus of the eye is important for contributing to the differential diagnosis of other causes of uveitis and for allowing the visualization of cystoid macular edema. These mentioned complications of uveitis are the most common[11].



Figure 1. Band keratopathy.

In the present study, ocular complications were present in all children who had uveitis, and one patient had more than one complication. Band keratopathy was the most frequent sequelae (n=2; 50%) and also the presence of posterior synechiae (n=2; 50%), followed by cataract (n=1; 25%), and pigment in the lens (n=1; 25%).

Regarding the treatment of JIA-U, the main objective is the control of ocular inflammation with the prevention of recurrences and ocular complications.

Among the 4 patients studied, the need to introduce a systemic biological agent to control uveitis was observed in 3 (75%), indicating the severity of the cases and the refractoriness to the use of other medications. The most prescribed biological agent for disease control was Adalimumab (n=2; 50%), followed by Etanercept (n=1; 25%). One patient (25%) was not treated with any of the classes indicated for uveitis, because it was diagnosed when there were only sequelae from a previous acute inflammatory event.

According to the guidelines for screening, monitoring and treatment of JIA-associated uveitis defined by the American College of Rheumatology in 2019[5], the initial treatment for active U-JIA should be the ocular administration of topical corticosteroids, followed by gradual withdrawal as soon as the anterior chamber reaction is under control. The drug of choice is 1% prednisolone acetate in drops, due to better penetration into the anterior chamber. The combination of a cycloplegic drug is also indicated in order to minimize the damage to the synechiae that may occur during the inflammatory process.[12] In the latest guidelines on the treatment of U-JIA, the use of systemic corticosteroids is much less indicated than in the previous ones, due to the side effects resulting from its long-term use.[12] In principle, there is no need to change systemic therapy with the onset of uveitis, unless control of ocular inflammation is not achieved with continued local treatment for 3 months. In these cases, the introduction or intensification of systemic therapy is recommended, with gradual reduction of topical corticosteroids.[5] In patients with severe active chronic U-JIA and with vision-threatening ocular complications, immediate initiation of MTX combined therapy with an anti-TNF biological agent. Among anti-TNF drugs, the use of adalimumab or infliximab is preferred over etanercept. In those patients who are refractory to this treatment, it is recommended to use the maximum dose of the anti-TNF agent of choice before changing the immunosuppressant class. Upon achieving control of JIA-U, reduction of topical therapy is recommended before reduction of systemic therapy. This decrease in systemic treatment should be performed after at least 2 years of control of uveitis activity, due to the chance of uveitis relapse with its early withdrawal.[5] Below is the flowchart referring to the treatment of JIA-U (figura 2):

Periodic ophthalmic screening is the main tool in the secondary prophylaxis of JIA-U. It should preferably be performed within 6 weeks of JIA diagnosis. The frequency of the ophthalmic evaluation is determined according to the risk for

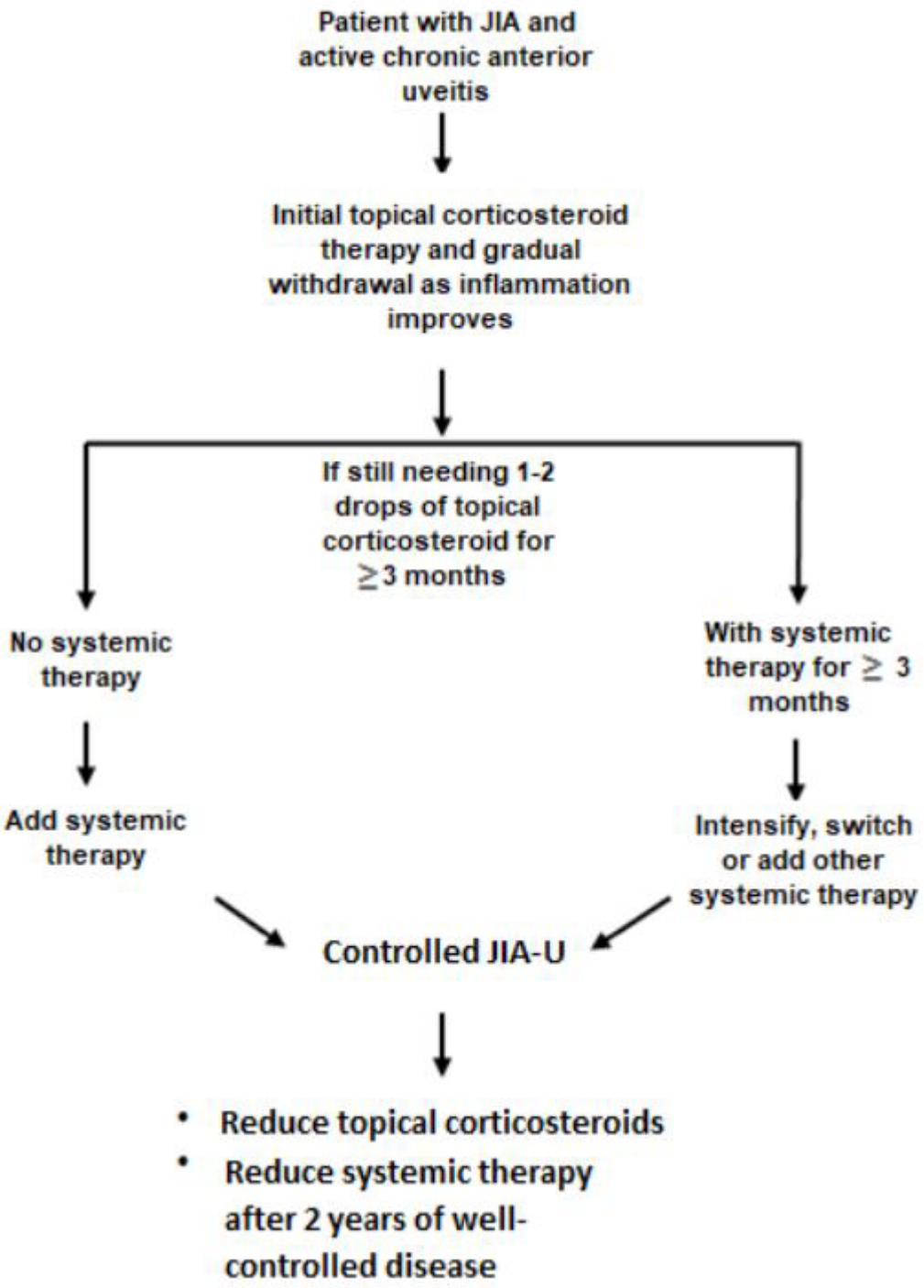

Figure 2. Flowchart: treatment of U-JIA.

uveitis development.[5] The recommendations are set out in the flowchart below (figura 3):

It is important to emphasize that the periodic evaluation must be carried out even if the joint condition is in remission.

We emphasize the importance of care in the ophthalmological follow-up of these patients, in order to establish an early diagnosis of uveitis and prevent possible ocular complications. The pediatrician and/or pediatric rheumatologist who manages a patient with JIA should be aware of this aspect of

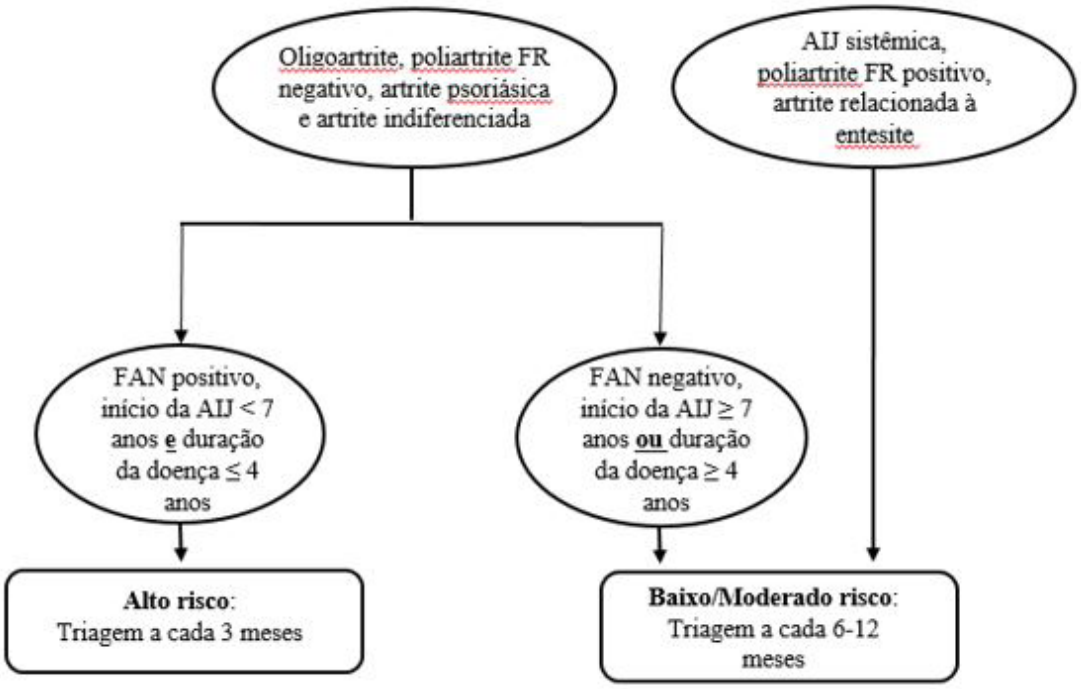

Figure 3. Flowchart: recommendations.

care and know how to correctly indicate the referral to the ophthalmologist.

CONCLUSION

This study had important limitations, such as being a retrospective study of medical records review, with a short coverage period and a small number of patients. Such limitations must be considered when evaluating the results. In the population studied, it is concluded that the appearance of JIA-U was significant, highlighting the need to introduce a biological agent for its treatment and the high prevalence of ocular complications. Adalimumab was identified as the main biological agent used in the treatment, indicated according to the severity and refractoriness of the condition to other treatments. Once the importance of uveitis as the main extra-articular manifestation of JIA has been defined and its association with severe visual sequelae, even with the establishment of adequate treatment, it is then necessary to establish protocols that guide its monitoring, in order to reduce the chances of eye damage to these children.

We conclude that screening for JIA-U is of vital importance, with periodic ophthalmological evaluation in both high and low-risk JIA patients, it is essential for its early diagnosis and treatment, with the aim of promoting rapid and lasting remission. inflammation and avoid its complications.

REFERENCES

1. Prakken B, Albani S, Martini A. Juvenile idiopathic arthritis. Lancet. 2011;377(9783):2138-49.
2. Jari M, Shiari R, Salehpour O, Rahmani K. Epidemiological and advanced therapeutic approaches to treatment of uveitis in pediatric rheumatic diseases: a systematic review and meta-analysis. Orphanet J Rare Dis 15, 41 (2020)
3. Morelle G, Gueudry J, Uettwiller F, Wouters C, Bader-Meunier B, Robert MP, et al. Chronic and recurrent non-infectious paediatric-onset uveitis: a French cohort. RMD Open 2019;5:e000933. doi:10.1136/rmdopen-2019-000933
4. Ramanan AV, Dick AD, Benton D, Compeyrot-Lacassagne S, Dawoud D, Hardwick B, et al. A randomised controlled trial of the clinical effectiveness, safety and cost-effectiveness of adalimumab in combination with methotrexate for the treatment of juvenile idiopathic arthritis associated uveitis (SYCAMORE Trial). Trials. 2014;15:14.
5. Angeles-Han ST, Ringold S, Beukelman T, Lovell D, Cuello CA, Becker ML, et al. 2019 American College of Rheumatology/Arthritis Foundation Guideline for the Screening, Monitoring, and Treatment of Juvenile Idiopathic Arthritis-Associated Uveitis. Arthritis Rheumatol. 2019;71(6):864-77.
6. Moradi A, Amin RM, Thorne JE. The Role of Gender in Juvenile Idiopathic Arthritis-Associated Uveitis. Journal of Ophthalmology, 2014, 1-7. doi:10.1155/2014/461078
7. Foeldvari I, Klotsche J, Simonini G, Edelsten C, Angeles-Han ST, Bangsgaard R, et al. Proposal for a definition for response to treatment, inactive disease and damage for JIA associated uveitis based on the validation of a uveitis related JIA outcome measures from the Multinational Interdisciplinary Working Group for Uveitis in Childhood (MIWGUC). Pediatr Rheumatol Online J. 2019;17(1):66.

8. Jabs DA, Nussenblatt RB, Rosenbaum JT, Standardization of Uveitis Nomenclature Working G. Standardization of uveitis nomenclature for reporting clinical data. Results of the First International Workshop. Am J Ophthalmol. 2005;140(3):509-16.

9. Heiligenhaus A, Heinz C, Edelsten C, Kotaniemi K, Minden K. Review for disease of the year: epidemiology of juvenile idiopathic arthritis and its associated uveitis: the probable risk factors. Ocul Immunol Inflamm. 2013;21(3):180-91.

10. Blau EB. Familial granulomatous arthritis, iritis and rash. J Pediatr. 1985;107(5):689

11. Thorne JE, Woreta F, Kedhar SR, Dunn JP, Jabs DA. Juvenile idiopathic arthritis-associated uveitis: incidence of ocular complications and visual acuity loss. Am J Ophthalmol. 2007;143(5):840-6

12. Sen ES, Ramanan AV, Juvenile idiopathic arthritis-associated uveitis,Best Practice&Research Clinical Rheumatology 2018; https://doi.org/10.1016/j.berh.2018.01.

13. Henderson LA, Zurakowski D, Angeles-Han ST, Lasky A, Rabinovich CE, Lo MS. Medication use in juvenile uveitis patients enrolled in the Childhood Arthritis and Rheumatology Research Alliance Registry. Pediatric Rheumatology, 2016; 14,9. doi:10.1186/s12969-016-0069-5