Residência RP Pediátrica
Publicação Oficial da Sociedade Brasileira de Pediatria
ISSN-Online: 2236-6814

Submitted on: 10/09/2020
Approved on: 11/12/2020

CASE REPORT

Brain-lung-thyroid syndrome: clinical response under methylphenidate hydrochloride therapy

Barbara Bianchi[1,2], Camila Diniz Gil[1,2], Laura Vagnini[1], Jacqueline Harouche Rodrigues Fonseca[3], Zumira Aparecida Carneiro[2], Regina Albuquerque[4], Ana Hamad[5], Charles Marques Lourenco[1,2,4].

Keywords:
Thyroid Nuclear Factor 1, hypotonia, sequencing, Chorea.

Abstract

Introduction: The "brain-lung-thyroid syndrome" is caused by mutations in the NKX2-1 gene, which encodes the thyroid transcription factor 1, and is characterized by widely diverse clinical manifestations: choreic movements, respiratory disorders and hypothyroidism. **Case Report**: Male patient, 10 years old, son of non-consanguineous parents, being treated for subclinical hypothyroidism with levothyroxine, was referred at 4 years of age for investigation of hypotonia. There were no reports of breathing problems at birth. Investigation for hypotonia (central and neuromuscular) including muscle biopsy was normal. There was a progressive improvement in hypotonia, but the patient developed choreic movements. In view of the new clinical finding, a genetic-molecular study was carried out directed towards the NKX2-1 gene, confirming the diagnosis of "brain-lung-thyroid syndrome". The patient started treatment with methylphenidate hydrochloride with evident improvement in choreic movements. **Discussion**: Manifestations related to the NKX2-1 gene may include hereditary benign chorea (HBC), congenital hypothyroidism and neonatal respiratory disorders. Generally, chorea begins in early childhood, in the patient's first year of life (most common), in later childhood or even adolescence, and progresses into the second decade after which it remains static or (rarely) resolves. Recently, the use of methylphenidate in patients with a mutation in this gene proved to be a possible therapeutic approach to control choreic movements and improve motor coordination in patients affected by this rare disease.

[1] Paulista Center of Diagnosis and Research, Clinical Genetics - Ribeirão Preto - SP - Brazil
[2] Estácio de Ribeirão Preto University Center, School of Medicine - Ribeirão Preto - São Paulo - Brazil.
[3] DLE Laboratory, Biochemical Genetics - Rio de Janeiro - SP - Brazil.
[4] São José do Rio Preto State Medical School (FAMERP), Neurogenetics - São José do Rio Preto - São Paulo - Brazil.
[5] Ribeirão Preto University Hospital- Ribeirão Preto Medical School (FMRP) – University of São Paulo, Department of Neurosciences and Behavioral Sciences - Ribeirão Preto - SP - Brazil.

Correspondence to:
Charles Marques Lourenco.
Centro Paulista de Diagnostico e Pesquisa. R. Cap. Adélmio Norberto da Silva, 590 - Alto da Boa Vista, Ribeirão Preto - SP, Brazil. CEP: 14025-670.
E-mail: charlesgenetica@gmail.com

Residência Pediátrica; 2023: Ahead of Print.
DOI: 10.25060/residpediatr-2023.v13n1-483

This work is licensed under a Creative Commons Attribution 4.0 International License.

INTRODUCTION

Hereditary Benign Chorea (HBC; OMIM 118700), present in the brain-lung-thyroid syndrome (BTLS; OMIM 610978), is a rare autosomal dominant non-progressive condition that occurs in early childhood, associated with mutations of the NKX2-1 gene present in the chromosome 14q13[1]. It is a fundamental gene in the embryogenesis and physiology of the organs affected by the syndrome[2].

Mutations in this gene can involve three main organs: brain, thyroid and lungs (see figure 1). The neurological manifestations of the disease include chorea, dystonia, myoclonus, tics, hypotonia, ataxia, dysarthria and delayed motor development[3]. In addition, changes in the thyroid gland can range from congenital hypothyroidism (clinical or subclinical) to thyroid agenesis. Among the main pulmonary manifestations, the following stand out: recurrent infections, asthma, lung cancer, pulmonary alveolar proteinosis and pulmonary lobe agenesis. Furthermore, other organs may be involved, such as the pituitary gland[4].

Some patients with BTLS have psychiatric disorders such as attention deficit hyperactivity disorder (ADHD), causing learning difficulties and obsessive-compulsive disorder (OCD)[1]. ADHD is a neurobiological problem that can affect all ages, but it is more frequent in children. Clinical signs are distraction, difficulty concentrating, hyperactivity, impulsivity and can lead to negative consequences such as learning disorders. There are several drugs used to treat ADHD, with methylphenidate hydrochloride being usually indicated as the drug of choice[5]. This drug has a similar structure to amphetamines, that is, it is a central nervous system (CNS) psychostimulant. The drug improves cognitive tasks and reduces fatigue[6].

Interestingly, a recent case report of a patient with BTLS showed a significant improvement in the patient's choreic movements with the use of methylphenidate hydrochloride[3]. However, this improvement was previously associated with two patients with hereditary benign chorea[8,9]. In 1996, Friederich was the first to describe improvements in handwriting and gait in a young male patient treated with methylphenidate hydrochloride[8]. The author's hypothesis was that this benefit would be due to a decrease in chorea stress and not by a direct effect of the drug.

We report here a case of a male patient with a mutation in the NKX2-1 gene who showed improvement in choreic movements after using methylphenidate hydrochloride, emphasizing the patient's diagnostic journey to confirm the etiology of his clinical condition.

CASE REPORT

Male patient, 10 years old, son of young non-consanguineous parents, was referred for evaluation of hypotonia associated with movement disorder. There were no complications during pregnancy, he was born by cesarean delivery, at term (39 weeks and 3 days), from mother G2P1C1A1, weighing 2.850 kg and length of 47 cm. He had no clinical complications at birth, with no signs of cyanosis and jaundice. He was discharged from the hospital 2 days after birth. Neonatal screening tests showed no change.

Developmental milestones showed that the patient presented a delay in supporting the neck and trunk, sitting only at 9 months with support. In addition, the patient's speech was late, as well as walking without support, which only happened at 3 years of age, after follow-up with the physical

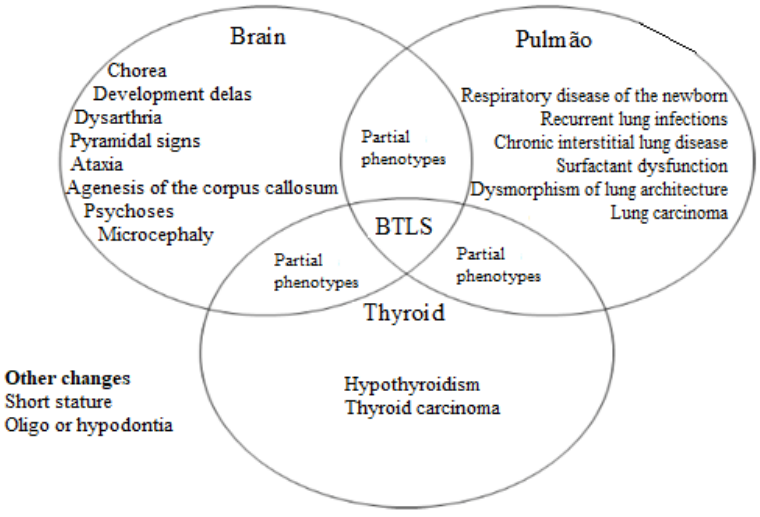

Figure 1. Spectrum of NKX2-1 gene phenotypes and its disorders. Disorders related to the NKX2-1 gene can manifest abnormalities in the brain, thyroid or lung, and may affect one or more. The Brain-Lung-Thyroid Syndrome refers to the involvement of the three organs[7]. Source: The Authors (2020).

therapist. Due to speech delay, the patient started speech therapy, starting to speak only at 3 years old the first words and at 5 years old he was able to formulate sentences.

At 11 months of life, due to the neurological condition, the patient was evaluated by an endocrinologist and the ordered tests confirmed the existence of subclinical hypothyroidism. The patient started thyroid hormone replacement, levothyroxine at an initial dose of 50 mg, and currently at 75 mg; however, there was no significant improvement in the motor part. The patient was referred to the reference service to investigate the condition of hypotonia, where a systematic investigation was carried out with muscle biopsy, electroneuromyography and magnetic resonance imaging of the brain, which did not show any abnormality.

From the age of 8, the patient began to present movement disorders with involuntary choreic movements and was again evaluated by the genetics team of the clinic where the hypothesis of benign childhood chorea was made. The patient was asked for an exomic sequencing test, which showed the presence of the c.177_178insG mutation (p.His60Gln ext36*) in the NKX2-1 gene, confirming the diagnosis of Brain-Lung--Thyroid Syndrome/Benign Childhood Chorea.

After this diagnosis, treatment with haloperidol was started for the movement disorder; however, the patient developed acute depression, personality changes and even with the reduction in the dose, the patient maintained behavioral changes, leading to the suspension of the drug. The mother did not accept the introduction of new drugs for a period of 1 year. In a new reassessment, at the age of 10, it was suggested to start treatment with methylphenidate hydrochloride, because the patient also had difficulty concentrating. The initial dose of the new drug was 20mg/day and since the beginning the patient showed improvement in movement disorders and also in concentration.

Upon physical examination, the patient presented a symmetrical face with some choreic facial movements, eye movements within normal limits, centered tongue, symmetrically and globally preserved muscle strength. Live osteotendinous reflexes in upper and lower limbs and plantar cutaneous reflex in flexion. Superficial and deep sensitivity were preserved. In addition, continuous choreic movements were observed in the limbs and trunk, and the gait was characterized by a slightly widened base.

DISCUSSION

The brain-lung-thyroid syndrome results from a mutation in the NKX2-1 gene, which is essential for embryogenesis, generating a physiological impairment in the functionality of these organs. It begins with manifestations such as dystonia, movement disorders, hypothyroidism, hypotonia, respiratory diseases and recurrent pulmonary infections[3]. There is evidence that the pituitary gland is also affected, leading to pituitary hormone disorders such as hypogonadism[4].

The reported patient has choreic movements and subclinical hypothyroidism, but he does not have pulmonary manifestations, which may occur with a subgroup of patients affected by this disease. According to the literature, the classic triad (involvement of the three organs) is only observed in 50% of reported cases[4]. A recent study reported neurological and thyroid involvement in 30% of patients and, in 13 % of patients, the clinical presentation is isolated in the form of chorea[7].

Peall et al reported that 40% of patients with the gene mutation had pulmonary involvement, especially in the form of respiratory tract infection and infant respiratory distress syndrome[1], manifestations that were not observed or described by the patient's parents in their clinical history. Thyroid dysfunction was documented as extremely prevalent: of the 46 patients affected by the disease, 40 individuals had subclinical hypothyroidism[7]. Gras et al described that 67% of their sample of patients had congenital hypothyroidism, attributing the psychomotor delay to thyroid hormone deficiency[2].

Regarding his neuropsychomotor development, hypotonia was identified in the first year of life associated with delay in motor milestones with progressive evolution to choreic movements[2]. There are similarities in the evolutionary neurological clinic of the patient reported in this case report with the others described in the literature[2]. Monti et al[10] reported in their study that the patient already presented neurological development impairment in the first months of life: presence of choreic movements, motor incoordination in the lower limbs, axial hypotonia and developmental delay[10]. The onset of chorea usually occurs in one of the following periods[7]:

- Early childhood
- At approximately one year of age (most common)
- Late childhood or adolescence

Onset of chorea usually occurs in early childhood (mean age 2.5-3 years), although it is likely to occur even earlier due to late recognition of the phenotype of this movement disorder[1].

Diverging from the case of the patient reported in this case, since choreic movements started later (at 8 years of age). It is worth noting that choreic symptoms in patients with a mutation in the NKX2-1 gene are not progressive in nature, on the contrary, there is a tendency towards improvement in adulthood[9].

Most patients with mutations in the NKX2-1 gene, despite the neurological symptoms, have neuroimaging exams within normal limits, which was also observed in the reported patient. However, some patients presented alterations in neuroimaging exams, such as: ventricular dilatation, bilateral pallidum hyperintensity and cystic mass in the pituitary gland.

There are disagreements about the frequency of association between Attention Deficit Hyperactivity Disorder (ADHD) and brain-lung-thyroid syndrome, an association present in our patient. Peall et al[1] reported that of the 10 patients

reported in the study, none of them was diagnosed with ADHD. On the other hand, Gras et al[2] reported that 7 of the 28 patients had ADHD with responsiveness to pharmacological treatment with methylphenidate hydrochloride.

In our case report, the patient was not submitted to a formal neuropsychological evaluation; however, clinically the patient had been diagnosed with ADHD.

Methylphenidate hydrochloride is a medication generally used to treat ADHD, but it has also proved to be advantageous for the choreic movements that are present in this syndrome.

The responsiveness to methylphenidate hydrochloride in movement disorders may be related to the reduction in the availability of D2 receptors by competitively inhibiting dopamine transporters and, therefore, generating an increase in extracellular dopamine[11]. In proton emission tomography neuroimaging (PET--CT) CFT was used to measure presynaptic dopamine transporter function and Raclopride to measure postsynaptic D2 receptor function, resulting in reduced binding of Raclopride in the striatum. The reduction in motor hyperactivity can be explained by activation in pre-synaptic D2 and D3 autoreceptors, leading to a reduction in vesicular dopamine and reducing dopamine in postsynaptic D1 and D2 receptors. It also modulates the neural activity of several brain areas, increasing or decreasing the cortical and subcortical metabolism[11].

In the study by Kathryn et al[1], the PET-CT scan indicated a reduction in the function of dopamine receptors, in parallel to this, when using the drug in the treatment of ADHD, its mechanism of action was used to increase the functionality of neurotransmitters involved in the disorder, such as dopamine. Since the lack of this neurotransmitter leads to alterations in movement, such as chorea and dystonia, when methylphenidate is introduced, there is an improvement in the clinical condition of patients with BTLS.

The case report describes an immediate response to methylphenidate in a patient with brain-lung-thyroid syndrome. Future research should be carried out with the intention of documenting and corroborating these findings in order to establish an effective treatment for movement disorders in these patients, thus contributing to a substantial improvement in the quality of life of those affected by this rare disease.

REFERENCES

1. PEALL, Kathryn et al. Benign hereditary chorea related to NKX2.1: expansion of the genotypic and phenotypic spectrum. Developmental Medicine & Child Neurology, v. 56, n. 7, p. 642-648, jul. 2014. Disponível em: <https://www.ncbi.nlm.nih.gov/pubmed/24171694>
2. GRAS, Domitille et al. Benign hereditary chorea: phenotype, prognosis, therapeutic outcome and long term follow-up in a large series with new mutations in the TITF1/NKX2-1 gene. Journal of Neurology, Neurosurgery, and Psychiatry, v. 83, n. 10, p. 956-962, oct. 2012. Disponível em: <https://www.ncbi.nlm.nih.gov/pubmed/22832740>
3. GAUQUELIN, Laurence et al. The Movement Disorder of Brain-Lung--Thyroid Syndrome Can be Responsive to Methylphenidate. Tremor and Other Hyperkinetic Movements, v. 7, p. 508. Disponível em: <https://www.ncbi.nlm.nih.gov/pmc/articles/PMC5666014/>
4. BALICZA, Péter et al. NKX2-1 New Mutation Associated With Myoclonus, Dystonia, and Pituitary Involvement. Frontiers in Genetics, v. 22, n. 9, p. 335, aug. 2018. Disponível em: <https://www.ncbi.nlm.nih.gov/pubmed/30186310>
5. BARBOSA, Flavia et al. Uso de metilfenidato em crianças com transtorno de deficit de atenção e hiperatividade em um município do interior do Paraná, Brasil. ACTA Biomedicina Brasiliense, v. 7, n. 2, p. 29-38, dec. 2016. Disponível em: <http://www.actabiomedica.com.br/index.php/acta/article/view/147>
6. BARROS, Denise; ORTEGA, Francisco. Metilfenidato e aprimoramento cognitivo farmacológico: representações sociais de universitários. Saúde Soc. São Paulo, v. 20, n. 2, p. 350-362, 2011. Disponível em: <https://www.scielosp.org/pdf/sausoc/2011.v20n2/350-362/pt>
7. PATEL, Neepa J., JANKOVIC, Joseph. *NKX2-1*-Related Disorders. Gene Reviews [internet], feb. 2014. Disponível em: <https://www.ncbi.nlm.nih.gov/books/NBK185066/#nkx2-1-dis.References>
8. RICHARD, Friederich. Benign hereditary chorea improved on stimulant therapy. Pediatr Neurol, v. 14, p. 326-327, may. 1996. Disponível em: <https://doi.org/10.1016/0887-8994(96)00056-2>
9. DEVOS, David et al. New syndromic form of benign hereditary chorea is associated with a deletion of *TITF-1* and *PAX-9* contiguous genes. Movement Disorders, v. 21, p. 2237-2240, oct. 2006. Disponível em : https://onlinelibrary.wiley.com/doi/full/10.1002/mds.21135
10. MONTI, Sara et al. NKX2.1-Related Disorders: a novel mutation with mild clinical presentation. Italian Journal of Pediatrics, v. 41, n. 45, jun. 2015. Disponível em: <https://ijponline.biomedcentral.com/articles/10.1186/s13052-015-0150-6#Sec2>
11. TUBING, J et al. Methylphenidate can improve chorea in NKX2.1 and ADCY5 mutation-positive pacients- A report in two children. Moviment Disorders Clinical Practice, v. 5, n. 3, p. 343-345, 2018. Disponível em: < https://www.ncbi.nlm.nih.gov/pmc/articles/PMC6336415/>