Residência RP Pediátrica
Publicação Oficial da Sociedade Brasileira de Pediatria
ISSN-Online: 2236-6814

Submitted on: 11/22/2020
Approved on: 02/09/2021

CASE REPORT

Subcutaneous fat necrosis of the newborn: case report and literature review

Júlia Belcavelo Contin Silva[1], Bruno Augusto Alvares[2], João César Lyra[3], Alice Yamashita Prearo[3], Maria Regina Bentlin[3], Silvio Alencar Marques[4].

Keywords:
Fat necrosis,
Infant,
Newborn,
Diseases,
Hypothermia,
Induced,
Skin diseases.

Abstract

Introduction: incomplete. **Results:** Fatty necrosis of the subcutaneous tissue is an uncommon inflammation, with a still unknown pathogenesis, which appears in newborns in the first weeks of life. The lesions are characterized by areas of edema and erythema that progress to hardened and painless subcutaneous plaques or nodules. The risk factors for this panniculitis are hypoxia and perinatal stress, such as traumatic or prolonged delivery and, more recently, therapeutic hypothermia. The diagnosis is clinical, the evolution is self-limited and benign, but the level of serum calcium should be monitored, as hypercalcemia can occur, leading to severe symptoms. In our report, we describe a case of subcutaneous adipose necrosis associated with prolonged expulsive and therapeutic hypothermia. **Conclusion:** Although infrequent, early recognition of this condition, especially in newborns with risk factors, is important, and can guide clinical follow-up including monitoring calcium, pain control and not using antibiotics.

[1] Medical School of Botucatu UNESP, Pediatrics Resident - Botucatu - São Paulo - Brazil.
[2] Medical School of Botucatu UNESP, Dermatology Resident - Botucatu - São Paulo - Brazil.
[3] Medical School of Botucatu UNESP, Assoaciate Professor - Department of Pediatrics - Botucatu - São Paulo - Brazil.
[4] Medical School of Botucatu UNESP, Full Professor – Department of Dermatology - Botucatu - São Paulo - Brazil.

Correspondence to:
Júlia Belcavelo Contin Silva.
UNESP. Av. Prof. Mário Rubens Guimarães Montenegro, s/n - UNESP - Campus de Botucatu - Botucatu/SP, Brazil. CEP: 18618687.
E-mail: juliacontin@hotmail.com

Residência Pediátrica; 2023: Ahead of Print.
DOI: 10.25060/residpediatr-2023.v13n2-516

This work is licensed under a Creative Commons Attribution 4.0 International License.

INTRODUCTION

Subcutaneous fat necrosis is a rare, self-limiting panniculitis that appears in at term or post-term newborns (NB) in their first weeks of life[1]. It is characterized by areas of edema and erythema that progress to subcutaneous, erythematous, hardened and painless plaques or nodules[2]. It occurs more frequently in patients born after traumatic or prolonged labor, and more recently in those submitted to therapeutic hypothermia[3]. The diagnosis is clinical, the evolution is benign, but the serum calcium level must be monitored, as hypercalcemia is frequent and can lead to severe symptoms[4].

We describe a case of subcutaneous fat necrosis associated with prolonged expulsive period and therapeutic hypothermia.

CASE DESCRIPTION

Ours is a term newborn (NB), female, birth weight 3980g, vaginal delivery, with a nuchal cord, prolonged expulsive period and Apgar score of 0 – 4 – 4. Required neonatal resuscitation (tracheal intubation and cardiac massage), and after stabilization she was referred to the Neonatal Intensive Care Unit. Obtaining vascular access was difficult, requiring central venous dissection (right jugular) due to failure to pass the umbilical catheter and the percutaneous catheter. With 2 hours of life, she presented convulsive crises, which were difficult to control, requiring phenobarbital, phenytoin and continuous midazolam. Body therapeutic hypothermia was indicated and started at 4 hours of life, with core temperature maintained at around 33.5°C. Still in the first 24 hours of life, she developed cardiogenic shock (clinical and echocardiographic diagnosis) that responded to the administration of dobutamine, a shock attributed to perinatal asphyxia. The head ultrasound performed at 48 hours of life showed diffuse changes in the brain parenchyma, edema and image of left parasagittal ischemic infarction. She remained under hypothermia for 72 hours, with subsequent uneventful rewarming. A trophic enteral diet with breast milk was started after rewarming, with difficulty in progressing, requiring parenteral nutrition. At the end of the second week of life, the venous catheter was removed and she was extubated. On the 13th day of life, she presented with phlogistic signs and purulent secretion at the site of catheter insertion, associated with a hardened area in the right upper limb. Initially the diagnosis was an abscess and antibiotics were prescribed. In the blood culture there was growth of Enterobacter cloacae. After one week of treatment (19 days of life), despite the use of appropriate antibiotics for the agent, there was progression of the edema, of a hardened nature and erythema, to the back region. A soft tissue ultrasound was ordered, which showed skin and subcutaneous tissue with diffuse thickening in the dorsal region associated with blurring of subcutaneous fat. The hypothesis was subcutaneous fat necrosis. At 25 days, she still had hardened erythematous-hyperchromic plaques, difficult to outline, in the region of the right shoulder, left shoulder and left back (figure 1), but with negative blood cultures, without other clinical and laboratory signs of infection. The serum calcium dosage was normal until the third week of life, but after 1 month it increased, reaching levels between 10.9 and 11.7 mg/dl. During this period, a loop diuretic was used with normalization of serum calcium levels. A skin biopsy was performed, which confirmed the diagnosis of subcutaneous fat necrosis.

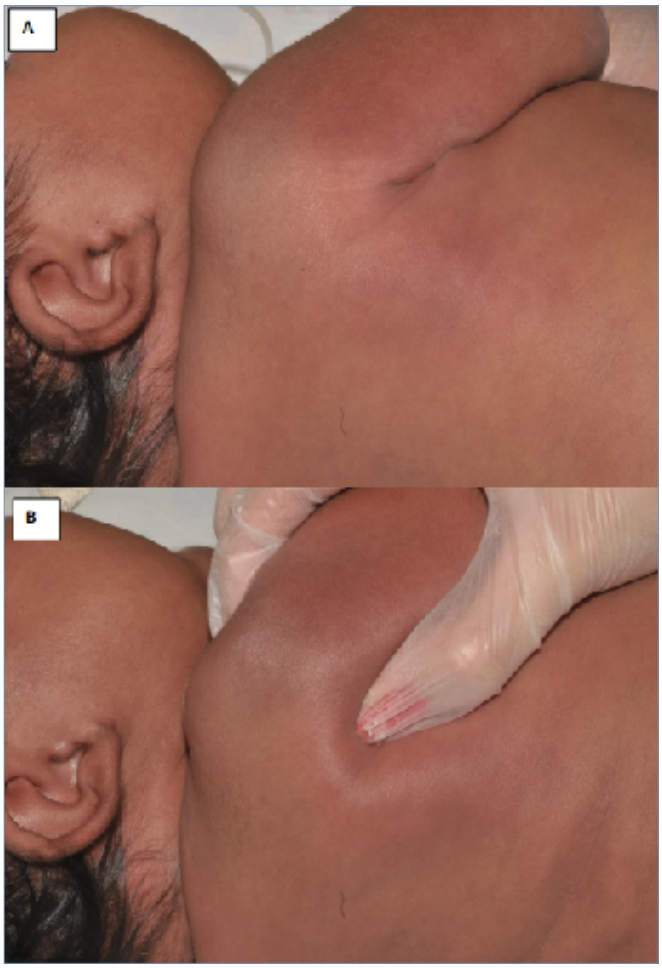

Figura 1. Hardened edema in the region of the right shoulder. (images authorized by the child's guardian).

The child was discharged at 41 days of life, weighing 4255g with generalized hypotonia, controlled seizures, using phenobarbital, and being followed up by neuropediatrics, neonatology, dermatology, in addition to a multidisciplinary team. At 2 months, she was still hypotonic, with small nodules in the subcutaneous tissue without phlogistic signs and the serum calcium level was within normal limits.

DISCUSSION

Subcutaneous fat necrosis or adipose necrosis of the newborn was first described by Harrison & McNee in 1926[5,6], and its pathogenesis remains unknown. It is believed to be related to tissue hypoxia that generates inflammation and necrosis in the subcutaneous adipose tissue[7]. It is an uncommon condition with an unknown incidence. A retrospective study, carried out in a tertiary center in Toronto, Canada, for 20 years, enrolled 30 children diagnosed with the disease, with no differences regarding gender[8].

Among the risk factors for the development of the disease are hypoxia and perinatal stress, common in prolonged labor, meconium aspiration, placenta previa, placental abruption, maternal diabetes, among other conditions[7,9]. In these cases, hypoperfusion of the subcutaneous tissue of the NB, whose enzymatic system responsible for the desaturation of fatty acids is immature, it worsens the deposition of saturated fatty acids (stearic acid and palmitic acid), leading to solidification and necrosis of the adipose tissue[10]; the local pressure resulting from the trauma associated with childbirth also potentiates fat necrosis. Therapeutic hypothermia is an additional risk factor, since tissue cooling induces adipocyte crystallization, also resulting in necrosis[1].

The clinical picture is characterized by areas of edema and erythema that progress to subcutaneous plaques or nodules, erythematous, hardened, painless, well-defined, located mainly in areas subjected to trauma during childbirth, such as the back, arms, thighs and buttocks; sometimes associated with a change in the color of the overlying skin (erythematous or violaceous)[4,6]. Lesions may eventually ulcerate. In addition to the skin lesions, newborns are generally well and without other changes on physical examination. Pain may occur and requires analgesia[1].

Diagnosis is clinical, based on history and physical examination. Imaging tests are generally unnecessary for diagnosis, although they can play an important role in ruling out differential diagnoses. Histopathological confirmation is made by the presence of areas of adipose necrosis, deposition of needle-shaped crystals, surrounded by a granulomatous reaction, consisting of lymphocytes, histiocytes, polymorphonuclear cells and multinucleated giant cells associated with calcification foci[1,4,11].

In all cases, total and/or ionized calcium levels should be monitored, as well as clinical signs of hypercalcemia, such as irritability, hypoactivity, vomiting, food refusal[12]. Hypercalcemia develops as a potentially fatal complication in some cases. The specific etiology for this phenomenon is unknown. One of the most accepted theories is the extrarenal production of 1,25-dihydrovitamin D by the macrophages of the granulomatous infiltrate, promoting the mobilization of calcium from the bone and increasing the intestinal absorption of calcium, resulting in secondary hypercalcemia[5,10]. Inflammatory granulomatous cells express high levels of 1-alpha-hydroxylase, the enzyme that converts 25-hydroxyvitamin D3 to its active form of 1,25-dihydroxyvitamin D3[13,14]. Possible links between hypercalcemia and increased prostaglandin E, which increase calcium reabsorption from bone, or parathyroid hormone levels have been studied; however, these are often normal[1].

The differential diagnosis is made with neonatal scleroderma, which appears mostly in premature newborns with serious pathologies such as sepsis, respiratory failure, heart failure or intestinal obstruction[2]. It is characterized by edema and generalized skin hardening. The palms, soles and genitals are spared[1,14]. Prognosis is poor and associated with high mortality. Another differential is cold panniculitis, which usually manifests itself with erythematous, hardened and well-defined plaques in places where the skin has been in direct contact with cold objects[3]. It usually appears within hours to days of exposure to cold and resolves quickly. Histopathologically, the absence of needle-like clefts in the fat distinguishes it from fat necrosis[1]. Other differentials include acute bacterial dermohypodermitis (erysipelas, cellulitis), abscesses, cytomegalovirus infection, deep hemangiomas, lipogranulomatosis (Farber's disease) and sarcomas[5,7].

In most cases, the evolution is benign, and the lesion resolves after a few months, without the need for treatment and without leaving sequelae[7]. Specific treatment is indicated when complications such as hypercalcemia occur, which in severe; and unmonitored cases can lead to death. Because the onset of hypercalcemia can be delayed, serum calcium levels should be monitored several months after diagnosis. Hypercalcemia is treated with supplemental calcium and vitamin D restriction, hyperhydration with intravenous fluids, and loop diuretics (furosemide)[6,12]. In more severe cases, systemic corticosteroids and bisphosphonates may be required[1].

In the case described, the patient had several risk factors for fat necrosis: term, prolonged expulsive period, born in poor vitality conditions, submitted to therapeutic hypothermia due to hypoxic ischemic encephalopathy, cardiogenic shock due to asphyxia, situations that lead to tissue and subcutaneous tissue hypoxia. A confounding factor was Gram-negative infection at the site of insertion of the venous catheter, which led the medical team to consider the differential diagnosis of abscess. In this situation, the imaging exam was useful for ruling it out. The maintenance of the skin condition despite clinical improvement, normalization of laboratory tests, negative blood cultures and the appearance of asymptomatic hypercalcemia at the end of the first month of life corroborated the diagnosis, which was confirmed by anatomopathological examination.

Although uncommon, early recognition of this morbidity, especially in newborns with risk factors, including therapeutic hypothermia, is important and can guide clinical follow-up, including calcium monitoring, pain control and not using antibiotics.

REFERENCES

1. Hunt R, Levy M L, Corona R. Subcutaneous fat necrosis of the newborn. UpToDate [internet] 2022 Abr; [citado 2020 Set 01]. Disponível em: https://www.uptodate.com/contents/subcutaneous-fat-necrosis-of-the-newborn?search=necrose%20gordurosa%20de%20subcut%C3%A2neo&source=search_result&selectedTitle=2~127&usage_type=default&display_rank=2.
2. Alves R, Freitas I, Santos I, Afonso A, Cardoso J. Necrose gorda do recém-nascido. Trab Soc Port Dermatol Venereol. 2011;69:103-5.
3. Monteiro R, Paulos L, Margatho M, Pereira M, Dinis A, Winckler L. Subcutaneous fat necrosis following induced hypothermia. Acta Pediatr Port. 2015;46:138-41.
4. Kannenberg SMH, Jordaan HF, Visser W I, Ahmed F, Bezuidenhout AF. Report of 2 novel presentations of subcutaneous fat necrosis of the newborn. Dermatopathology. 2019;6:147-52.
5. Fontes N, Amaral B, Oliveira A, Selores M, Pontes M, Coelho E. Complicação tardia de um parto traumático. Nascer e Crescer. 2014;21:161-3.
6. Cabral JEB, Ayres SS, Ferreira LCB, Albertoni DR. Necrose gordurosa do subcutâneo ou adipo necrose do recém-nascido. Descrição de um caso. J Pediatr (Rio J) 1994;70:178-80.
7. Oliveira ACS, Selores M, Pereira O. Necrose adiposa do recém-nascido - a propósito de dois casos clínicos. An Bras Dermatol. 2011;86:S114-7.
8. Del Pozzo-Magaña BR, Ho N. Subcutaneous fat necrosis of the newborn: a 20-year retrospective study. Pediatr Dermatol. 2016;33:e353.
9. O'Brien N, Hayes B. Subcutaneous fat necrosis of the newborn. BMJ Case Rep. 2019;12:e231458.
10. Chan D, Walinsundin WMS, Yap FKP, Koh MJA. Calcium management challenges in a macrosomic child with subcutaneous fat necrosis. BMJ Case Rep. 2019;12:e227141.
11. Agarwal M, Singh L, Khan N. A. Subcutaneous fat necrosis of the newborn: is fine needle aspiration cytology diagnostic? Act Cytol. 2019;63:75-7.
12. Shumer DE, Thaker V, Taylor GA, Wassner AJ. Severe hypercalcaemia due to subcutaneous fat necrosis: presentation, management and complications. Arch Dis Child Fetal Neonatal Ed. 2014;99:F419-21.
13. Farooque A, Moss C, Zehnder D, Hewison M, Shaw NJ. Expression of 25-hydroxyvitamin D3-1alpha-hydroxylase in subcutaneous fat necrosis. Br J Dermatol. 2009;160:423-5.
14. Stefanko NS, Drolet BA. Subcutaneous fat necrosis of the newborn and associated hypercalcemia: A systematic review of the literature. Pediatric Dermatol. 2019;36:24-30.