Residência RP Pediátrica
Publicação Oficial da Sociedade Brasileira de Pediatria
ISSN-Online: 2236-6814

Submitted on: 11/09/2020
Approved on: 08/29/2023

CASE REPORT

Aortopulmonary window: rare cardiopathy - case report

Gessianni Claire Alves de Souza[1,2], Caio César Melo Delgado[1], Helena Maria Fonseca de Souza[1], Rafaela Andrade Melo[1],Yngra Bastos Mesquita Minora de Almeida[1], Luziene Alencar Bonates dos Santos[3], Taiana Alves de Alcantara Andrade[4]

Keywords:
Aaortopulmonary window,
Pulmonary hypertension,
Children,
Heart failure.

Abstract

Aortopulmonary window is a congenital heart disease of low prevalence that results from anormalities in the septation of the commom arterial trunk. It is caracterized as a communication between the aorta and main pulmonary artery or its branches. This malformation resembles a large persistent ductus arteriosus. Clinical symptoms are related to pulmonary blood flow and the septal defect size. The aim of this paper is to report a case, inclunding his clinical presentation, the diagnostic work up, as well as the initial care at the emergency unit.

[1] Instituto de Medicina Integral - Professor Fernando Figueira, Pediatra - Recife - Pernambuco - Brazil.
[2] Instituto de Medicina Integral - Professor Fernando Figueira, Recife, Pernambuco, Residente em Cardiologia Pediátrica - Recife - Pernambuco - Brazil.
[3] Mestre em Saúde Materno-Infantil - IMIP/PE, Cardiologista Pediátrica do IMIP - Recife - Pernambuco - Brazil.
[4] Instituto de Medicina Integral - Professor Fernando Figueira, Cardiologista Pediátrica do IMIP - Recife - Pernambuco - Brazil.

Correspondence to:
Luziene Alencar Bonates dos Santos.
Instituto de Medicina Integral Professor Fernando Figueira (IMIP). Rua dos Coelhos, nº 300, Boa Vista, Recife, PE, Brazil. CEP: 50070-902. E-mail: pedimip2019@gmail.com

Resid Pediatr. 2023;13(3). DOI: 10.25060/residpediatr-2023.v13n3-505

Este trabalho está licenciado sob uma Creative Commons Attribution 4.0 International License.

INTRODUCTION

The aortopulmonary window (APW) is a rare congenital heart anomaly representing 0.2%-0.6% of all congenital heart lesions.[1,2] There is a communication between the aorta and the pulmonary artery, with two separate arterial valves.

Patients with APW have a left-to-right shunt; therefore, when this malformation is alone and large, the clinical presentation is due to increased pulmonary flow, with congestive heart failure, pulmonary hypertension and early development of obstructive pulmonary vascular disease.[3]

In around 50% of cases there is an association with another heart defect, which makes it difficult to recognize the anomaly. The association with aortic arch interruption is the most common, increasing the condition severity.

The clinical diagnosis of APW, although difficult, should always be remembered in children with early cardiac decompensation and poor weight gain. Due to the non-specificity of usual exams such as chest x-ray and electrocardiogram, the echocardiogram, although operator dependent, is recognized as the exam of choice.

The prognosis of untreated cases is poor, yielding 40% mortality in the first year of life.[4] APW surgical closure is indicated in all patients and should be performed as soon as the diagnosis is made to prevent the development of severe pulmonary arterial hypertension (PAH).

OBJECTIVE

To report a case of a child treated in a pediatric emergency setting due to fatigue and coughing since birth, associated with feeding difficulties and weight loss. We expect to contribute to facilitating diagnosis and treatment approaches.

METHODOLOGY

This report was based on the patient's care record and a bibliographic review in the main medical databases (PUBMED and BIREME), searching for papers that covered the subject. There were 15 papers related to the topic, from 2007 to 2017.

CASE REPORT

This is the case of a 5-month-old male infant, born by cesarean section, at term, Apgar 9/10, admitted to this clinic due to worsening respiratory distress, intense irritability and cyanosis after three days of hospitalization in the hospital in the region where he lives. He had a history of recurrent respiratory infections, tiredness and difficulty gaining weight since birth.

Upon admission, he presented with intense irritability and significant respiratory distress. On physical examination, he had a bulging in the precordial region, respiratory rate of 50 breaths per minute, subcostal indrawings, heart rate of 190 beats per minute, with oxygen saturation of 96% in a 50% Venturi mask. There was an audible systolic murmur at the upper left sternum border, hepatomegaly and diffuse bullous rales on lung auscultation. The chest X-ray revealed a globally enlarged cardiac area with signs of pulmonary hyperflow (figure 1). The electrocardiogram showed biventricular overload. An echocardiogram was performed (figure 2), which showed a proximal aortopulmonary window (type I), a patent foramen ovale, signs of significant hyperflow and pulmonary arterial hypertension (systolic pressure estimated at 53 mmHg), with a significant increase in the left chambers and preserved biventricular function. Drug treatment with furosemide, digitalis and captopril was initiated. He underwent surgical repair (figure 3) in the same hospitalization, without technical complications, with dissection and ligation of the aortopulmonary window. The patient evolved well and was extubated in the immediate postoperative period and sent to the ICU, where he remained for 2 days to manage heart failure using furosemide and captopril. He was discharged from hospital on the seventh day after surgery, without any complications.

DISCUSSION

The aortopulmonary window is a defect that does not close spontaneously or decrease in size with time and growth. Embryologically, it is a defect explained by incomplete fusion or malformation of the right or left conotruncal defect between the fifth and eighth week of intrauterine life. The differential diagnosis includes the patent ductus arteriosus and truncus arteriosus.[5,6] The clinical impact on patients depends on the size of the window and the presence of associated lesions, in addition to the progression to pulmonary hypertension, due to

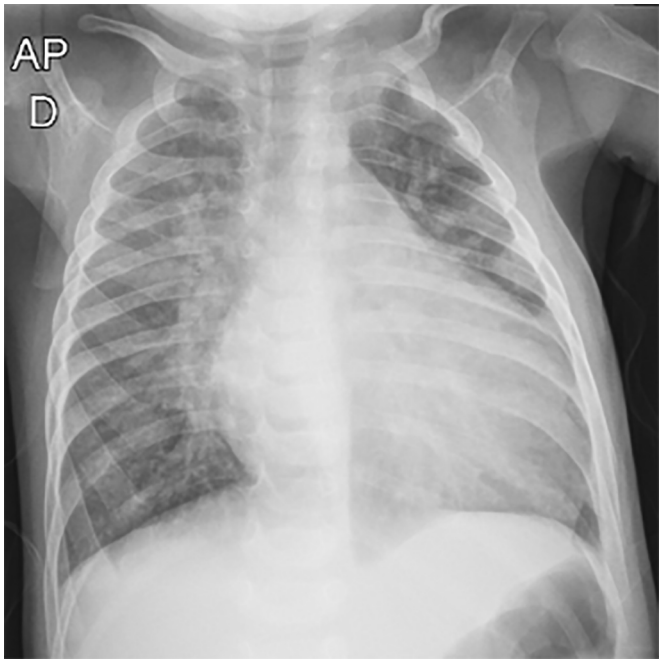

Figure 1. Chest X-ray with globally enlarged cardiac area with signs of pulmonary hyperflow.

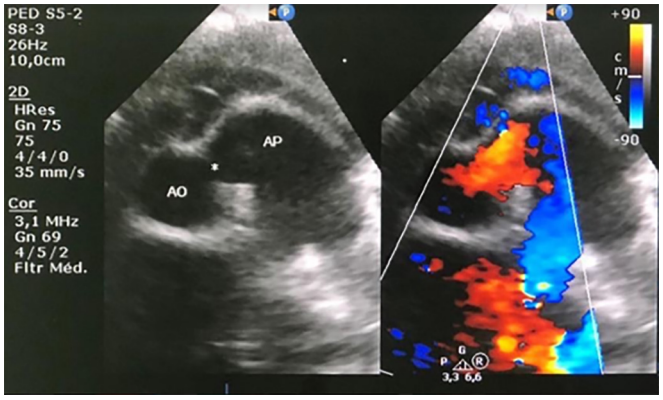

Figure 2. Large and proximal aortopulmonary window, measuring approximately 7.8 mm, with left-right flow.

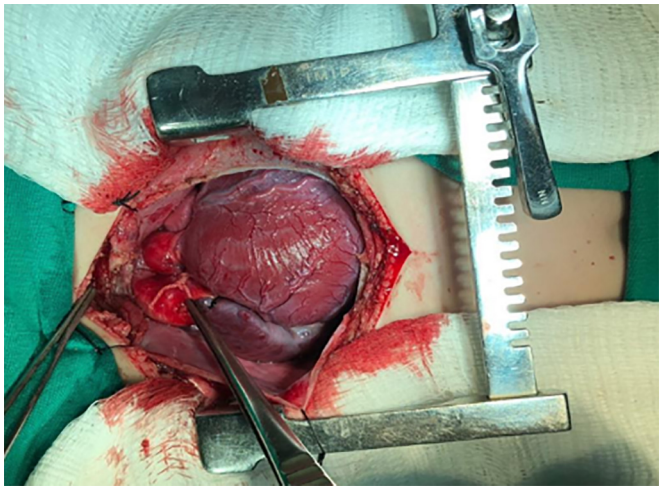

Figure 3. Proximal aortopulmonary window identified with surgical forceps.

the large deviation of blood flow from left to right. The most commonly used classification is Richardson: Type I – proximal (most common); Type II – distal defect; Type III – complete defect.[7]

Prenatal diagnosis is very rare, although it is very important to advance surgical correction and prevent the development of congestive heart failure. The main diagnosis feature is a demonstration of the connection between the pulmonary artery and the aorta above the level of the artery two semilunar valves[8] on obstetric ultrasound.

The vast majority of patients present with a history of tachypnea or respiratory distress, recurrent lower respiratory tract infections, inability to grow adequately and congestive heart failure, just like the patient in the exposed case. Chest radiography may show cardiomegaly, and the diagnosis of APW is usually confirmed on echocardiography.

Most patients with this condition develop severe clinical symptoms with congestive heart failure or pulmonary hypertension early in life; therefore, surgical intervention is indicated as soon as the diagnosis is made. According to Barnes at al., in the absence of correction the prognosis is poor and depends on the presence of other associated congenital heart malformations; mortality can reach 40% in the first year of life.

Approaches include simple ligation, division and suture, transpulmonary approach, direct transaortic closure, transaortic polyester patches, and the sandwich technique. The initial and long-term results after surgical correction are excellent, regardless of age or pulmonary resistance, as observed in the study by D. Gowda et al. It was also seen that in patients with ventricular dysfunction, after surgery, the dysfunction regressed, as well as the reduction in afterload and diuretics during follow-up.

CONCLUSION

The aortopulmonary window is a rare anomaly, but well-defined and surgically correctable. Surgical repair should be offered as soon as the diagnosis is established, regardless of patient age, with good long-term results. The objective of this review was to present the uncommon diagnosis, but which should be considered in patients with respiratory distress, signs of heart failure and recurrent respiratory infections.

REFERENCES

1. Talwar S, Agarwal P, Choudhary SK, Kothari SS, Juneja R, Saxena A, et al. Aortopulmonary window: Morphology, diagnosis, and long-term results. J Card Surg. 2017 Feb;32(2):138-44. DOI: 10.1111/jocs.12936.
2. Talwar S, Siddharth B, Gupta SK, Choudhary SK, Kothari AA, Juneja R, et al. Aortopulmonary window: results of repair beyond infancy. Interact Cardiovasc Thorac Surg. 2017 Nov;25(5):740-4. DOI: 10.1093/icvts/ivx158.
3. Gangana CS, Malheiros AFA, Alves EV, Azevedo MA, Bernardes RM, Simões LC. Janela aortopulmonar: impacto das lesões associadas no resultado cirúrgico. Arq Bras Cardiol. 2007;88(4):402-7.
4. Demir IH, Erdem A, Saritas T, Demir F, Erol N, Yucel IK, et al. Diagnosis, treatment and outcomes of patients with aortopulmonary window. Balkan Med J. 2013 Jun;30(2):191-6. DOI: 10.5152/balkanmedj.2013.6995.
5. Gowda D, Gajjar T, Rao JN, Chavali P, Sirohi A, Pandarinathan N, et al. Surgical management of aortopulmonary window: 24 years of experience and lessons learned. Interact Cardiovasc Thorac Surg. 2017 Aug;25(2):302-9. DOI: 10.1093/icvts/ivx099.
6. Tongprasert F, Sittiwangkul R, Jatavan P, Tongsong T. Prenatal diagnosis of aortopulmonary window: a case series and literature review. J Ultrasound Med. 2017 Aug;36(8):1733-8.
7. Barnes ME, Mitchell ME, Tweddell JS. Aortopulmonary window. Semin Thorac Cardiovasc Surg Pediatr Card Surg Annu. 2011;14(1):67-74. DOI: 10.1053/j.pcsu.2011.01.017.
8. Kumar A, Singh DK, Gupta VK. Aortopulmonary Window: A Rare Congenital Heart Defect. J Clin Diagn Res. 2016 Aug;10(8):PJ01-2. DOI: 10.7860/JCDR/2016/19412.8244.