Residência RP Pediátrica
Publicação Oficial da Sociedade Brasileira de Pediatria
ISSN-Online: 2236-6814

Submitted on: 10/02/2022
Approved on: 15/06/2023

ORIGINAL ARTICLE

Expanding the applicability of ultrasonography in the neonatal sphere: in addition to cerebral hemorrhages

Julia Amim Rosa[1], Milena Rasche[1], Gabrielly de Araujo[1], Marcia Wang Matsuoka[1], Mário Cícero Falcão[1], Fabiola Roberta Marim Bianchini[1], Laura Emilia Monteiro Bigelli Cardoso[1], Lisa Suzuki[1]

Keywords:
Ultrasonography,
Spine,
Lung,
Cranial sutures,
Infant
Newborn.

Abstract

Introduction: Neonatal ultrasound began in the 1970s to evaluate cerebral hemorrhages. With the advent of different transducers and improvement of the technological devices (Doppler function), its use has greatly expanded, being possible the evaluation many organs. **Objectives:** The study aims to show new applicability of ultrasonography, as an auxiliary method in the diagnosis of spinal alterations, pulmonary diseases, and cranial sutures in the neonatal period. **Methods:** Descriptive study of ultrasound examinations performed with the Logiq P7 device of General EletricT, with multifrequency and microconvex transducers with frequency of 3 to 11 MHz and linear with frequency of 2 to 11 MHz. Ultrasound evaluations were performed immediately after diagnostic suspicion, by a specialist physician with more than 15 years of experience in pediatric ultrasound, provided that the clinical condition of the newborn allowed the examination and, if there was a need, a new ultrasound would be performed for diagnostic confirmation. **Results:** Presentation of ultrasound images performed routinely in a neonatal tertiary-level unit, including evaluations of spine, lungs and skull bones presented as well: 1. Ultrasonography of normal neonatal spine (medullary cone and cauda equina). 2. Normal neonatal chest ultrasound, with the presence of A-lines and rare B-lines, and graphic representation of normal diaphragmatic mobility. 3. Ultrasound of the pervious and closed sagittal cranial suture. **Conclusions:** Ultrasonography has several applicability, and its use in the neonatal population favors satisfactory the diagnosis and follow-up of various pathologies, in a noninvasive and innocuous manner, reserving the other diagnostic methods for cases in which diagnostic complementation is necessary.

[1] Instituto da Criança e do Adolescente, Departamento de Pediatria - São Paulo - São Paulo - Brazil.

Correspondence to:
Mário Cícero Falcão.
Instituto da Criança e do Adolescente. Av. Dr. Enéas Carvalho de Aguiar, 647 - Cerqueira César, São Paulo - SP, Brasil.
CEP: 05403-000. E-mail: mario.falcao@hc.fm.usp.br

DOI: 10.25060/residpediatr-2023.v13n3-836

This work is licensed under a Creative Commons Attribution 4.0 International License.

INTRODUCTION

The use of ultrasound (USG) in neonatal units has proven to be very useful in daily practice in the diagnosis and monitoring of diseases already established, such as cerebral hemorrhages and ventricular dilations[1,2]. However, with the advent of various transducers, portable ultrasound devices and the evolution of other specialties, there has been an increase in their use for diagnosis and monitoring of several reasonably common diseases in neonatology, which were previously not evaluated from an ultrasound perspective, as in evaluation of occult dysraphism in the spine, in the main neonatal pulmonary pathologies, such as transient tachypnea of the newborn (TTN), respiratory distress syndrome (RDS) and in the cephalic segment, in the evaluation of cranial sutures, when there is a suspicion of early closure[3-5].

The use of USG in the diagnosis and monitoring of cranial hemorrhages is already well established[6]. Using this method, it is possible to evaluate and monitor the severity of the disease using the Papile classification, which differentiates the various degrees of hemorrhage into grades I, II, III and IV; depending on the location where the hemorrhage occurred[7]. Since the introduction of ultrasound in perinatal care in the end of the 1970s, with the advent of portable devices and the development of the various transducers currently available, there has been a significant improvement in the quality of images and the possibility of execution[8]. In the past, ultrasound evaluations were mainly used to examine the ventricular system, as well as to diagnose intraventricular hemorrhages and periventricular cysts[9]. Nowadays, ultrasound provides details that could not be seen in older devices, enabling the well-trained observer to detect minor changes that were previously not identifiable, such as small neonatal hemorrhagic and ischemic brain lesions, congenital abnormalities and changes in brain maturation[10].

Using the Doppler function, available on current ultrasound devices, it is also possible to evaluate the vascularization in different organs, enabling one to visualize vascular architecture characteristics and the evaluation of the flow inside the analyzed vessel, whether artery or vein[11].

In addition to the cranial segment, it is also possible to evaluate the abdominal segment, where it is possible to characterize the abdominal anatomy, including visualization of the kidneys, ureters (when distended) and bladder, in the search for possible malformations or pathologies, such as, for example, hydronephrosis[12].

It is worth mentioning that the use of USG in the neonatal population in particular has several advantages: the advent of portable devices favors its performance at the bedside, thus avoiding excessive manipulation and displacement of the newborn, sometimes very premature or unstable as far as the ultrasound device is located[13]. Furthermore, it is a painless and innocuous imaging method, which can be performed whenever necessary, and it is a way of evaluating the dynamics of the structure to be studied, such as assessing diaphragmatic and pulmonary mobility, assessing the presence or absence of intestinal peristalsis, the characterization of possible ureteroceles in the suspicion of an obstruction in the urinary tract, not visible on other imaging methods, such as radiography and computed tomography[12].

Furthermore, the pediatric population has advantages over the adult population when acquiring images; because in them the muscles are poorly developed and have little adipose tissue. In neonates, in particular, the little calcification of bone structures, sometimes still cartilaginous, allows the ultrasound beam to pass through, enabling the characterization of spinal cord structures[13].

In this context, the present study aims to disseminate the possibility of expanding its use due to its ease of use, as an ancillary method in the diagnosis of spinal disorders, pulmonary disorders and cranial sutures in the neonatal period.

METHODS

Ultrasonographic images of exams routinely performed in a tertiary-level Neonatal Unit are presented, including assessments of the spine, lungs and skull bones.

The exams demonstrated here were carried out on the device available at the service, a Logiq P7 from General Electric™, with multi-frequency and microconvex transducers with a frequency of 3 to 11 MHz and linear transducers with a frequency of 2 to 11 MHz.

To perform spinal USG, the newborn was preferably positioned in the prone position, with a cushion in the abdominal region to increase the intervertebral space and thus facilitate the characterization of the spinal cord; The spinal canal is then scanned using a linear transducer.

To perform pulmonary USG, the rec The newborn was kept in the horizontal supine position and the entire chest was scanned bilaterally using a linear transducer.

To perform USG of the skull, to evaluate the cranial sutures, the newborn was preferably positioned in an orthostatic position on the lap, allowing scanning of the metopic, sagittal, right and left coronal and right and left lambdoid sutures, as well as the anterior fontanel. Whenever possible, the examination was performed on newborns who were in good clinical condition, without the need for ventilatory support or incubators.

RESULTS

The authors sought to show ultrasound images of exams routinely performed in neonatal units, using ultrasound equipment and transducers frequently available in inpatient units, and with already established use in adults.

With the use of USG in the evaluation of the neonatal spine (Figure 1), through the still cartilaginous vertebrae, it is possible to outline medullary characteristics, as well as their positioning within the medullary canal, and it also enables one to assess their mobility, which must be present in a normal

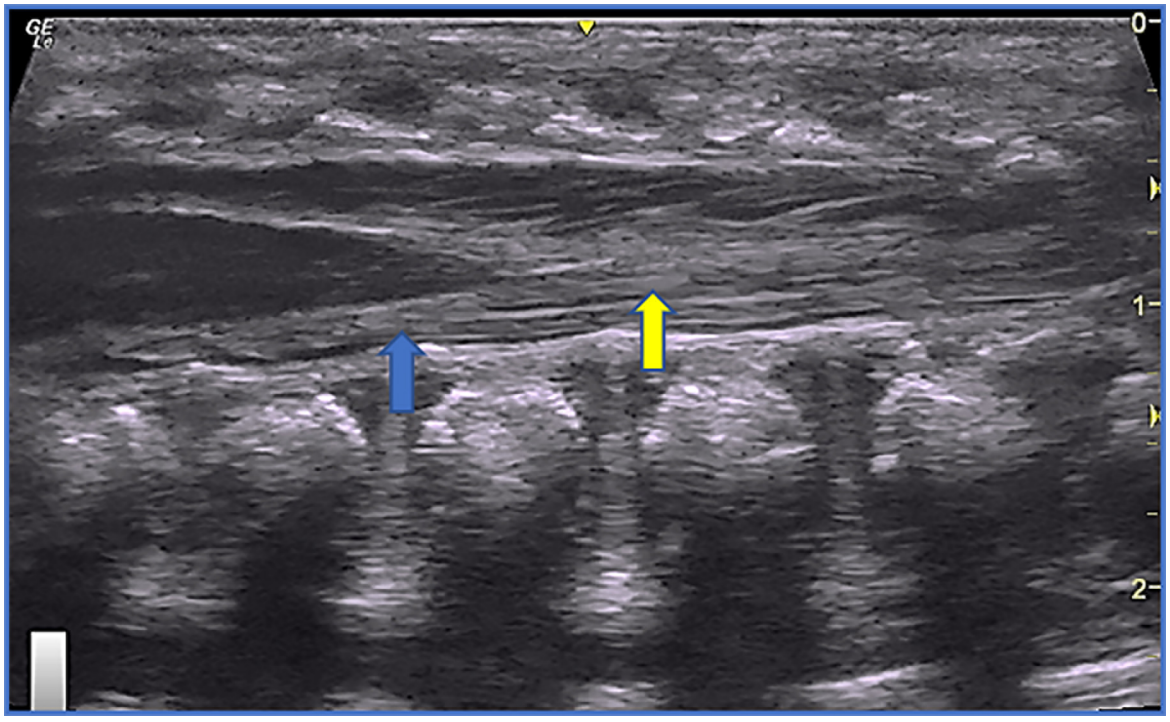

Figure 1. Normal neonatal spine USG image. Medullary cone (blue arrow), cauda equina (yellow arrow).

marrow. Using USG, it is possible to assess the positioning and morphology of the medullary cone, evaluate and rule out the presence of tumors such as cysts and lipomas; which can eventually cause damage due to compression in the nerve roots, and one can evaluate possible fistulous paths in the sacral pits[3].

When evaluating the neonatal chest, it is possible to perform a very satisfactory examination of pathologies that alter the lung surface, such as pulmonary consolidations, effusion and pleural thickening; and in intensive care units, in particular, USG enables diagnosis and monitoring of pathologies inherent to the neonatal period, such as TTNB and RDS[14].

In the normal chest, we can normally see A lines, and rare B lines (Figure 2), and the loss of these normal ultrasound signs may be associated with diseases. The A lines appear below the pleural line, appearing, at the same time, to be horizontally parallel and equidistant from each other and represent reverberation artifacts, usually found in healthy lungs. B lines are vertical beams that start from the visceral pleura and advance to deeper portions of the chest. These B lines are generated by an air/liquid mixture in lung tissue.

Furthermore, USG, since it is a dynamic method, enables the identification of pulmonary and diaphragmatic mobility, being superior to chest radiography for this purpose. In cases in which there is a suspicion of reduction in diaphragmatic mobility or bronchial selection after intubation, for example, USG enables this assessment to be carried out quickly and harmlessly (Figure 3)[15].

Recently, USG has proven to be a very satisfactory method for evaluating cranial sutures, previously evaluated using computed tomography, which uses radiation for its purposes. With USG, it is possible to evaluate postural plagiocephaly, unrelated to the early closure of cranial sutures (Figure 4)[16].

DISCUSSION

USG, as it is a painless, non-invasive and radiation-free imaging method, is excellent for use with the general population, especially pediatrics; and currently, with the availability of portable devices, its use at the bedside has been favored[6]. In neonatal units, in particular, this characteristic stands out even more, because it is not unnecessary to transport a newborn, sometimes unstable, to the sector where the ultrasound device is located to perform the exam[17].

In the newborn's spine, due to the little calcification of the vertebrae and lower paravertebral muscle mass, as well as the presence of little local adipose tissue, the characterization of the spinal canal and its components is quite satisfactory in the first months of life. Thus, through USG, as an initial imaging study, it is possible to evaluate anatomical structures such as the spinal cord, nerve roots, evaluate the positioning of the conus medullaris, dynamic characterization of the normal mobility of the spinal cord (Figure 1), as well as the identification of hidden diseases, such as lipomas, cysts and local malformations[18]. Using USG, it is possible to diagnose changes in the spinal cord such as its anterior or posterior displacement within the spinal canal, loss of its normal mobility, morphological changes such as the rounded rather than tapered medullary cone, as well as its abnormal positioning, usually located at the site of the L1/L2 vertebrae[19,20].

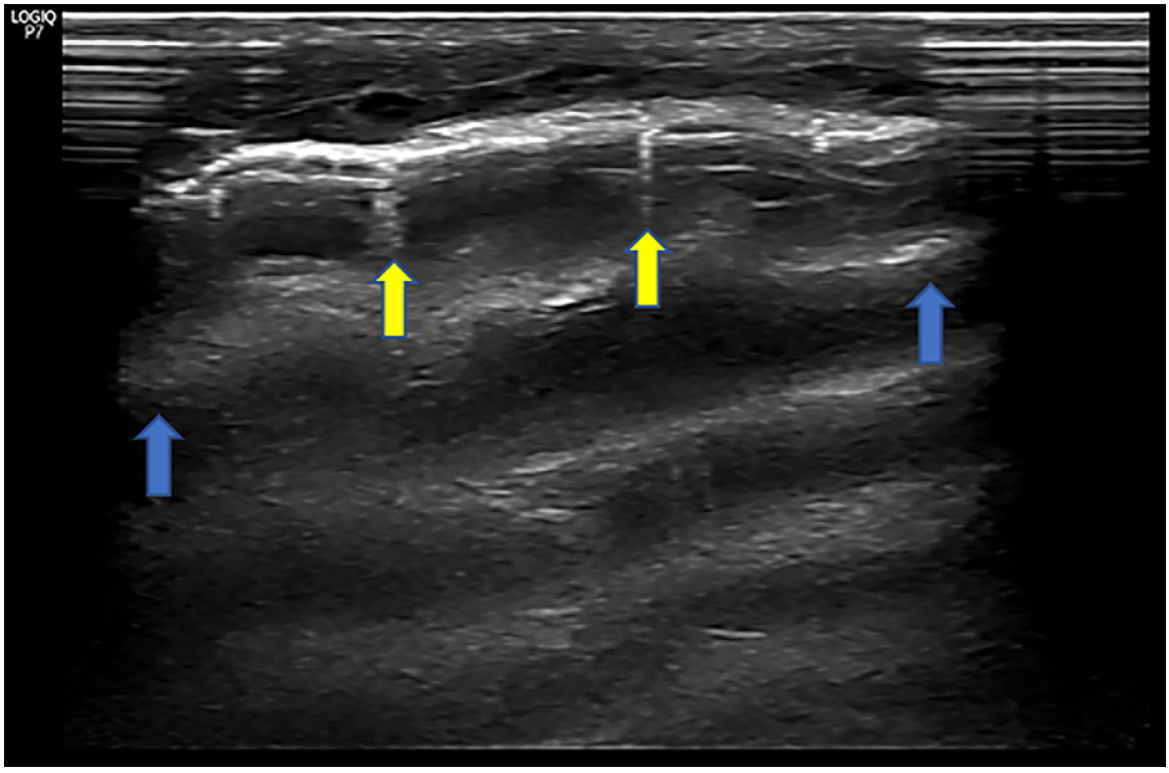

Figure 2. Normal neonatal chest USG. Presence of A lines (blue arrow) and rare B lines (yellow arrow).

Where there are alterations, and in cases where USG is not completely informative or for pre-surgical evaluation, magnetic resonance imaging is indicated, and NB sedation[3] is sometimes necessary to carry it out.

The study of the neonatal chest is also possible using USG, especially in pathologies that affect the lung surface. Especially in newborns, diseases inherent to this age range, such as TTNB, RDS and other conditions such as pneumonia, strokes and, more recently, lung injuries caused by SARS-CoV-2, can be diagnosed and monitored by USG; thus avoiding the unnecessary carrying out of excessive chest x-rays, which uses radiation to perform them, with a consequent cumulative effect[14,21]. In the normal chest, it is possible to identify A lines and a few B lines, as well as pleural sliding and diaphragmatic mobility (Figures 2 and 3). In the presence of pathologies such as TTNB and RDS, there is total or partial loss of the usually observed signs, with the presence of a diffusely echogenic lung in TTNB and pleural irregularity and areas with a solid appearance in RDS, which appearance resembles the lung affected by SARS-CoV-2. In pneumonia, one can see a lung with a solid appearance, reflecting pulmonary consolidation, and in effusions there is pleural fluid, which when simple appears anechoic, and when complicated, may present particles in suspension and/or septations[22].

Furthermore, USG enables the diagnosis of very small changes, sometimes millimeters, that would not be evident on chest x-ray, such as small effusions and small consolidations. Furthermore, USG enables the diagnosis of changes that sometimes occur concomitantly, such as strokes associated with pulmonary consolidations[21]. More recently, there have been papers published demonstrating the applicability of USG to evaluate the positioning of the orotracheal intubation cannula, making it possible to evaluate its positioning by characterizing diaphragmatic mobility bilaterally, when the positioning is correct, and by directly characterizing the distal end of the cannula inside the trachea using USG[14].

Even more recent is the use of USG to evaluate cranial sutures, as it is perfectly possible to characterize them using this diagnostic method. There was an increase in such evaluation after the guidance from the American College of Pediatrics for children to sleep in the supine position to reduce cases of sudden death. With these reports there was an increase in cases of postural plagiocephaly, without the need for surgical intervention[23].

Normal sutures are seen through USG as a discontinuity between the skull bones where the sutures (metopic, sagittal, coronal and lambdoid) are located (Figure 4 A). The surface i.e., bone, with adjustment and use of appropriate transducers, appears as linear echogenic lines and the sutures as a hypoechogenic interval between the bone echogenic lines. When the sutures are closed (Figure 4 B), this discontinuity is no longer characterized, and one may even see local bulging[23]. In this way, USG enables the diagnosis of this change, in addition to allowing the characterization of closed sutures, reserving computed tomography of the skull with three-dimensional reconstruction (3D-CT) for when USG is inconclusive and for

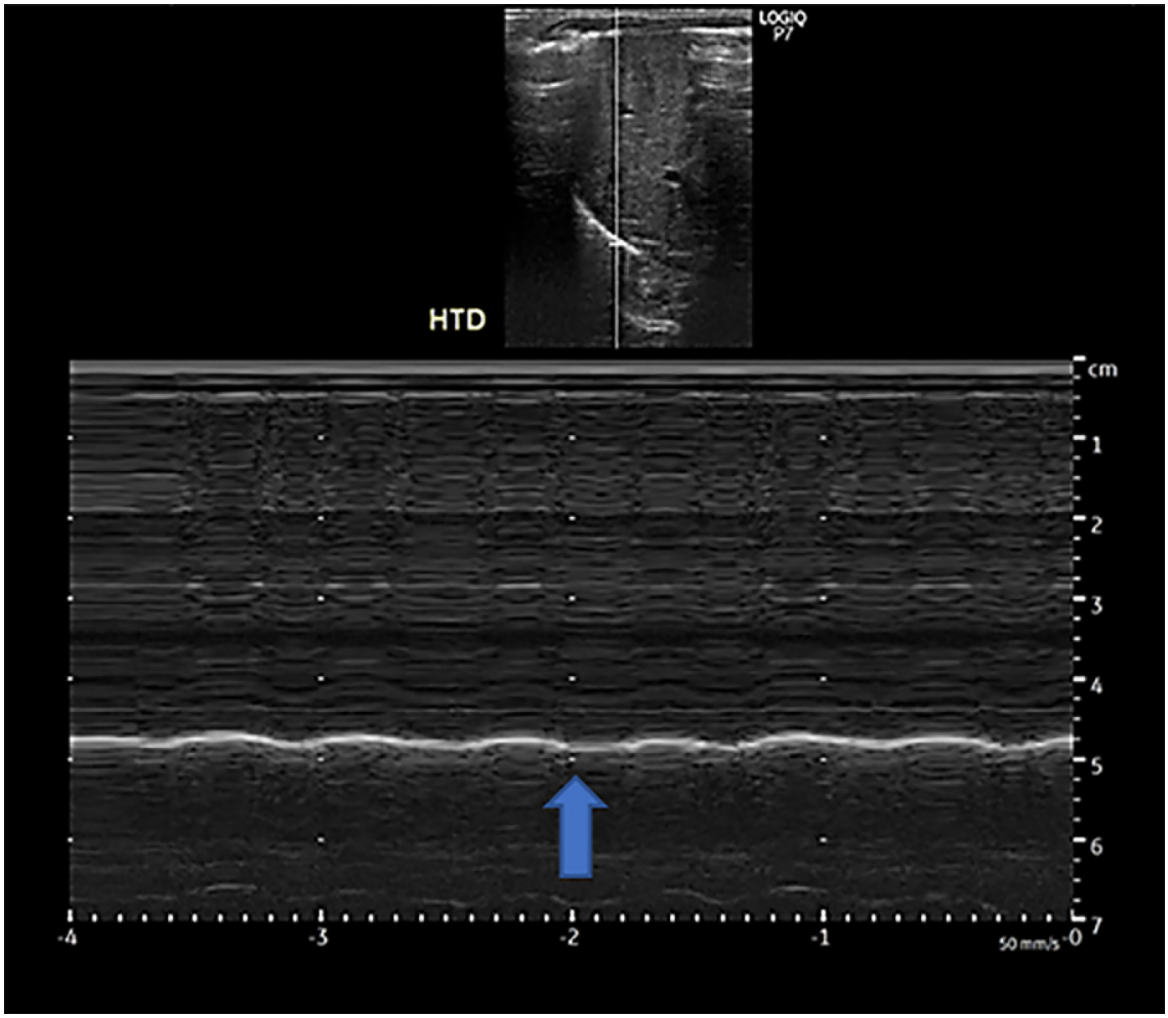

Figure 3. Graphical representation of normal diaphragmatic mobility (blue arrow).

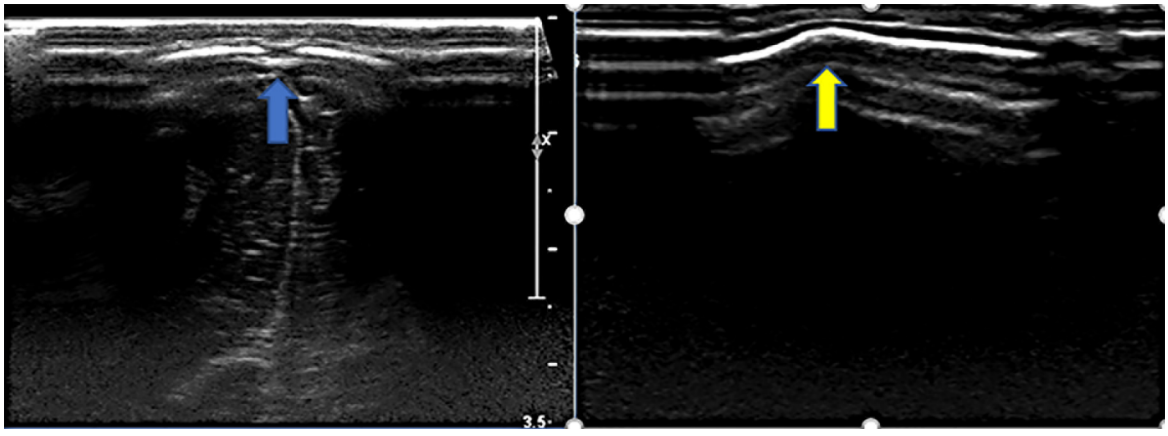

Figure 4. Sagittal cranial suture USG. A: patent, normal (blue arrow), B: closed (yellow arrow).

pre-surgical evaluations[5]. To perform 3D-CT, it is necessary, as in chest radiography, to use radiation, but at higher doses.

CONCLUSION

USG is an imaging method with diverse applicability, and its use, in the neonatal population in particular, favors the diagnosis and satisfactory monitoring of various pathologies, in a non-invasive and harmless manner, reserving other diagnostic methods for cases in which it is necessary as diagnostic complementation.

REFERENCES

1. Dudink J, Steggerda SJ, Horsch S; eurUS.brain group. State-of-the-art neonatal cerebral ultrasound: technique and reporting. Pediatr Res. 2020;87(Suppl 1):3-12.
2. van Wezel-Meijler G, Steggerda SJ, Leijser LM. Cranial ultrasonography in neonates: role and limitations. Semin Perinatol. 2010;34(1):28-38.
3. Orman G, Tijssen MPM, Seyfert D, Gassner I, Huisman TAGM. Ultrasound to Evaluate Neonatal Spinal Dysraphism: A First-Line Alternative to CT and MRI. J Neuroimaging. 2019;29(5):553-64.
4. Liu J, Lovrenski J, Ye Hlaing A, Kurepa D. Neonatal lung diseases: lung ultrasound or chest x-ray. J Matern Fetal Neonatal Med. 2021;34(7):1177-82.
5. Vargo JD, Hasan A, Andrews BT. Identification and Management of Cranial Anomalies in Perinatology. Clin Perinatol. 2018;45(4):699-715.
6. Steggerda SJ, Leijser LM, Walther FJ, van Wezel-Meijler G. Neonatal cranial ultrasonography: how to optimize its performance. Early Hum Dev. 2009;85(2):93-9.
7. Papile LA, Burstein J, Burstein R, Koffler H. Incidence and evolution of subependymal and intraventricular hemorrhage: a study of infants with birth weights less than 1,500 gm. J Pediatr. 1978;92(4):529-34.
8. Pape KE, Blackwell RJ, Cusick G, Sherwood A, Houang MT, Thornurn RJ, et al. Ultrasound detection of brain damage in preterm infants. Lancet. 1979;1(8129):1261-4.
9. Levene MI, Wigglesworth JS, Dubowitz V. Hemorrhagic periventricular leukomalacia in the neonate: a real-time ultrasound study. Pediatrics. 1983;71(5):794-7.
10. Steggerda SJ, Leijser LM, Walther FJ, van Wezel-Meijler G. Neonatal cranial ultrasonography: how to optimize its performance. Early Hum Dev. 2009;85(2):93-9.
11. Miller E, Daneman A, Doria AS, Blaser S, Traubici J, Jarrin J et al. Color Doppler US of normal cerebral venous sinuses in neonates: a comparison with MR venography. Pediatr Radiol. 2012;42(9):1070-9.
12. Hálek J, Flögelová H, Michálková K, Smakal O, Dubrava L, Zapletalová J, et al. Diagnostic accuracy of postnatal ultrasound screening for urinary tract abnormalities. Pediatr Nephrol. 2010;25(2):281-7.
13. Boyd S, Kluckow M. Point of care ultrasound in the neonatal unit: Applications, training and accreditation. Early Hum Dev. 2019;138:104847.
14. Corsini I, Parri N, Ficial B, Dani C. Lung ultrasound in the neonatal intensive care unit: Review of the literature and future perspectives. Pediatr Pulmonol. 2020;55(7):1550-62.
15. Francisco MJ Neto, Rahal A Junior, Vieira FAC, Silva PSD, Funari MBG. Advances in lung ultrasound. Einstein (Sao Paulo). 2016;14(3):443-8.
16. Steggerda SJ, de Bruine FT, Smits-Wintjens VEHJ, Walther FJ, van Wezel-Meijler G. Ultrasound detection of posterior fossa abnormalities in full-term neonates. Early Hum Dev. 2012;88(4):233-9.
17. Di Salvo DN. A new view of the neonatal brain: clinical utility of supplemental neurologic US imaging windows. Radiographics. 2001;21(4):943-55.
18. McGovern M, Mulligan S, Carney O, Wall D, Moylett E. Ultrasound investigation of sacral dimples and other stigmata of spinal dysraphism. Arch Dis Child. 2013;98(10):784-6.
19. Lowe LH, Johanek AJ, Moore CW. Sonography of the neonatal spine: part 1, normal anatomy, imaging pitfalls, and variations that may simulate disorders. AJR Am J Roentgenol. 2007;188(3):733-8.
20. Lowe LH, Johanek AJ, Moore CW. Sonography of the neonatal spine: part 2, Spinal disorders. AJR Am J Roentgenol. 2007;188(3):739-44.
21. Sharma D, Farahbakhsh N. Role of chest ultrasound in neonatal lung disease: a review of current evidences. J Matern Fetal Neonatal Med. 2019;32(2):310-6.
22. Matsuoka MW, Rocha SMS, Gibelli MABC, Nicolau CM, Carvalho WB, Suzuki L. Uso da ultrassonografia pulmonar em recém-nascidos durante a pandemia da COVID-19. Radiol Bras. 2020;53(6):401-4.
23. Rozovsky K, Udjus K, Wilson N, Barrowman NJ, Simanovsky N, Miller E. Cranial Ultrasound as a First-Line Imaging Examination for Craniosynostosis. Pediatrics. 2016;137(2):e20152230.