Residência RP Pediátrica
Publicação Oficial da Sociedade Brasileira de Pediatria
ISSN-Online: 2236-6814

Submitted on: 06/30/2021
Approved on: 09/06/2021

CASE REPORT

Cri Du Chat Syndrome: report of a neonatal case and evolution up to nine months of age.

Layssa Marinho Aguiar[1], Carlos Alberto Moreno Zaconeta[1],Tatiane Martins Barcelos[1], Aldo Roberto Ferrini Filho[1]

Keywords:
Cri-du-Chat syndrome, Chromosome deletion, Microcephaly.

Abstract

Cri Du Chat Syndrome (SCDC) is a genetic syndrome that must be recognized and diagnosed as soon as possible for early follow-up and multidisciplinary intervention. We describe the case of a female newborn who was suspected at SCDC at delivery room due to high-pitched crying and facial asymmetry. We also describe the investigation until the final diagnosis and the clinical evolution up to nine months of age of the child. After the diagnosis was confirmed, our pacient received hospital discharge with follow-up of multidisciplinary team in order to reduce development impairments.

[1] Hospital Materno Infantil de Brasília, Departamento de Neonatologia - Brasília - Distrito Federal - Brasil.

Correspondence to:
Layssa Marinho Aguiar.
Hospital Materno Infantil de Brasília. Av. L2 Sul SGAS Quadra 608 Módulo A - Asa Sul, DF, 70203-900. E-mail: layssamarinhoaguiar@gmail.com

Resid Pediatr. 2023;13(4).
DOI: 10.25060/residpediatr-2023.v13n4-671

This work is licensed under a Creative Commons Attribution 4.0 International License.

INTRODUCTION

5p- syndrome, also known as cri du chat (cat's cry) syndrome (CCS), has an incidence of approximately 1:45,000 live births. In 85% of the cases CCS results from a partial deletion of the short arm of chromosome 5, while the remaining cases derive from parental translocation involving 5p[1].

The diagnosis of CCS is based on typical clinical manifestations. Karyotyping is performed as a confirmatory test. Clinical manifestations vary according to chromosomal alterations. However, chromosomal bands 5p15.2 and 5p15.3 are always involved and cover the critical region for the condition's phenotype[2,3].

CASE REPORT

A female infant was born from a cesarean section due to arrested labor at 39 weeks of gestation. Her birth weight was 3,205g (appropriate for gestational age), length was 50cm, and head circumference was 33cm. She was the daughter of non-consanguineous parents. Her mother had no history of pregnancy or miscarriage or known cases of genetic syndromes in the family. She said she did not drink alcohol or take drugs during pregnancy. The infant was born in good clinical condition (Apgar 9/9) and did not require without neonatal resuscitation.

During early physical examination in the delivery room, the infant had a high-pitched cry and facial and cranial asymmetries. She was placed on rooming-in and the opinion of a geneticist was requested. While in rooming-in, she showed good acceptance of her mother's breast and had a preference for keeping her head turned to the left. Four days after birth, she was evaluated by a geneticist, who described the following findings: plagiocephaly, forehead asymmetry, eyebrow hair rarefaction, high nasal root, high nasal dorsum, oblique and elongated palpebral fissures, thin upper lip and feet with long halluces with lateral deviation (Figure 1).

Five days after birth, she had a convulsive equivalent, which manifested as irritability, high-pitched cry and breathing pauses followed by tonic movements in the legs and arms. She was taken to the neonatal intensive care unit (NICU) and anticonvulsant therapy with phenobarbital was initiated.

An electroencephalogram showed a pattern of asymmetrical baseline activity, absence of normal physiological elements and presence of focal slow activity in the left temporal region. Other tests – echocardiogram, electrocardiogram and ultrasound of the brain, kidneys and urinary tract – showed no changes, except for a minor dilation of the lateral ventricles of the brain. Karyotyping found chromosome 5 deletion, which confirmed the diagnosis of CCS.

The patient had another convulsive equivalent 24 hours after the first episode and after five days of hospitalization in the NICU she was placed in rooming-in, where she did not develop other complications. She was discharged 19 days after birth, on exclusive breastfeeding, with a prescription for phenobarbital and with guidance for outpatient follow-up with the genetics, neurology and multidisciplinary teams.

The infant has not had seizures or required hospitalization since discharge. She has experienced difficulty sucking her mother's breast and has not gained enough weight. As a result, she was no longer kept on exclusive breastfeeding and a formula was introduced prior to six months of life. She is currently nine months old, weighs 6,495g (below Z score -2) is 69 cm long (between Z score -2 and -1) and has a head circumference of 37.5cm (below Z score -3).

Although she has been acquiring new skills from early stimulation offered since her first days of life, she presents with global developmental delay. She fixed her gaze and showed a social smile when she was three months old, started rolling over when she was five months, sat without support at the age of eight months, but cannot crawl yet. Solid foods were successfully introduced – good acceptance, no swallowing



Figure 1. Patient with Cri Du Chat syndrome: A. Soon after birth; B. In the first days of life; C. At 9 months old.

difficulties – when she was about six months old. Despite adequate food acceptance, she has had difficulty gaining weight and is undergoing nutritional monitoring.

DISCUSSION

Infants with cri du chat syndrome present several clinical anomalies, the most characteristic of which is a high-pitched cry that resembles a cat's cry, after which the syndrome was named[3]. This is probably caused by anomalies of the larynx (small, narrow, diamond-shaped) and epiglottis (flaccid, small, hypotonic), and tends to disappear with age. Although it is the most characteristic finding in patients with CCS, it is not considered a pathognomonic sign of the disease[4,5].

Children with CCS develop severe intellectual disability. Another common finding is microcephaly, which in our case is well demonstrated in the head circumference-for-age chart, in which microcephaly worsens with time (Figure 2). Children with CCS may also present heart defects, hypotonia, difficult-to-control seizures and dysmorphic facial features, such as a rounded and asymmetrical face, hypertelorism, downward slanting palpebral fissures, epicanthus, low-set ears, widened nasal bridge and micrognathia. These clinical manifestations vary based on the presence of different anomalies involving chromosome 5, thus producing different phenotypes[3,5].Low birth weight, difficulty sucking and keeping exclusive breastfeeding, and low weight gain are seen in a large proportion of children with the syndrome[6]. In the case presented, the infant did not have low birth weight and accepted her mother's breast in the first days after birth. With time, however, she developed sucking difficulties and was unable to gain enough weight, requiring dietary interventions.

The diagnosis of CCS is based on the typical clinical manifestations mentioned above. Karyotyping confirms the diagnosis when a partial deletion of the short arm or a parental translocation of chromosome 5p is found. In doubtful cases, FISH analysis (Fluorescent In-Situ Hybridization – mapping of a gene by molecular hybridization of a DNA sequence) can be ordered to confirm the diagnosis[1,2].

In cases suspected with CCS, pre-test genetic counseling is recommended to discuss the tests to be performed, the expected results and their limitations with the patient's family. In post-test genetic counseling sessions, the patient's family must be informed about the condition, provided with the clarification they need and offered support after diagnosis[7]. Counseling also includes discussions about reproductive options and the possibility of performing genetic tests in other family members. About 80% of the cases of CCS are due to new mutations, with a negligible risk of recurrence. However, G-banded karyotyping in peripheral blood must be ordered for parents of children with CCS, since risk of recurrence may be higher in the 10 % of the cases caused by a balanced chromosomal rearrangement in the genetic material of one of the parents, which may be an inversion (10% of cases) or a balanced translocation (90% of cases)[8]. Even in cases in which the parents do not wish to have other children, karyotyping should still be performed if they already have other children, since one of them may have inherited the balanced chromosomal alteration from one of the parents and will thus be at greater risk of having a child with CCS[5].

In complementary evaluation, complete cardiac evaluation with electrocardiograms and echocardiograms is essential to rule out cardiac malformations, which affect 15% to 20% of patients. Otoacoustic emission and red reflex tests must be performed in

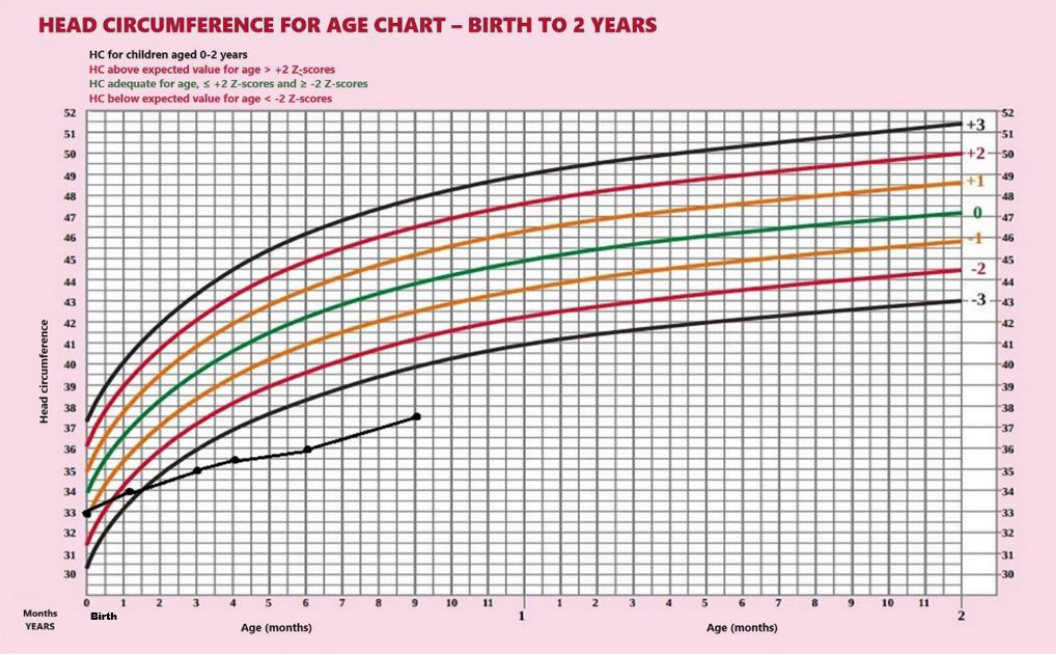

Figure 2. Head circumference chart for age from birth to 9 months of age.

all newborns. Transfontanellar ultrasound is also recommended, since it is an easily accessible, widely available, non-invasive test that allows the assessment of brain malformations. Neurology assessment must also be performed within the first weeks of birth or as soon as possible after diagnosis[7].

There is no specific therapy for patients with CCS, but early rehabilitation and educational interventions improve outcomes and lead to considerable progress in the social adjustment of patients[2]. The first year of life is a key time period for the future development of children. Patient stimulation and follow-up by a multidisciplinary team are recommended from the first days of life, so that potential developmental delays are identified as early as possible and interventions introduced to allow the best possible results[9].

Family involvement in educational and rehabilitation programs has been associated with better child psychomotor, linguistic and social development[10]. Considering the context imposed by the disease, the optimal development of the child described in this case report can be attributed to the involvement and stimulation provided by his family, who were guided and informed about the importance of stimulation, and the follow-up care provided by a multidisciplinary team from the first months of life, which further reinforces the importance of such interventions.

The dysmorphic signs of CCS must be recognized as early in neonatal life as possible, so that early diagnostic confirmation can be achieved along with the best possible outcomes.

The Research Ethics Committee approved this case report and granted it certificate no. 45392821.3.0000.5553. The patient's parents consented to the publication of this article and the images contained in it.

REFERENCES

1. Giersch ABS. Congenital cytogenetic abnormalities. UpToDate [Internet]. 2019 Sep; [cited 2021 Jul day]. Available from: https://www.uptodate.com/contents/congenital-cytogenetic-abnormalities.
2. Mainardi PC. Cri du Chat Syndrome. Orphanet J Rare Dis. 2006 Sep;1(1):33.
3. Schrijver I, Zehnder JL. Chromosomal translocations, deletions, and inversions. UpToDate [Internet]. 2021 May; [cited 2021 Jul day]. Available from: https://www.uptodate.com/contents/chromosomal-translocations-deletions-and-inversions#H2.
4. Niebuhr E. The cri du chat syndrome. Epidemiology, cytogenetics and clinical features. Hum Genet. 1978;44:227-75.
5. Ribeiro EM, Carneiro RCCP, Carneiro LJP, Matos EMSS, Albuquerque LS. A síndrome de Cri Du Chat em adolescentes. J Health Biol Sci. 2020 Jun;8(1):1-3.
6. Mainardi PC, Pastore G, Castronovo C, Godi M, Guala A, Tamiazzo S, et al. The natural history of Cri du Chat Syndrome. A report from the Italian Register. Eur J Med Genet. 2006 Sep;49(5):363-83.
7. Liverani ME, Spano A, Danesino C, Malacarne M, Cavani S, Sputon M, et al. Children and adults affected by Cridu Chat syndrome: Care's recommendations. Pediatric Reports. 2019 Feb;11(1):7839.
8. Honjo RS, Mello CB, Pimenta LSE, Nunes-Vaca EC, Beneditto LM, Khoury RBF, et al. Cri-du-Chat syndrome: characteristics of 73 Brazilian patients. J Intellect Disabil Res. 2018 Jun;62(6):467-73.
9. Nardi S. The cri du Chat syndrome; Technical aspects and educational guidelines. A.B.C. Associazione Bambini Cri du chat. [Internet]. 2014; [cited 2021 Jul day]. Available from: https://www.criduchat.it/documents/ABC-Criduchat-Technical-aspects-Educational-Guidelines-EN-web.pdf.
10. Cornish K, Oliver C, Standen P, Bramble D, Collins M. Cri-du-Chat Syndrome. Handbook for Parents and Professionals [Internet]. 2nd ed. The Cri Du Chat syndrome Support Group. 2003 May; [cited 2021 Jul day]. Available from: http://criduchat.org.uk/wp-content/uploads/2020/02/CDC-HANDBOOK-FOR-PARENTS-AND-PROFESSIONALS.pdf