Residência RP Pediátrica
Publicação Oficial da Sociedade Brasileira de Pediatria

Submitted on: 09/24/2022
Approved on: 07/10/2023

CASE REPORT

Acute appendicitis in an adolescent with situs inversus totalis: a case report

Júlia Buzzato Rainer[1], Carolina de Souza Fernandes Correa[1], Sarah Lira Garani[2], Cecília Pereira Silva[1,3], Camilla Kalil Laviola[3], Andréa Fabiane Lira[3]

Keywords:
Appendicitis,
Situs Inversus,
Diagnosis,
Adolescent.

Abstract

Appendicitis is the most common surgical emergency in pediatrics, being present in 1% to 8% of children with acute abdominal pain. The classical clinical presentation is characterized by the presence of acute migrating abdominal pain in the right iliac fossa. However, in patients with *situs inversus totalis*, the pain manifests in the left iliac fossa, which may delay the diagnosis and predispose to the development of complications. Thus, the aim of this study is to report a case of appendicitis in an adolescent with *situs inversus totalis*. **Methods:** This study is case report of appendicitis in an adolescent with *situs inversus totalis*. The research was submitted to the Ethics in Human Research Committee and approved under CAAE number 53591321.0.0000.5237. **Results:** The incidence of appendicitis in patients with *situs inversus totalis* is 0.016% to 0.024%. Due to the atypical clinical presentation in these patients, there is a tendency to delay the diagnosis of appendicitis, especially when the *situs inversus totalis* was not previously identified. Thus, there is a greater risk of developing severe complications such as intestinal perforation and sepsis, which considerably increases morbidity and mortality. **Conclusions:** We emphasize the importance of listing appendicitis as a possible diagnosis in patients with acute abdominal pain in the left iliac fossa because of the possibility of *situs inversus totalis*.

[1] Centro Universitário de Volta Redonda - Volta Redonda - Rio de Janeiro - Brasil.
[2] Universidade Nove de Julho, São Paulo - São Paulo - Brasil.
[3] Hospital Santa Cecília, Volta Redonda - Rio de Janeiro - Brasil.

Correspondence to:
Júlia Buzzato Rainer.
Centro Universitário de Volta Redonda. Av. Dauro Peixoto Aragão, 1325 - Três Poços, Volta Redonda, RJ, CEP: 27240-560. E-mail: juliaraiiner@gmail.com

Resid Pediatr. 2024;14(2). DOI: 10.25060/residpediatr-2024.v14n2-964

This work is licensed under a Creative Commons Attribution 4.0 International License.

INTRODUCTION

Appendicitis is the most common surgical emergency in children.[1,2] The risk of having appendicitis is 7% to 8% throughout life, and most cases occur during adolescence.[2] Classic signs and symptoms include acute migratory abdominal pain, which initially manifests in the periumbilical region and, after approximately 24 hours, shifts to the right iliac fossa. Other clinical signs include anorexia, fever, nausea and vomiting, peritoneal irritation, and right lower quadrant tenderness.[3]

Situs inversus totalis is an autosomal recessive disorder[4] defined by the abnormal arrangement of the thoracic and abdominal organs along the right and left axes.[5] This condition has a low prevalence and incidence and affects only 0.001% to 0.01% of the general population.[6] It is diagnosed in one in every 10,000 to 20,000 live births.[4] Most patients are asymptomatic. However, diagnosing cases of situs inversus totalis is essential for a better interpretation of the signs and symptoms of conditions that require surgery, such as appendicitis.[4]

The diagnosis of appendicitis may be delayed in patients with situs inversus totalis due to the atypical presentation of clinical signs and symptoms,[4,7] such as acute abdominal pain in the left iliac fossa. Delayed diagnosis increases the risk of severe and even lethal complications.[4]

Given the importance of early diagnosis, individuals with acute abdominal pain in the left iliac fossa must be suspected of appendicitis due to the possible existence of situs inversus totalis. This study describes a case of an adolescent with situs inversus totalis, initially undiagnosed with appendicitis, who was eventually treated in a pediatric emergency room.

CASE REPORT

A 12-year-old male was admitted to the pediatric emergency room with pain in the left iliac fossa and difficulty walking for the past 24 hours. No comorbid conditions were reported. On physical examination, he was in good general condition, hydrated, flushed, afebrile (axillary temperature: 36.7 °C), and eupneic on room air. His abdomen was flat and showed signs of peristalsis. He felt pain on superficial and deep palpation in the left iliac fossa, especially after decompression of the abdominal wall. No palpable masses or visceromegaly were apparent. Other systems were unchanged. Laboratory test results were as follows: complete blood count – erythrocytes: 4.37 x 106/µL, hemoglobin: 13.7 g/dL, hematocrit: 39%; leukocytes: 20,200/µL, rods: 7%, segmented: 74%, monocytes: 4%; platelets: 272,000/µL; C-reactive protein – 55 mg/dL; urine sediment examination – without changes. Chest and abdominal X-ray images showed the patient had situs inversus totalis. Abdominal computed tomography scans revealed an enlarged appendix in the left iliac fossa, confirming the diagnosis of appendicitis (Figures 1, 2, 3, and 4). The patient was prescribed an appendectomy.



Figure 1. Axial view of the thoracic plane, showing situs inversus with dextrocardia.



Figure 2. A coronal scan showing situs inversus totalis.

DISCUSSION

Appendicitis is the most common reason for emergency abdominal surgery in children. The condition is diagnosed in 1% to 8% of children with acute abdominal pain.[8,9] The reported combined incidence of appendicitis and situs inversus totalis ranges between 0.016% and 0.024%.[10]



Figure 3. An axial view scan showing a thickened enlarged appendix (red arrow) in the left iliac fossa.

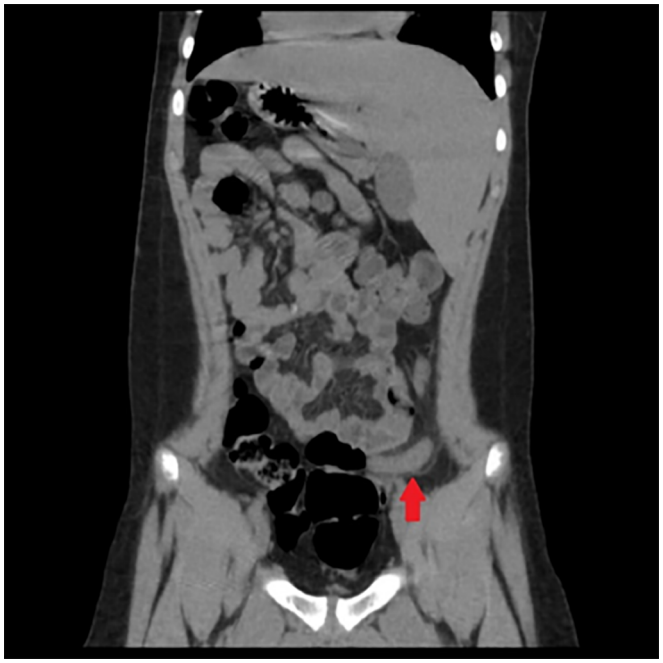

Figure 4. A coronal view scan showing a thickened enlarged appendix (red arrow) in the left iliac fossa.

Appendicitis is diagnosed based on clinical history and workup. The preferred diagnostic imaging methods are abdominal ultrasound, computed tomography, and magnetic resonance imaging. Plain radiographs are generally not helpful in establishing a diagnosis of appendicitis. However, they help detect situs inversus totalis and add considerable diagnostic value.[2,7]

Although laboratory tests are not sufficiently sensitive or specific for acute appendicitis, they may help diagnose individuals with the condition. A normal leukocyte count has a substantial negative predictive value; an increase in immature forms of neutrophils also has a strong association with appendicitis; and a high C-reactive protein level predicts complicated or perforated appendicitis.[2,7]

The signs and symptoms of appendicitis in patients with situs inversus totalis differ from the classically described manifestations of the disease.[11] Acute abdominal pain migrates from the periumbilical region to the left iliac fossa and not to the right iliac fossa,[4] which may delay diagnosis.[12]

Delayed diagnosis also derives from the fact that most patients with situs inversus totalis, as the patient described in this case report, are unaware that they have the anomaly, [12] since it is generally asymptomatic. [4] Therefore, individuals with situs inversus totalis have a greater chance of developing severe and lethal complications, including perforation of the appendix resulting in sepsis and septic shock.[4,7]

Despite their severity and lethality, these complications can be prevented via early identification and treatment. [11] Appendicitis must be included in the differential diagnosis of acute abdominal pain in the left iliac fossa [7] so that individuals with undiagnosed situs inversus totalis are not missed.[12]

CONCLUSION

Since appendicitis is the most common indication for emergency pediatric surgery, children and adolescents with acute abdominal pain must be examined for the condition. Furthermore, considering the possible complications arising from delayed diagnosis, appendicitis must be included in the differential diagnosis of individuals with atypical manifestations such as the ones seen in cases of situs inversus totalis.

REFERENCES

1. Becker C, Kharbanda A. Acute appendicitis in pediatric patients: an evidence-based review. Pediatr Emerg Med Pract[Internet]. 2019 Sep[citado em 18 set 2022];16(9):1-20. Epub 2019 Sep 2. PMID: 31461613. Disponível em: https://pubmed.ncbi.nlm.nih.gov/31461613/..
2. Rentea RM, St Peter SD. Pediatric Appendicitis. Surg Clin North Am[Internet]. 2017 Feb[citado em 18 set 2022];97(1):93-112. doi: 10.1016/j.suc.2016.08.009. PMID: 27894435. Disponível em: https://pubmed.ncbi.nlm.nih.gov/27894435/.
3. Bundy DG, Byerley JS, Liles EA, Perrin EM, Katznelson J, Rice HE. Does this child have appendicitis? JAMA[Internet]. 2007 Jul 25[citado em 18 set 2022];298(4):438-51. doi: 10.1001/jama.298.4.438. PMID: 17652298; PMCID: PMC2703737. Disponível em: https://pubmed.ncbi.nlm.nih.gov/17652298/.
4. Koç A, Sönmez Y, Balaban O. Anaesthetic Management for Appendectomy in a Patient with Situs Inversus Totalis. Turk J Anaesthesiol Reanim[Internet]. 2016 Apr[citado 17 set 2022];44(2):105-7. doi: 10.5152/TJAR.2016.33716. Epub 2016 Apr 1. PMID: 27366569; PMCID: PMC4894195. Disponível em: https://pubmed.ncbi.nlm.nih.gov/27366569/.

5. Van Praagh R, Van Praagh S. Atrial isomerism in the heterotaxy syndromes with asplenia, or polysplenia, or normally formed spleen: an erroneous concept. Am J Cardiol[Internet]. 1990 Dec 15[citado em 18 set 2022];66(20):1504-6. doi: 10.1016/0002-9149(90)90543-a. PMID: 2252000. Disponível em: https://pubmed.ncbi.nlm.nih.gov/2252000/.

6. Golash V. Laparoscopic management of acute appendicitis in situs inversus. J Minim Access Surg[Internet]. 2006 Dec[citado em 18 set 2022];2(4):220-1. doi: 10.4103/0972-9941.28184. PMID: 21234150; PMCID: PMC3016484. Disponível em: https://pubmed.ncbi.nlm.nih.gov/21234150/.

7. Akbulut S, Ulku A, Senol A, Tas M, Yagmur Y. Left-sided appendicitis: review of 95 published cases and a case report. World J Gastroenterol[Internet]. 2010 Nov 28[citado em 16 set 2022];16(44):5598-602. doi: 10.3748/wjg.v16.i44.5598. PMID: 21105193; PMCID: PMC2992678. Disponível em: https://pubmed.ncbi.nlm.nih.gov/21105193/.

8. Scholer SJ, Pituch K, Orr DP, Dittus RS. Clinical outcomes of children with acute abdominal pain. Pediatrics[Internet]. 1996 Oct[citado em 18 set 2022];98(4 Pt 1):680-5. PMID: 8885946. Disponível em: https://pubmed.ncbi.nlm.nih.gov/8885946/.

9. Reynolds SL, Jaffe DM. Diagnosing abdominal pain in a pediatric emergency department. Pediatr Emerg Care[Internet]. 1992 Jun[citado em 17 set 2022];8(3):126-8. doi: 10.1097/00006565-199206000-00003. PMID: 1614900. Disponível em: https://pubmed.ncbi.nlm.nih.gov/1614900/.

10. Huang SM, Yao CC, Tsai TP, Hsu GW. Acute appendicitis in situs inversus totalis. J Am Coll Surg[Internet]. 2008 Dec[citado em 19 set 2022];207(6):954. doi: 10.1016/j.jamcollsurg.2008.03.030. Epub 2008 May 19. PMID: 19183546. Disponível em: https://pubmed.ncbi.nlm.nih.gov/19183546/.

11. Pipal DK, Pipal VR, Yadav S. Acute Appendicitis in Situs Inversus Totalis: A Case Report. Cureus[Internet]. 2022 Mar 8[citado em 19 set 2022];14(3):e22947. doi: 10.7759/cureus.22947. PMID: 35411282; PMCID: PMC8988252. Disponível em: https://pubmed.ncbi.nlm.nih.gov/35411282/.

12. Otsuka Y, Hayashi R, Urano S, Yashima A, Nanba Y, Otsuka F. Left-sided appendicitis due to situs inversus totalis. Clin Case Rep[Internet]. 2021 Feb 4[citado em 18 set 2022];9(3):1791-1792. doi: 10.1002/ccr3.3734. PMID: 33768941; PMCID: PMC7981778. Disponível em: https://pubmed.ncbi.nlm.nih.gov/33768941/.