Residência RP Pediátrica
Publicação Oficial da Sociedade Brasileira de Pediatria

Submitted on: 02/05/2023
Approved on: 04/14/2023

CASE REPORT

Case report: klippel-trenaunay syndrome

Nathalya Gonçalves dos Santos[1], Adriana Prazeres da Silva[1], Vitor Hugo L. de O. Rodrigues[1], Jacqueline Trujillo Vargas[1], Emelie Otilia Fischer[1]

Keywords:
Hemangioma,
Syndrome,
Vascular malformations.

Abstract

Introduction: Klippel-Trenaunay syndrome (KTS) is a rare congenital disease, characterized by the triad: capillary malformations that manifest as port wine stain, typically venous varicosities, bone and soft tissue hypertrophy. **Case report:** LFRR, term newborn weighing 3360g, male, cesarean delivery due to imminent eclampsia (G3P2C0). Apgar score 9/9 with physical examination showing left lower limb with port wine stain, increased volume and diffuse violaceous lesions extending from the toes to the buttocks, palpable and symmetrical peripheral pulses. **Discussion:** KTS management does not have a well-established consensus, and conservative treatment can be performed using non-invasive measures (elastic or non-elastic compressive stockings) associated or not with psychological support, elevation of the affected limb and physiotherapy. Active conducts such as sclerotherapy can be used in small areas, as well as the use of laser therapy on port wine stains and ulcerations. Sirolimus may be a promising therapeutic option for the management of venous malformations, including KTS, leading to an improvement in symptoms such as pain and a decrease in the size of the lesions. **Conclusion:** KTS, as a rare syndrome, has scarce literature. The main management is based on the use of conservative therapies, others related to the complications presented and now begins the phase of using off-label drugs (Sirolimus) that slow down the progression of the disease.

[1] Hospital Regional do Mato Grosso do Sul, Pediatria - Campo Grande - Mato Grosso do Sul - Brazil.

Correspondence to:
Nathalya Gonçalves dos Santos.
Hospital Regional de Mato Grosso do Sul. Av. Engenheiro Lutero Lopes, 36, Aero Rancho, Campo Grande, MS, Brazil. CEP 79084-180. E-mail: natalia.ufmt@gmail.com

Resid Pediatr. 2024;14(2). DOI: 10.25060/residpediatr-2024.v14n2-1039

This work is licensed under a Creative Commons Attribution 4.0 International License.

INTRODUÇÃO

Klippel-Trenaunay syndrome (KTS) is a rare congenital disease affecting approximately 2-5 people per 100,000 population. The syndrome is characterized by a triad of findings comprising capillary malformations manifesting as port-wine stains, various veins, and bone and soft tissue hypertrophy [1].

Diagnosis is based on clinical evaluation and the observation of two of the three signs mentioned above [2]. The condition affects males and females equally, and clinical signs and symptoms include pain, lymphedema, superficial thrombophlebitis, venous thrombosis, ulcerations, bleeding, pulmonary embolism, stasis dermatitis, decalcification of involved bones, poor wound healing, spina bifida, among others [3].

KTS mainly affects the legs (80 to 85% of cases), with bilateral involvement occurring in only 12.5%. Other limbs are affected in less than 1% of cases. Bone and soft tissue hypertrophy become evident in the first years of life and progress until approximately 12 years of age [4].

It has been hypothesized that the condition's vascular signs and symptoms stem from widespread changes in the mesoderm that occur during embryonic development caused by a somatic mutation in primitive cells in the PIK3CA gene. This mutation would cause a delay in the regression of the vascular reticulum in the affected area in the embryo, leading to greater exposure to growth factors, thereby causing hypertrophy and hyperplasia of the veins and increased bone growth [5].

CASE REPORT

LFRR, a male full-term newborn weighing 3360g, was born from a cesarean section due to imminent eclampsia (G3P2C1). His 1-minute and 5-minute Apgar scores were 9. Physical examination revealed a left leg with a port-wine stain, increased volume, diffuse violet lesions extending from the toes to the glutes (Figure 1), and palpable and symmetrical peripheral pulses. No other changes were noted.

The newborn was admitted to the neonatal intensive care for suspicion of Klippel-Trenaunay or Parkes-Weber syndrome. A vascular surgeon and a pediatric dermatologist examined the patient and prescribed a moisturizing cream (Dersani ®) for the leg and protection against local trauma.

Lab workup results were as expected. An echocardiogram indicated a patent foramen ovale of approximately 3.5 mm with flow from left to right. Transfontanellar ultrasound and complete ultrasound of the abdomen were also routine.

Ultrasound examination performed at 24 weeks and six days of pregnancy showed anechoic formations clustered in soft tissues (supra-aponeurotic planes), preserving muscle and bone and extending from the posterior sacrococcygeal and anterior pelvic region to the left leg. The formations



Figure 1. Hypertrophy of the left leg with varicose veins in a patient with Klippel-Trenaunay Syndrome.

affected the thigh up to the proximal portion of the mid-leg, with slight deformity and flexion of the left knee. The report cited a superficial multicystic malformation in the pelvic, sacrococcygeal, and left leg regions, consistent with multicystic lymphangioma.

The patient was discharged nine days after birth on a prescription of oral vitamin A+D and topical moisturizing cream. He was taken back for a consultation with the pediatric dermatologist 50 days after birth. He presented a port-wine stain on the left leg and an extensive tumor affecting the buttocks and thigh (Figure 2). His left leg was hypertrophic, his foot was swollen, and lymphatic vessels proliferated over the port wine stain, at which time the patient was diagnosed with KTS.

The vascular surgeon prescribed diosmin hesperidin and elastic bandages. Magnetic resonance angiography was recommended, but the parents rejected the idea for fear of sedation.

During follow-up, the infant had episodes of bleeding in the left leg, generally after local trauma, and underwent six blood transfusions until the age of one year and 11 months. He was also hospitalized several times to have intravenous antibiotics administered and a deep ulcer treated (Figure 3).



Figure 2. Hypertrophy of the left leg with a port-wine stain and lymphatic proliferation.



Figure 3. Deep ulcer with signs of infection on the left leg.

The patient's severe condition prompted the pediatric dermatologist to inform the parents of the off-label use of oral Sirolimus with good results [6]. The parents agreed, and the health authority of the State of Mato Grosso do Sul was requested to release the medication for use.

The patient was started on sirolimus 1 mg (rapamune ®) on March 27, 2021. He was given half a dose every 12 hours orally with good acceptance. Lymphatic proliferation in the toes of the left foot was reduced after just over two months of treatment (Figures 4 and 5).

Magnetic resonance angiography of the pelvis and legs performed when the patient was two years and nine months old revealed large varicose veins in the abdominal and pelvic cavity, along the muscles of the pelvis on the left and throughout the left leg; lymphedema in the left hemi-abdomen, pelvis, left leg, testicular pouch; and lymphangioma in the left abdominal cavity (Figure 6).

DISCUSSION

There has yet to be a consensus over the management of KTS. Conservative treatment can be delivered via non-invasive measures (elastic or non-elastic compressive stockings) associated with psychological support, elevation of the affected limb, and physiotherapy [7].

Analgesics, antibiotics, and corticosteroids have been associated with complications such as cellulitis and thrombophlebitis [8]. Anticoagulants may be indicated prophylactically before surgery and in cases of acute thrombosis [9].

Sclerotherapy can be used in small areas. Surgery is reserved for symptomatic cases. Reports in the literature have described clinical deterioration after band ligation and stripping. Laser therapy has also been used to treat port-wine stains and ulcerations [10].

When surgery is needed for patients with symptoms, minimally invasive approaches are recommended due to the risk of intense bleeding [11]. Preoperative planning is required and must consider intraoperative blood loss and the high risk of venous thrombosis and pulmonary thromboembolism [12].

Research on the mutant gene and its signaling pathway and mTOR inhibitor sirolimus, prescribed to suppress cell proliferation and mitigate disease progression, have shown promising results [13].

Studies demonstrate that sirolimus can be prescribed to manage venous malformations, including KTS, improving pain and reducing lesion size [14]. The drug also impacts hemostasis with decreased serum D-dimer levels after treatment [15].

CONCLUSION

Since it is a rare condition, little has been written about KTS. Management is based on conservative therapies and the treatment of complications. Off-label medications (sirolimus) have slowed disease progression. The main focus is to improve the patient's quality of life by treating complications and decreasing the need for hospitalization.

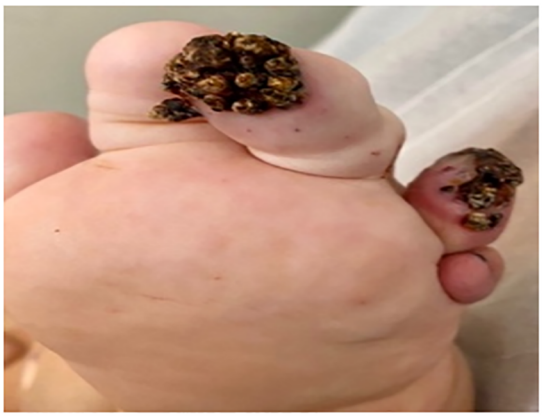



Figure 4 and 5. Lymphatic proliferation in left toes before and after the start of treatment, showing regression of the lesions.



Figure 6. Lymphedema in the left hemi-abdomen, pelvis, left leg, and testicular pouch.

Our patient experienced a considerable reduction in lymphatic proliferation after a few months of treatment with sirolimus and a decrease in bleeding episodes and infection.

REFERENCES

1. Leon CDAD, Braun Filho LR, Ferrari MD, Guidolin BL, Maffessoni BJ. Síndrome de Klippel-Trenaunay: relato de caso. An Bras Dermatol. 2010;85(1):93-6.
2. Afonso AR, Cunali VCA, Chagas VCA, Nabuco PVO, Barsam FJBG, Félix EMF. Resid Pediatr. 2016;6(2):91-3 DOI: https://doi.org/10.25060/residpediatr-2016.v6n2-10.
3. Cebeci E, Demir S, Gursu M, Summu A, Yamak M, Doner B, et al. A case of newly diagnosed Klippel Trenaunay Weber Syndrome presenting with nephrotic syndrome. Case Rep Nephrol. 2015;2015:704379. DOI: https://doi.org/10.1155/2015/704379.
4. Villela ALC, Guedes LGS, Paschoa VVA, David AB, Tenório TM, Lamego Junior HP, et al. Perfil epidemiológico de 58 portadores de síndrome de Klippel-Trénaunay-Weber acompanhados no Ambulatório da Santa Casa de São Paulo. J Vasc Bras. Set 2009;8(3):219-24. DOI: https://doi.org/10.1590/S1677-54492009000300006.
5. Harna B, Tomar S. Klippel Trenaunay Syndrome. Indian J Pediatr. 2020;87(11):966-7.
6. Freixo C, Ferreira V, Martins J, Almeida R, Caldeira D, Rosa M, et al. Efficacy and safety of sirolimus in the treatment of vascular anomalies: a systematic review. J Vasc Surg. 2020;71(1):318-27.
7. Bessis D, Vernhet H, Bigorre M, Quéré I, Rossler J. Life-threatening cutaneous bleeding in childhood Klippel-Trenaunay syndrome treated with oral sirolimus. JAMA Dermatol. 2016 Sep 1;152(9):1058-9.
8. Sung HM, Chung HY, Lee SJ, Lee JM, Huh S, Lee JW, et al. Clinical experience of the Klippel-Trenaunay syndrome. Arch Plast Surg. 2015 Sep;42(5):552-8.
9. Shirazi F, Cohen C, Fried L, Arbiser JL. Mammalian target of rapamycin (mTOR) is activated in cutaneous vascular malformations in vivo. Lymphat Res Biol. 2007;5(4):233-6. DOI: https://doi.org/10.1089/lrb.2007.1012.
10. Asghar F, Aqeel R, Farooque U, Haq A, Taimur M. Presentation and Management of Klippel-Trenaunay Syndrome: A Review of Available Data. Cureus. 2020 May 8;12(5):e8023. DOI: https://doi.org/10.7759/cureus.8023.
11. Flumignan RLG, Cacione DG, Lopes SI, Clezar CNB, Queiroz CD, Pereira-Filho ARD, et al. Síndrome de Klippel-Trenaunay-Weber: associação do tratamento operatório à escleroterapia por espuma. J Vasc Bras. 2011;10(1):77-80.
12. Lee JH, Chung HU, Lee MS. An anesthetic management of a patient with Klippel-Trenaunay syndrome. Korean J Anesthesiol. 2012 Jul;63(1):90-1.
13. Zea MI, Hanif M, Habib M, Ansari A. Klippel-Trenaunay Syndrome: a case report with brief review of literature. J Dermatol Case Rep. 2009 Dec 30;3(4):56-9.
14. Hammer J, Seront E, Duez S, Dupont S, Van Damme A, Schmitz S, et al. Sirolimus is efficacious in treatment for extensive and/or complex slow-flow vascular malformations: a monocentric prospective phase II study. Orphanet J Rare Dis. 2018 Oct 29;13(1):191. DOI: https://doi.org/10.1186/s13023-018-0934-z.
15. Abdelbaky MA, Ragab IA, AbouZeid AA, Mohammad SA, Dahab MM, Elsherbeny M, et al. Sirolimus: A rescue drug to control complications of extensive venous malformation. European J Pediatr Surg Rep. 2020 Jan;8(1):e90-4.