Residência RP Pediátrica
Publicação Oficial da Sociedade Brasileira de Pediatria

Submitted on: 02/11/2023
Approved on: 07/10/2023

CASE REPORT

Atypical clinical manifestation of tropical pyomyositis

Camylla Santos de Souza[1], Juliana Porto Moura Negreiros[1], Laura Belizante Pontes Pereira[1], Natasha Simões Montenegro Mello[1], Graciela Josué de Oliveira Laurênio[1], Glaucia Maria Lima Ferreira[1]

Keywords:
Pyomyositis, Appendicitis, Infectious disease medicine, Pediatrics.

Abstract

Tropical pyomyositis is a muscle infection whose manifestations may initially be mild and nonspecific, making diagnosis difficult; however, in most cases, it evolves with a benign prognosis. Because it is an uncommon condition, it is necessary to discuss a case of tropical pyomyositis with rare complications after trauma. The patient in question was in a period of convalescence from dengue fever when he suffered trauma, evolving with an abscess in the left thigh, surgically drained, and using cephalexin. Before completing seven days of antibiotics, he returned to the emergency medical care due to worsening of the clinical picture. When he was admitted, a new drainage was performed and ceftriaxone and oxacillin were started. With no satisfactory response to the antibiotics after three days, it was escalated to ceftaroline. On the eighth day of treatment, he had a worsening of the infectious condition, associated with a CT finding of a large median retrovesical collection. It was decided to prescribe meropenem and linezolid and to perform videolaparoscopic drainage, however, five days after the procedure, the patient evolved with a positive Blumberg sign on physical examination, with confirmation of a significant retrovesical collection on abdominal ultrasound. An exploratory laparotomy was then performed with drainage of the collection and, due to the visualization of intraoperative appendicitis, an appendectomy was performed. Afterwards, the patient evolved with progressive clinical improvement, finishing meropenem and linezolid by the 21st day and being discharged with guidance for outpatient follow-up.

[1] Hospital Unimed Sul / Hospital Regional da Unimed, Pediatria - Fortaleza - Ceará - Brasil.

Correspondence to:
Camylla Santos de Souza.
Hospital Unimed. Av. Almirante Maximiniano da Fonseca, 44 - Luciano Cavalcante, Fortaleza, CE, Brazil. CEP: 60811-020. E-mail: camylladesouza@outlook.com

Resid Pediatr. 2024;14(2).
DOI: 10.25060/residpediatr-2024.v14n2-1042

This work is licensed under a Creative Commons Attribution 4.0 International License.

INTRODUCTION

Pyomyositis is a rare muscle infection caused by especially oxacillin-sensitive Staphylococcus aureus (OXA-S) by contiguity or hematogenous dissemination. It can lead to the formation of abscesses and progressive muscle necrosis, which can result in serious systemic complications and death[1].

The name tropical pyomyositis is due to the fact that the disease is more common in tropical regions, but there is an increase in cases in temperate regions[2]. It occurs in two age groups: children (2 to 5 years old) and adults (20 to 45 years old). Young, healthy men are more affected than women, in a ratio of 5:2[3].

Any muscle can be involved, but the most common sites are the thigh, gluteal and trunk muscles, in addition to the abdominal, forearm, iliac and psoas muscles[3].

Some predisposing factors are known, such as trauma, immunodeficiency, corticosteroid therapy, diabetes mellitus, infection, ischemia and malnutrition. In 20-50% of cases there is a history of trauma or vigorous exercise in the area involved. This condition is also related to electric shocks and injectable drug use[2-4].

Symptoms depend on the stage of the disease and can range from a low fever to septicemia[3]. Mortality is around 1 to 10%. There are reports of serious complications, such as: osteomyelitis, pneumopathies, pyoarthritis, deep vein thrombosis, sepsis, compartment syndrome, renal failure and local recurrences[3,4].

The disease is classified into three stages: stage I (invasive) with non-specific manifestations, such as low fever, local pain and stiffness, edema and paresthesia. Stage II (suppurative) with increased edema and fever. In stage III (late), systemic involvement occurs with signs of sepsis, with the possibility of death[2].

Diagnosis can be carried out using ultrasound, magnetic resonance imaging and computed tomography. Cultures and laboratory tests such as muscle enzymes are also important. Differential diagnoses include osteomyelitis, septic arthritis and hematomas[2,3].

All stages of tropical pyomyositis require antibiotic therapy, with surgical drainage being necessary in cases with abscess. The use of beta-lactamase resistant penicillin such as oxacillin or first to third generation cephalosporins is recommended. In case of sepsis, an aminoglycoside can be associated[2].

Given the magnitude and possible complications that can occur, and the fact that it is underdiagnosed, in-depth knowledge of this entity is essential so that timely care can be provided. Therefore, the present case report aims to describe the clinical characteristics and atypical evolution of an unusual disease, tropical pyomyositis, in a child admitted to a general pediatrics service in Fortaleza, with a history of viral illness during convalescence and blunt trauma. Furthermore, more specifically, the objective is to: 1) verify the progression of tropical pyomyositis and its most common outcomes, evaluating the possibility of rare complications; 2) evaluate possible causes and predisposing factors associated with tropical pyomyositis; 3) seek to estimate the effectiveness of the drug and surgical treatment adopted and analyze the evolution of the disease, as well as evaluate tests performed; 4) alert health professionals about the importance of diagnosing a rare disease, more common in the tropics, as well as its stages and possible complications.

CASE REPORT

J.P.D.A., 14 years old, male, with easy suspicion of acromegaly, who, during a period of convalescence from dengue fever (IgG and IgM positive on 05/16), suffered blunt trauma in a bullying attack at school and developed an abscess on the left thigh (Figure 1), surgically drained on 05/24/2022, with outpatient prescription of cephalexin. On 06/30, he returned to the emergency room with worsening edema in the left thigh, edema in the right buttock and fever.

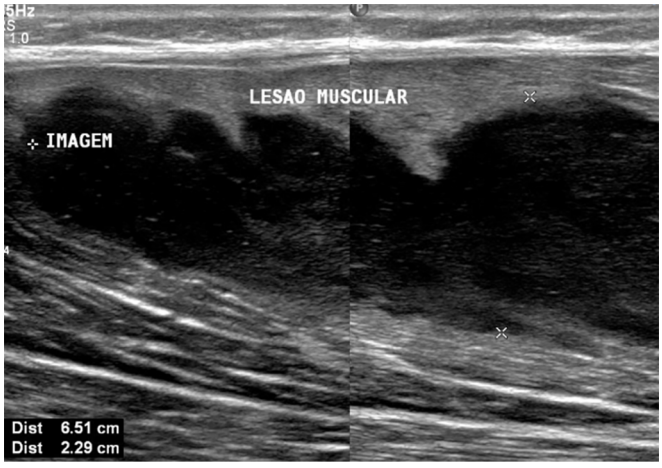

Figure 1. Soft tissue US (05/23/2022): Extensive heterogeneous collection with hyperechoic beams compromising the region of the vastus lateralis muscles on the left. Measuring approximately 7.6 x 3.3cm, characterizing a significant muscle injury (grade III).

After imaging tests, tropical pyomyositis was diagnosed and hospital admission was carried out for new drainage on 05/31/2022, with the start of ceftriaxone and oxacillin. Three days later, with no satisfactory response and an episode of fever, antibiotic therapy was switched to ceftaroline. After eight days, he developed discomfort, adynamia and difficulty moving his left knee. An echocardiogram was performed on 06/10/2022, with a finding of laminar pericardial effusion, and a computed tomography of the abdomen (Figure 2) and abdominal ultrasound, which showed a median, retrovesical pelvic collection, measuring approximately 680ml. We prescribed meropenem and linezolid; however, the patient developed abdominal pain that was refractory to symptoms. In



Figure 2. Abdominal CT with contrast (06/13/2022): Liquefied collection, suggestive of an abscess, within the muscles of the buttock on the right, Median pelvic collection, retrovesical, measuring 13.8 x 9.8x9.8cm, in volume estimated 680ml.

consultation with pediatric surgery, we did a videolaparoscopic drainage of the retrovesical collection on 06/18/2022.

After the approach, the patient still had pain complaints in the abdomen, associated with vomiting, hyporexia, peritonism and, on 06/23/2022, Blumberg was positive on physical examination. We also found an important retrovesical collection on abdominal USG. An exploratory laparotomy with collection drainage was then performed, we found an appendicitis intraoperatively and performed an appendectomy.

After the procedure, he progressed with clinical improvement, afebrile, clinically and hemodynamically stable, finishing meropenem and linezolid until the 21st day. Control ECOTT (06/27/2022) showed no changes. After discharge from the hospital, he was referred for outpatient follow-up with a pediatric surgeon and infectious disease specialist, with no reports of further complications.

DISCUSSION

In the aforementioned case, the patient, in addition to being outside the usual age range described in the literature, had two predisposing risk factors for the manifestation of pyomyositis. The first of these occurred in the form of a concomitant viral infection, dengue, which, in itself, could already be responsible for an increase in vascular permeability and plasma extravasation, with consequent hypovolemic shock and/or significant hemorrhage[5]. The second risk factor was the occurrence of a blunt trauma during the period of convalescence from dengue, serving as a facilitating factor for the implantation of an associated local bacterial infection[6,7].

In the literature, the average diagnosis time for tropical pyomyositis is 14 days, since its symptoms can be non-specific and confused with other conditions, such as septic arthritis[5,7,8]; Meanwhile, in the case studied, it was possible to identify the condition in just over 1 week (8 days in total), considering the date of diagnosis of dengue infection until the first treatment, carried out with drainage of the left lower limb abscess. Furthermore, the region affected in the patient in question is compatible with what has been described in other reports, that, in the pediatric population, the three most frequent locations are the quadriceps femoris, the gluteal muscles and the iliopsoas[8].

When there are no characteristic clinical findings, imaging exams are recommended. In most cases, such as the one mentioned above, performing an ultrasound with a specialized operator may be sufficient to determine the extent of the injury and the need for drainage; however, in more atypical locations, such as the spine, examinations may be necessary, although bearing higher costs and not always being easily accessible through the public healthcare system, such as an MRI[2,7,8].

Not all cases of pyomyositis require a surgical approach, but the use of antibiotic therapy is mandatory, preferably beta-lactamase resistant penicillins - such as oxacillin - and/or first to third generation cephalosporins, as was the case in the patient studied, aiming at coverage of the two main microorganisms involved: group A[2,6] beta-hemolytic Streptococcus and Staphylococcus aureus. The case in question could have been a case of community-acquired methicillin-resistant S. aureus (CA-MRSA), as has already been described in the United States[2,7], since, even with the use of cephalexin at home and the combination of ceftriaxone and oxacillin when hospitalized, there was still a need to expand the spectrum of coverage to ceftaroline and, after further worsening, to meropenem and linezolid. Other agents can also be identified, especially in immunocompromised individuals, with emphasis on Streptococcus pneumoniae, Escherichia coli, Neisseria gonorrhoea, Candida albicans, Fusobacterium nucleatum, Mycobacterium tuberculosis and M. avium complex, for example. In Brazil, a case of pyomyositis related to toxocariasis has already been described[2,6-8]. In the case studied, however, the cultures collected remained negative.

Furthermore, it can be considered that the aforementioned patient's pyomyositis reached grade III, since, in addition to systemic symptoms indicative of sepsis, the abscess extended to the abdominal cavity, also progressing with appendicitis. No cases were found in the literature that linked the occurrence of appendicitis with pyomyositis. It is questioned to what extent there was a coincidence in the two conditions occurring concomitantly, or whether the appendix was affected by bacterial translocation of an underlying abscess.

Therefore, the child in this case had predisposing factors for presenting tropical pyomyositis, confirmed by clinical, laboratory and imaging diagnoses. It progressed with disease progression (stage 3) and more serious complications than those described in the literature, such as pericardial effusion and abscess/intracavitary collection in the abdomen, in addition to presenting rare complications, not yet described, such as appendicitis, raising questions whether the concomitance would be a coincidence or a new associated complication. Early diagnosis of tropical pyomyositis is of fundamental importance for the success of treatment, be it medication or surgery, if necessary, and antibiotic therapy should be started early to control its complications.

REFERENCES

1. Pereira GH. Piomiosite Tropical Relacionada a Covid19. Braz J Infect Dis. 2022 Jan;26(Suppl 1):102055.
2. i Graells XS, Benato ML, Del Santoro PG, Kulcheski AL, Sebben AL, Morais GS. Piomiosite Tropical Invadindo Canal Medular. Rev Méd da UFPR. 2017;4(3):147-50.
3. Marques JEN, Silva MMDM, Amaral WN. Piomiosite Tropical - Relato De Caso. Rev Bras Ultra. 2014 Mar;16:71-3.
4. Costa FQ, Rosário MS. Piomiosite Tropical - Relato De Caso. Rev Cient Hosp Santa Izabel. 2022 Aug 30;6(2):86-9.
5. Garcia E. Relato de Caso: Miositis Causada por Virus da Dengue. Resid Pediatr. 2015 Apr;5(1):36-9. DOI: https://doi.org/10.25060/residpediatr-2015.v5n1-09.
6. Talavera MB, Wakai M, Campos LMA, Baldacci ER, Silva CAA. Piomiosite Bacteriana Aguda (Pba) Em Crianças Eutróficas. Rev Bras Reumatol. 2003 Aug;43(4):259-64.
7. Pone MVS, Moura T. Piomiosite Bacteriana. Rev Pediatr SOPERJ. 2009;10(2):20-1.
8. Bahute A, Alves C, Balacó I, Cardoso PS, Ling TP, Matos G. Piomiosite Pélvica Em Idade Pediátrica: Uma Série De Casos Clínicos. Rev Port Ortop Traum. 2015 Dez;23(4):310-9.