Residência RP Pediátrica
Publicação Oficial da Sociedade Brasileira de Pediatria
ISSN-Online: 2236-6814

Submitted on: 06/07/2021
Approved on: 06/05/2024

CASE REPORT

Garrè's osteomyelitis in Pediatrics: report of a rare case

Aldo Roberto Ferrini Filho[1], Ana Laura Stahlhoefe[1], Camila Pereira Rosa Lara[1], Isabella Juliana Manfredo Rodrigues[1], Jose de Mendonça Costa Neto[2], Bruno Vaz da Costa[1], Flavia de Assis Silva[1]

Keywords:
Osteomyelitis, Mandible, Pediatrics.

Abstract

Introduction: Garrè's osteomyelitis (GO) is a rare inflammatory chronic disease, characterized by a periosteal reaction with bone neoformation secondary to bacterial infections of odontogenic origin. The mandible is the most affected bone structure. Most prevalent in the first and second decades of life, a little more prevalent in males. **Objective**: To describe a clinical case in a pediatric patient with GO, showing diagnostic keys for the pediatrician and its clinical evolution. **Case report:** A 12-year-old male patient, previously healthy, started with pain in the lower dental arch, associated with an extensive carious lesion in the lower right first molar, progressing with the appearance of a tumor in the homolateral mandibular topography, it was painless and hardened. A computed tomography was performed on the face, which showed periapical lytic involvement along the lower right first and second premolars, and the adjacent external cortical bone, associated with periosteal reaction. Having raised the hypothesis of GO, the extraction of the affected tooth was realized with bone tissue biopsy, the histological study showed the presence of fibrous tissue, dilated blood vessels and intertrabecular inflammatory infiltrate. Antibiotic therapy with intravenous clindamycin for seven days. It evolved with progressive regression of the lesion, being maintained orally therapy for six weeks, suspended after complete regression. **Conclusion:** This case reinforces the importance of this condition for pediatricians. It should always be suspected when there is a dental disease. The evolution tends to be favorable, when appropriate treatment is instituted, removing the infectious focus and prescribing adjuvant antibiotic therapy.

[1] Hospital Materno Infantil de Brasília, Pediatria - Brasília - Distrito Federal - Brazil.
[2] Faculdade Ceres, Patologia - São José do Rio Preto - São Paulo - Brazil.

Correspondence to:
Aldo Roberto Ferrini-Filho.
Hospital Materno Infantil de Brasília, Pediatria - Brasília - Distrito Federal - Brazil. L2 SUL Quadra 608 Módulo A, Asa Sul, Brasília, DF, Brazil. CEP: 70.203-900. E-mail: aldo_rf10@hotmail.com

Resid Pediatr. 2024;14(3). DOI: 10.25060/residpediatr-2024.v14n3-674

This work is licensed under a Creative Commons Attribution 4.0 International License.

INTRODUCTION

Garre's osteomyelitis (GO) is a rare, chronic, inflammatory disease characterized by periosteal reaction with new bone formation secondary to bacterial odontogenic infection.[1,2] The mandible is the most affected bone structure in patients with GO.[3]

The pathophysiology of the condition needs to be better understood. However, the role of odontogenic infection in the development and local dissemination of the disease and cortical bone perforation is notable. The disease causes new bone to form beneath the periosteum.[4] Some of the features of the pathophysiology of GO include preferential involvement of young individuals presenting dynamic bone tissue with high periosteal activity, which, when associated with a low virulence infection, results in an imbalance between osteoblastic and osteoclastic activity.[5]

Odontogenic bacterial infection resulting from periapical or periodontal abscesses, pericoronitis, infected tooth extraction wounds, or fracture wounds is a predisposing factor.[6]

The literature describes a higher prevalence of OG in individuals in the first or second decade of life, with a slight preference for males. A higher incidence is also observed in cases involving the lower molar teeth.[3]

The diagnosis of GO is based on clinical and imaging signs. Findings include a hard, swollen posterior edge of the mandible causing facial asymmetry, occasionally associated with local skin changes and regional lymphadenopathy. A periapical lesion associated with tooth decay has been described. X-ray images show expanded bone with generalized sclerosis.[7] New bone formation beneath the periosteum is a characteristic sign of the disease.[4,5]

The most common treatment for GO is extracting the affected tooth, followed by antibiotic therapy. Differential diagnoses include Ewing sarcoma, fibrous dysplasia, osteogenic sarcoma, cortical hyperostosis, bony exostosis, and osteoma.[6] This article describes the case of a pediatric patient with Garre's Osteomyelitis and the condition's diagnostic signs and development pattern.

CASE REPORT

A once-healthy 12-year-old boy had episodes of pain in the lower dental arch for a month and developed an extensive carious lesion on the lower right first molar. A stiff, tumor-like lesion appeared in his right mandible (Figure 1A). The patient said he felt no pain on the site of the lesion or when he chewed. He did not have a fever or respiratory or gastrointestinal symptoms.

Computed tomography (CT) scans of the face without contrast showed a periapical lytic lesion along the right first and second lower premolars, involving the adjacent external cortical bone associated with periosteal reaction (Figure 2A). GO was considered a likely diagnosis,

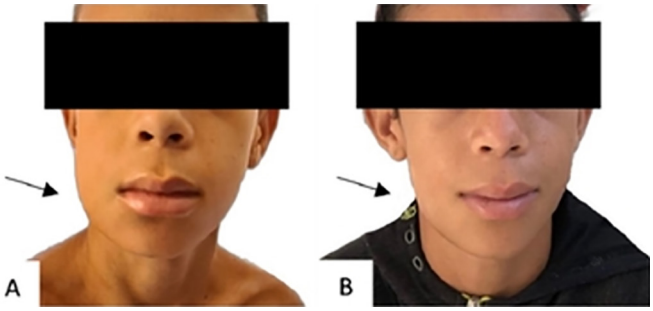

Figure 1. A - The tumor-like lesion at diagnosis. The patient has a swollen mandible and facial asymmetry (arrow). B - Image after treatment (antibiotic therapy and extraction of the lower right first molar) with facial asymmetry resolved (arrow).

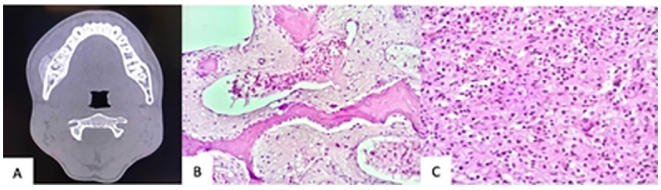

Figure 2. A – CT scan of the face without contrast showing a periapical lytic lesion along the right first and second lower premolars and the adjacent external bone cortex associated with periosteal reaction. B and C – H&E-stained slides from a bone biopsy of the mandible showing fibrous tissue, dilated blood vessels in trabecular bone, and an intertrabecular inflammatory infiltrate rich in plasma cells, lymphocytes, histiocytes, and neutrophils.

and the patient was referred to the dental care service for an evaluation.

The right lower first molar (tooth 46) was extracted, and a bone tissue biopsy was ordered. The slices stained with hematoxylin-eosin revealed the presence of fibrous tissue, dilated blood vessels in trabecular bone, and an intertrabecular inflammatory infiltrate rich in plasma cells, lymphocytes, histiocytes, and neutrophils, suggestive of GO. A bone specimen was sent for culture, and no bacterial growth was observed.

The patient was prescribed antibiotic therapy with intravenous clindamycin for seven days. The lesion healed gradually, and the patient was prescribed an additional six weeks of oral antibiotic therapy. Treatment was suspended once the signs of disease were gone (Figure 1B).

DISCUSSION

In 1893, Carl Garrè published an article describing a case of osteomyelitis, with peripheral formation of reactive bone secondary to infection or inflammation. The condition has since been known as Garre's osteomyelitis (GO).[1,2]

The present article describes the case of a 12-year-old boy diagnosed with GO[7]. According to Fukuda et al., this condition affects individuals of both genders aged around 13 years, with a slight preference for males.

Akgul et al. described that patients with GO develop facial asymmetry, and pain is not a frequent finding, unlike

the case described herein. Though of the non-suppurative type, cutaneous fistulae are a possible complication. Other symptoms include fever and lymphadenopathy[3].

In the literature, odontogenic infection has been notably associated with GO. Our patient had an extensive carious lesion in the lower right first molar. Nogueira et al. reported that the lower first molar is more frequently involved with associated periapical infection. Other non-infectious causes of disease have been described, such as odontogenic cysts and trauma[4].

Complementary imaging and laboratory tests are not pathognomonic. Imaging shows bone enlargement with generalized sclerosis associated with hyperplasia and bone lysis. Garre's osteomyelitis also manifests as periosteal thickening and new bone formation. Most lesions are located around the vestibular cortex of the teeth where periostitis originates[8,9]. Culture results positive for bacteria are rare, as seen in this case report.

Differential diagnosis includes benign and malignant conditions. Eversole et al. described the main characteristics of GO as facial asymmetry due to bone edema, benign histopathological findings, lesions secondary to infection or trauma, and complete or partial bone remodeling once the infection has been treated[7,9-11].

Differential diagnoses include fibrous dysplasia, syphilis, acne, pustulosis, hyperostosis and osteitis, Paget's disease, osteoid osteoma, Ewing sarcoma, osteosarcoma, and eosinophilic granuloma[12].

Histopathology is generally reserved for cases where the diagnosis is unclear, or no characteristic lesions are observed on imaging. New bone formation under the periosteum is a sign of the disease. Perpendicular bone trabeculae surrounded by osteoblasts, inflammatory cell infiltration, and signs of chronic osteomyelitis[2,9,10] are also observed. Due to the rarity of the case, a diagnostic biopsy of the lesion was performed.

The resolution of the disease requires a combination of antimicrobial therapy and complete removal of infected and necrotic tissue, as performed in our patient. Clindamycin was chosen because it provides good coverage for bacteria associated with odontogenic infection. Hyperbaric oxygen therapy has also been added to treatment with good results.[3,6]

GO is a benign condition. Patients improve when treated with antibiotics, and the infection that causes it resolves.[2]

CONCLUSION

Garre's Osteomyelitis is a chronic and rare inflammatory disease in the pediatric population. This case stresses the relevance of the disease in dental and pediatric care. GO must be considered in individuals with associated dental involvement. Diagnosis is based primarily on clinical and imaging signs, but histology plays a role in doubtful cases. Patients progress well when appropriate treatment is started, which includes removing foci of infection and introducing adjuvant antibiotic therapy.

REFERENCES

1. Wood RE, Nortje CJ, Grotepass F, Schmidt S, Harris AM. Periostitis ossificans versus Garrè's osteomyelitis. Part I. What did Garrè really say. Oral Surg Oral Med Oral Pathol. 1988;65(6):773-7.
2. Barros JSM, Barra SG, Wanzeler AMV, Manzi FR. Osteomielite de Garré: Relato de caso clínico. Rev Fac Odontol Lins. 2015;25(1):79-83.
3. Akgül HM, Çağlayan F, Yılmaz SG, Derindağ G. Garre's Osteomyelitis of the Mandible Caused by Infected Tooth. Case Rep Dent. 2018;1(1):1-4.
4. Nogueira PTBC, Pereira JPLD, Rodrigues LR, Costa VS, Nemezio MA, Silva AA. Osteomielite crônica com periostite proliferativa em mandíbula: relato de caso. Braz J Surg Clin Res. 2018;23(1):89-92.
5. Silva MM, Castro AL, Castro EVFL, Coclete GA. Osteomielite de Garré: atualização do tema e relato de dois novos casos clínicos. Rev Bras Odontol. 2009;66(1):8-11.
6. Park J, Myoung H. Chronic suppurative osteomyelitis with proliferative periostitis related to a fully impacted third molar germ: a report of two cases. J Korean Assoc Oral and Maxillofac Surg. 2016;42(4):215-20.
7. Fukuda M, Inoue K, Sakashita H. Periostitis Ossificans arising in the mandibular bone of a young patient: report of an unusual case and review of the literature. J Oral Maxillofac Surg. 2017;75(9):1834-e1–e8.
8. Nikomarov D, Zaidman M, Katzman A, Keren Y, Eidelman M. New treatment option for sclerosing osteomyelitis of Garré. J Pediatr Orthop B. 2013;22(6):577-82.
9. Liu D, Zhang J, Li C, Liu X, Zheng J. Chronic osteomyelitis with proliferative periostitis of the mandibular body: report of a case and review of the literature. Ann R Coll Surg Engl. 2019;101(5):328-32.
10. Eversole LR, Leider AS, Corwin JO et al. Periostite proliferativa de Garre: sua diferenciação de outras neoperiostoses. J Oral Surg 1979; 37(10): 725–731.
11. Shah KM, Karagir A, Adaki S. Chronic non-suppurative osteomyelitis with proliferative periostitis or Garre's osteomyelitis. BMJ Case Rep. 2013;1(2):1-2.
12. Song S, Jeong HJ, Shin HK, Kim E, Park SJ. Sclerosing osteomyelitis of Garré: A confusing clinical diagnosis. J Orthop Surg. 2019;27(3):1-4.