Residência RP Pediátrica
Publicação Oficial da Sociedade Brasileira de Pediatria
ISSN-Online: 2236-6814

Submitted on: 04/13/2023
Approved on: 11/30/2023

CASE REPORT

Tricuspid atresia diagnosed in preschool age: case report

Rebeca Holanda Nunes[1], Sônia Maria Cavalcante da Rocha[2], Nabel Anderson de Lencaster Saldanha da Cunha[2], Genivalda de Medeiros Barros[2], Mylene Arrais dos Santos[2], Amanda Carneiro Donato[2], Henrique Lobo Saraiva Barros[2], Viviane Portela Queiroz[3], Aluisio Kennedy de Sousa Filho[4]

Keywords:
Tricuspid Atresia, Heart Diseases, Child Care.

Abstract

Introduction: Congenital heart diseases are non-communicable diseases of high incidence in the pediatric population, with variable severity spectrum. The suspicion of congenital heart disease diagnosis begins in the intrauterine period. **Case report:** A child was diagnosed at three years and nine months of age with complex congenital heart disease. He did not undergo the heart test in the maternity hospital, was not followed-up during childcare, and when he presented cardiac symptoms, he was evaluated by professionals with no experience with children. **Discussion:** It is evident that the whole socioeconomic context influenced the delay in diagnosis. In addition, pediatric follow-up by untrained professionals may lead to misconduct, harming the patient. **Conclusion:** The failure of primary care can delay therapy, prolonging symptoms and increasing the risk of morbidity and mortality in the pediatric population, with risks that have not yet been measured.

[1] Hospital Infantil Albert Sabin, Pediatria Geral, Fortaleza, Ceará, Brazil.
[2] Hospital Infantil Albert Sabin, Cardiologia Pediátrica, Fortaleza, Ceará, Brazil.
[3] Hospital Universitário Walter Cantídio, Pediatria Geral, Fortaleza, Ceará, Brazil.
[4] Universidade Estadual do Ceará, Medicina, Fortaleza, Ceará, Brasil.

Correspondence to:
Rebeca Holanda Nunes.
Hospital Infantil Albert Sabin, Pediatria Geral, Fortaleza, Ceará, Brazil. R. Tertuliano Sales, 544, Vila União, Fortaleza, CE, Brazil. CEP: 60410-794. E-mail: rebecahnunes@gmail.com

Resid Pediatr. 2024;14(3). DOI: 10.25060/residpediatr-2024.v14n3-1091

This work is licensed under a Creative Commons Attribution 4.0 International License.

INTRODUCTION

Congenital heart disease is a non-communicable condition with a high incidence in the pediatric population, with an estimated frequency of eight in every 1,000 live births worldwide, and that predominantly affects males[1]. The severity of involvement varies, but diagnosis is possible from intrauterine life up to a few weeks after birth based on imaging tests and adequate physical examination. The preschool age range is two to six years old. Therefore, a diagnosis of congenital heart disease in this age range can delay treatment and prolong the time with symptoms.

Tricuspid atresia is a rare condition characterized by the absence of atrioventricular communication on the right side of the heart, potentially associated with other cardiac malformations according to the Kuhne classification, which was later modified by Edwards, as described in Table 1[2-4]. The most common type is valve atresia associated with pulmonary stenosis and ventricular septal defect (IB). The great arteries may be transposed in 15% to 25% of the cases, making treatment more difficult[5]. Pulmonary blood flow may be increased or decreased, depending on the classification above, but, in general, the clinical signs and symptoms include central or peripheral cyanosis and signs of heart failure (dyspnea, weight loss, fatigue during breastfeeding, and others). During physical examination, cardiac auscultation findings may vary depending on the magnitude of the septal defect. Several findings may be present, such as a systolic murmur of varying intensity, a hyperphonetic first heart sound (S1) or a split second heart sound (S2). However, diagnosis is only confirmed by echocardiography with direct visualization of blood flow between the cardiac chambers.

In this context, it is clear that diagnosing complex heart diseases requires clinical suspicion, screening methods, detailed physical examination, and adequate supplementary tests to estimate morbidity and establish the appropriate course of therapy for each patient. Diagnostic delays may impose greater difficulty in clinical and/or surgical management, thus increasing the risk of morbidity and mortality in pediatric patients.

OBJECTIVE

To report a case in which the diagnosis of a rare complex congenital heart disease was delayed as more attention was given to supplementary tests than to the patient's clinical signs and symptoms.

METHOD

This article describes the case of a three-year-old hospitalized at the Albert Sabin Children's Hospital in Fortaleza, Brazil. The hospital's Pediatric Cardiology team monitored the patient's clinical status daily based on physical examination, supplementary tests, and medical record data.

This study was conducted by the regulatory standards and guidelines for research involving human beings stipulated in Resolution 466/2012 of the National Health Council (CNS).

The person responsible for the child described in the report was informed about the study's objective and importance and signed an Informed Consent Form.

The risks related to the study include data leakage. This article's benefits include generating scientific knowledge that may influence the care provided to children with rare and complex congenital heart disease.

The articles listed in the references were selected from Pubmed and the medical literature collection of the supervisors of this case report. They were chosen based on keywords related to the subject of interest.

The research protocol was submitted for consideration by the Ethics Committee for the Analysis of Research Projects—Ethics and Research Committee and, upon approval, granted certificate number 67453223.7.0000.5042, as described in opinion report 5,999,972. This article was registered with the National Information System on Ethics in Research Involving Human Beings (SISNEP).

CASE REPORT

A 3-year-old and 9-month-old from a city in the interior of Ceará developed flu-like symptoms associated with moderate

Table 1. Classification of Tricuspid Atresia (Kuhn and Edwards).

TA 1: Normally related great arteries
A: pulmonary atresia
B: small ventricular septal defect with pulmonary stenosis
C: large ventricular septal defect without pulmonary stenosis
TA 2: transposition of the great arteries
A: interventricular septal defect with pulmonary atresia
B: interventricular septal defect with pulmonary stenosis
C: interventricular septal defect without pulmonary stenosis
TA 3: Transposition of malposition of the great arteries associated with complex lesions (truncus arteriosus or atrioventricular septal defect)

*TA: tricuspid atresia.

respiratory distress and central cyanosis requiring ventilation due to a drop in oxygen saturation compared to normal parameters for the general pediatric population (the parents did not know the patient's baseline saturation). Examination performed on admission revealed a 5+/6+ holosystolic murmur, clearly audible on all auscultation sites, with normal thrill and heart sounds, and no precordial bulge. A chest X-ray revealed an enlarged cardiac silhouette and bilateral lung infiltrates and consolidations. No edema, skin or mucosal alterations, dysmorphisms, or other clinical findings were observed. The patient's growth curves were within normal range, both in weight and height for age. After the initial evaluation, the patient was diagnosed with community-acquired pneumonia and referred to a hospital in his hometown, 325 km from Fortaleza. The patient was later referred to a tertiary pediatric hospital in Fortaleza due to the persistence of respiratory distress and central cyanosis despite antibiotic therapy and adequate oxygen support. Upon arrival at the referral hospital, antimicrobial therapy was maintained for ten days, after which the patient showed clinical and workup improvement. A more thorough investigation into a possible heart disease was carried out concomitantly.

The mother had no relevant findings in her obstetric history. The patient's family did not have a history of heart disease. The mother did not undergo a morphological ultrasound examination during pregnancy because the test was not available in her hometown. According to her pregnancy card records, her prenatal care was uneventful. The infant was born vaginally after a full-term pregnancy and was discharged from the maternity ward 48 hours after birth, having undergone the following neonatal screening tests: eye test (normal), ear test (required retesting), and tongue test (required retesting). The heel prick test performed at a primary healthcare clinic showed no signs of concern. For reasons unknown to the mother, a cardiac test was not performed. The infant was exclusively breastfed until six months old, without difficulty or dyspnea. At seven months of age, the patient began to show mild, nonspecific symptoms of central cyanosis, sweating, and tachydyspnea related to physical exertion. During this period, the patient was taken to a general practitioner since no pediatrician was available in town. An echocardiogram was ordered. A physician with no experience in pediatrics performed it and cited an "atrioventricular canal" in the report. The patient remained with mild symptoms and without a pediatrician or a cardiologist since there was none in town. At two years of age, during a visit with a general practitioner, another echocardiogram was ordered because of the alteration cited in the first report. Again, the examination was performed by a physician without experience in pediatrics. The report read the patient was normal from an anatomical and functional point of view, showing a left ventricular ejection fraction of 62%. Only at the referral hospital, at three years and nine months of age, was the patient re-evaluated by specialists with imaging tests, which showed tricuspid atresia, a small interatrial communication, mild mitral insufficiency, and a large interventricular communication with increased pulmonary flow (Figure 1).

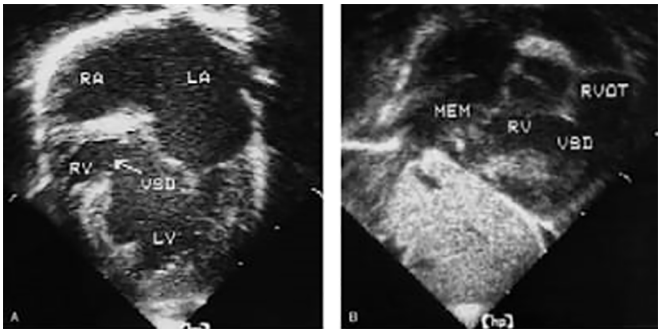

Figure 1. Echocardiogram showing type 1C tricuspid atresia with normally related great arteries and a large interventricular septal defect without pulmonary stenosis.

The infection resolved during hospitalization, and the patient was started on medication to improve cardiac function. The patient was discharged and referred to a pediatric cardiology service for surgery and clinical follow-up.

DISCUSSION

In the case described, the diagnosis of complex congenital heart disease was delayed for several reasons, ranging from failures in prenatal care to difficulties accessing pediatric care.

A morphological ultrasound examination performed during pregnancy may help to identify various malformations, including congenital heart disease[6]. However, this examination is optional under the Brazilian Unified Health System, making it harder to access it at a public healthcare facility[6]. The fetal echocardiogram is a well-established test by national and international cardiology and radiology associations for diagnosing intrauterine heart disease. Still, this test is even more limited in availability, both due to the smaller number of qualified professionals and its high cost[7,8]. The patient's mother did not have access to these tests in her hometown and was not advised to seek them in a private clinic.

Regarding neonatal care, in 2014 the Ministry of Health mandated that all newborns undergo cardiac testing before they are discharged from the maternity ward. The test screens newborns for critical congenital heart disease. It is easy to perform, affordable, noninvasive, and can be performed by healthcare workers after basic training[9-11]. Nevertheless, the patient described in this report was not screened for reasons yet unclear. Given the overarching context, the probable reason was a lack of adequate equipment or professionals trained to perform the tests.

Proper childcare is also an important tool in diagnosing congenital heart disease[12] since basic changes suggestive of complex conditions can be identified in physical examination, such as murmurs, peripheral pulse asymmetry, and peripheral or central cyanosis, among others[13]. Longitudinal monitoring also allows patients to be referred more promptly to specialized care when needed. Although the Brazilian Unified

Health System stipulates the right to universal access to a pediatrician, the reality of many economically disadvantaged communities precludes this possibility. The lack of trained professionals and pediatric follow-up can delay the diagnosis of complex heart diseases and consequently increase the risk of childhood morbidity and mortality[9].

It is also worth noting that the echocardiogram report did not match the patient's structural condition. The test was conducted by a professional with little experience in pediatrics. Supplementary tests must be performed and reviewed by professionals specialized in pediatrics so that the anatomical and physiological particularities of this population are properly considered and interpretation errors are avoided.

Difficulty accessing specialized healthcare adversely affects the ability to manage diseases properly. Most specialized centers are located in large cities. Limited access is an issue at public and private clinics. Geographic distance, poor access to public transport, and underprivileged socioeconomic conditions also contribute to the issue[14].

CONCLUSION

Congenital heart disease can be diagnosed during intrauterine life based on detailed history and physical examination, associated with specific supplementary tests. Failure to provide prenatal care and childcare may delay the diagnosis of complex diseases, with consequent impacts on surgery scheduling and increased risk of infant morbidity and mortality.

Healthcare workers in the public healthcare system must be able to identify cases suspected of congenital heart disease as soon as possible, be aware of what they should look for in a patient's history to recommend additional testing in accordance with Ministry of Health guidelines and explain to parents what other tests they might seek at a private clinic or hospital.

In addition, childcare must be longitudinally delivered by a trained professional to guarantee access to healthcare for the pediatric population. The importance of childcare cannot be overstated. Society must be educated about the importance of proper pediatric care.

REFERENCES

1. Valentín A. Cardiopatías congénitas en edad pediátrica, aspectos clínicos y epidemiológicos. Rev Médica Electrónica [Internet]. 2018; [2022 Dez 15]; 40(4):1083–99. Disponible en: http://scielo.sld.cu/scielo.php?script=sci_arttext&pid=S1684-18242018000400015.
2. Morejón AEG, Ricardo GS, Ramírez FD, Sanz LM. Atresia pulmonar con septum interventricular intacto. Rev Cubana Pediatr. 2012;84(4):401–5.
3. Park MK. PARK - Cardiologia pediátrica. 6. ed. SãoPaulo:GEN Guanabara Koogan; Com Pin edição; 2015. 696 p.
4. Silva G, Lima J, Palis L, Braga L. Atresia of tricuspid valve and hypoplasia of the right ventricle. Res Pediátr. 2017;7(3):118–9.
5. Beerman LB. Atresia tricúspide. Manual MSD - versão para profissionais de saúde [Internet]. 2020; [citado 2022 Dez 11]. Disponível em: https://www.msdmanuals.com/pt-br/profissional/pediatria/anomalias-cardiovasculares-congênitas/atresia-tricúspide.
6. Ministério da Saúde (BR). Secretaria de Atenção à Saúde. Departamento de Atenção Básica. Atenção ao pré-natal de baixo risco. Brasília, DF: Editora do Ministério da Saúde; 2012; [citado em 2022 Dez 16]. 318 p. Série A. Normas e Manuais Técnicos. Cadernos de Atenção Básica, n° 32. Disponível em: https://bvsms.saude.gov.br/bvs/publicacoes/cadernos_atencao_basica_32_prenatal.pdf.
7. Pedra SRFF, Zielinsky P, Binotto CN, Martins CN, Fonseca ESVB, Guimarães ICB, et al. Brazilian fetal cardiology guidelines – 2019. Arq Bras Cardiol. 2019;112(5):600–48.
8. The International Society of Ultrasound in Obstetrics. ISUOG Practice Guidelines (updated): sonographic screening examination of the fetal heart. Ultrasound Obstet Gynecol. 2013;41(3):348–59.
9. Amorim MS, Guimarães Filho GC, Fernandes NA, Lopes IC de OL, Cabral FRS, Guimarães AM, et al. A realidade da cardiopatia congenita no Brasil: revisão bibliográfica. Braz J Heal Rev. 2021;4(5):19378–88.
10. Ministério da Saúde (BR). Departamento de Gestão e Incorporação de Tecnologias em Saúde da Secretaria de Ciência, Tecnologia e Insumos Estratégicos (DGITS/SCTIE). Comissão Nacional de Incorporação de Tecnologias no SUS (CONITEC). Relatório n° 115. Teste do Coraçãozinho (Oximetria de PULSO) Na Triagem Neonatal. Brasília, DF: Ministério da Saúde; 2015.
11. Sociedade Brasileira de Pediatria (SBP). Departamento Científico de Cardiologia. Departamento Científico de Neonatologia. Manual de Orientação. Sistematização do atendimento ao recém-nascido com suspeita ou diagnóstico de cardiopatia congênita. São Paulo: SBP; 2022.
12. Lopes SAVDA, Guimarães ICB, Costa SFO, Acosta AX, Sandes KA, Mendes CMC. Mortality for critical congenital heart diseases and associated risk factors in newborns. A cohort study. Arq Bras Cardiol. 2018;111(5):666–73.
13. Guimarães AW, Sousa JPS, Castro Júnior JWG, Santos LC, Miranda ME. Anamnese Pediátrica. Estudos Avançados Sobre Saúde E Natureza [Internet]. 2022; [citado 2022 Dez 22]. Disponível em: https://www.periodicojs.com.br/index.php/easn/article/view/924
14. Silva MF, Moreira MCN. Dilemas na regulação do acesso à atenção especializada de crianças com condições crônicas complexas de saúde. Cienc Saude Coletiva. 2021;26(6):2215–24.