Residência RP Pediátrica
Publicação Oficial da Sociedade Brasileira de Pediatria
ISSN-Online: 2236-6814

Submitted on: 08/29/2023
Approved on: 02/01/2024

CASE REPORT

Clinical radiological dissociation in an infant with pulmonary tuberculosis: Case report

Débora Elisabeth Sales Vieira[1], Rafael José Souza Filho[1], Rebecca da Silva Sales Vieira[1], Ana Carolina Gonçalves Galeano Arco[2], Juliènne Martins Araújo[2], Clarissa Netto dos Reys Laia Franco Prillwitz[1], Christiane Mello Schmidt[1], Claudete Araújo Cardoso[1]

Keywords:
Tuberculosis, pulmonar, Diagnosis, infant.

Abstract

Pulmonary tuberculosis (TB) is a preventable treatable and infectious disease caused by Mycobacterium tuberculosis (Mtb). The infection occurs through the inhalation of droplets expelled by an individual with the active disease. Most cases develop latent infection, and a minority manifest the active form of the disease. As in adults, TB in children has predominantly pulmonary involvement, and usually present with non specific symptoms such as fever, respiratory distress, cough, weight loss or no gain, rales and wheezing. The etiological diagnosis is difficult due to the reduced number of bacilli in the lesions. This is the case of a 5 month old infant, female, previously healthy, with a persistent cough for three months, with chest wheeze and inappetence, but without manifestation of fever. The chest X-ray showed extensive lung consolidation affecting the entire right hemithorax. During hospitalization, the patient showed no improvement in the radiological appearance despite the use of broad-spectrum antibiotics. The diagnosis of Mtb infection was confirmed by a polymerase chain reaction test (Xpert Ultra MTB-RIF®). The patient was discharged to complete the treatment - rifampicin-isoniazid-pyrazinamide in an outpatient clinic with good clinical outcome. Due to the particularities of pediatric TB, highlightining the non-specificity of the signs and symptoms and the paucibacillary lesions, one must beawared of this diagnosis, especially in the presence of radiological clinical dissociation.

[1] Universidade Federal Fluminense, Pediatria, Departamento Materno-Infantil, Faculdade de Medicina, Niterói, Rio de Janeiro, Brazil.
[2] Hospital Getúlio Vargas Filho, Emergência Pediátrica, Niterói, Rio de Janeiro, Brazil.

Correspondence to:
Claudete Araújo Cardoso.
Universidade Federal Fluminense, Pediatria, Departamento Materno-Infantil, Faculdade de Medicina, Niterói, RJ, Brazil. R. Des. Athayde Parreiras, 100, Fátima, Niterói, RJ, Brazil. CEP: 24070-090. E-mail: claudetecardoso@id.uff.br

Resid Pediatr. 2024;14(3). DOI: 10.25060/residpediatr-2024.v14n3-1151

This work is licensed under a Creative Commons Attribution 4.0 International License.

INTRODUCTION

Pulmonary tuberculosis (TB) is an infectious disease caused by an imbalance in the invasion of the Mycobacterium tuberculosis (Mtb) in relation to the host's immune response. The majority of infected individuals present latent infection, and the minority the active form of the disease, with pulmonary manifestation being more frequent. Low- and middle-income countries account for 80% of TB cases[1].

In 2022, 7.5 million individuals were diagnosed with this disease worldwide; of which 900,000 were children[1]. According to DataSUS, in 2022, in Brazil, 1,960 children under the age of nine were diagnosed with TB, of which 1,431 (73%) manifested the pulmonary form of the disease and 105 (5%) progressed to pulmonary and extrapulmonary forms[2]. However, it is necessary to consider that TB is underreported at younger ages, since children present non-specific symptoms of respiratory tract infections or are oligosymptomatic[3-5]. According to recent data from DATASUS, in 2022, national vaccination coverage for BCG was 90% and in the state of Rio de Janeiro the rate remained at 76.2%, the second worst in Brazil.

Pediatric pulmonary TB is distinct in some aspects from adult-type TB. Children under 10 years of age develop paucibacillary pulmonary forms and it is difficult to obtain a satisfactory biological specimen[3-5]. Furthermore, infants are at greater risk of developing the active and severe form of the disease[4-6] and generally present nonspecific signs and symptoms. There are factors that increase the morbidity and mortality of TB in children, especially in infants, including young age, malnutrition, lack of BCG vaccination and a developing immune system.

The objective of this study is to report the case of an infant with an initial diagnosis of severe community-acquired pneumonia, presenting clinical and radiological dissociation, and to emphasize the need to consider the diagnosis of TB in children with prolonged pneumonia without response to antibiotic therapy for common pathogens.

The study was approved by the Ethics and Research Committee of the Medical School of the Universidade Federal Fluminense (CAAE nº 57892822.2.0000.5243)

CASE DESCRIPTION

Infant aged five months and 24 days, female, black, born and living in São Gonçalo, Rio de Janeiro. Admitted to the pediatric emergency department, with a dry and persistent cough for three months, without fever, vomiting and other symptoms. She went to the doctor a few times, and was treated with inhaled beclomethasone and salbutamol, showing partial improvement in symptoms, but with progression to a productive cough, hyaline-colored secretion, associated with wheezing and loss of appetite.

Born at term, without complications in the neonatal period. She received exclusive breastfeeding until she was four months old. She denied comorbidities, allergies, hospitalizations and previous surgeries. She received the BCG and hepatitis B vaccines at birth. The other vaccines were incomplete according to the NIP (National Immunization Program). She initially showed satisfactory growth for her age, but with stagnant weight gain and no changes in development. She denied prior contact with TB.

She was in good general condition, afebrile, weighing 7,500 grams (between z-score -2 and 0) and with mild intercostal insufficiency. Lung auscultation showed a decrease in breath sounds in the right hemithorax with diffuse rhonchi. Absence of lymphadenopathy and visceromegaly. The remainder of the physical examination was unremarkable. The chest X-ray demonstrated opacification in almost the entire right hemithorax (figure 1-A). Laboratory investigation showed anemia (hemoglobin: 8.9g/dL, microcytic-normochromic), leukocytosis (leukocytes: 20,100/mm³ - 0/1/0/0/6/80/11/2) without left shift and platelets of 566,000/mm³), elevated C-reactive protein (PCR: 311.9 mg/L, reference <6 mg/L), negative anti-HIV serology and viral panel (SARS-CoV-2, respiratory syncytial virus and Influenza). Due to operational issues, it was not possible to perform a tuberculin skin test (TT) at the unit.

Antibiotic therapy was started shortly after admission, with crystalline penicillin 200,000 IU/kg/day. During hospitalization, after five days of treatment, a new chest x-ray was performed (figure 1-B), which demonstrated the veiling of the entire right hemithorax, and the antibiotic was changed to ceftriaxone and vancomycin. However, after the fourth day of treatment, Figures 1C and 1D; respectively, there was no radiological improvement and an image suggesting excavation

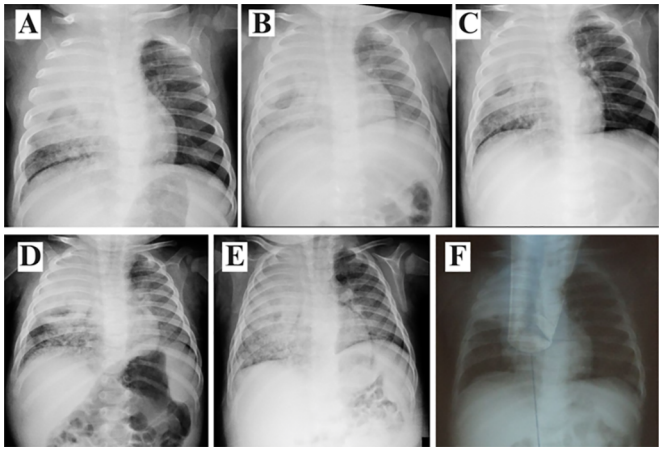

Figure 1. A) Consolidation in a large part of the right hemithorax; B) Coverage of the entire right hemithorax after five days of treatment with crystalline penicillin and change of regimen to vancomycin and ceftriaxone; C) 8th day of hospitalization: hypotransparency in almost the entire right hemithorax, with preservation of a small lung area at the base; D) 18th day: maintenance of pulmonary involvement despite broad-spectrum antibiotic therapy. Collected LBA for Xpert MTB/RIF; E) 22nd day: increase in pulmonary involvement while taking vancomycin and cefepime. New negative viral panel; F) Decreased hypotransparency in the right hemithorax after 2 months of treatment with rifampicin-isoniazid-pyrazinamide RIP).

on the right appeared. A new blood count also showed anemia and a slight increase in the number of leukocytes (22,100/mm³ - 0/0/0/0/1/61/35/2) and CRP 137 mg/L.

As there was a persistent radiological image, after 10 days, ceftriaxone was changed to cefepime, and vancomycin continued. After 19 days of antibiotic therapy, the Xpert Ultra MTB-RIF® molecular test of bronchoalveolar lavage (BAL) was performed due to suspicion of pulmonary TB due to clinical and radiological dissociation, as the patient still had extensive hypotransparency on the chest X-ray; but she was clinically stable, without fever and in good general health.

The chest CT was performed on the 22nd day of hospitalization as shown in figure 2.

After 24 days of vancomycin and 14 days of cefepime, there was radiological worsening due to noticeable hypotransparency at the base of the left hemithorax, which began to progress with wheezing and increased dyspnea. At this time, meropenem and the RIP regimen associated with vancomycin were started. The rapid molecular test detected Mtb sensitive to rifampicin. Subsequently, with growing suspicion of the possibility of pulmonary TB in the infant, the mother recalled that the patient's caregiver lived with a person recently diagnosed with TB. The Xpert Ultra MTB-RIF® molecular bronchoalveolar lavage (BAL) test was performed prior to the interview.

After two months of treatment with the RIP regimen, there was an improvement in the radiological image and the infant remained clinically well, progressing to clinical cure at the end of treatment. (figure 1F).

DISCUSSION

In pediatric pulmonary TB, signs and symptoms may include fever, weight loss or lack of weight gain, persistent cough, wheezing, respiratory distress, hepatosplenomegaly, lymphadenopathy, abdominal distension, lethargy and/or irritability[3]. Although infants manifest non-specific signs and symptoms mentioned above[3], the clinical picture already demonstrated important radiological changes, since around 50% of infants under one year of age have segmental consolidations or significant lymphadenopathy as their radiological presentation[6], this being the most common radiographic form of primary TB in children[12].

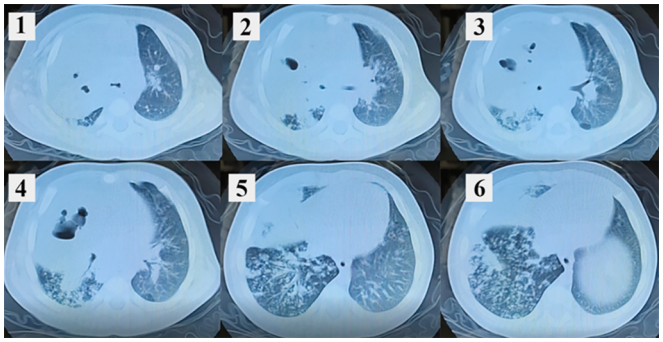

Figure 2 (1-6). Computed tomography of the 22nd day of hospitalization with extensive heterogeneous consolidation in the right hemithorax with areas of excavations and air bronchograms, some with the formation of an air-fluid level inside. Tree-in-bud pattern on both lungs, especially on the right side. The CT report contains information about prominent lymph nodes.

In the present report, the patient initially presented manifestations of a lower respiratory tract infection, with cough and dyspnea, and changes in the physical examination of the pulmonary system, which may improve with the use of symptomatic drugs and medications to treat recurrent wheezing. During the consultation, the chest X-ray showed extensive hypotransparency in the right hemithorax in the absence of fever, which is not expected in extensive pneumonia caused by common pathogens.

Cough and dyspnea are the most common symptoms of TB in infants[6], despite this, the WHO, according to the Consensus Statement on Childhood Tuberculosis[7], states that fever for a period of more than two weeks is also a factor for TB suspicion, but its absence in the infant could be a confusing factor for the healthcare team, causing diagnostic delays. The wheezing presented by the patient, common in infants and generally secondary to viral infections, may be present in cases of pediatric TB due to extrinsic compression of the bronchi resulting from mediastinal lymphadenopathy, as seen on the CT scan performed on the described patient[6,8]. It is important to highlight the importance of the differential diagnosis of recurrent wheezing in infants, especially when there is no response to treatment with bronchodilators and inhaled corticosteroids.

During the courses of antibiotic therapy, symptomatic and radiological improvement in the infant was expected, since the initial diagnostic hypothesis was severe lobar pneumonia, which did not occur. In infants, there are factors in the clinical history that increase the suspicion of TB, including prolonged pneumonia without improvement with antibiotics for common germs or worsening, contact history and radiographic findings suggestive of TB (presence of hilar and/or paratracheal lymph node disease, micronodular appearance miliary pattern and cavitations[9,10]), in the presence of a good general health.

Clinical-radiological dissociation is characterized by the presence of severe pneumonia on radiography without clinical signs of severity expected in pulmonary conditions caused by common pathogens[8]. In this case, based on the altered imaging exam, the expected clinical signs would be high fever and toxemia, but the infant had dyspnea and wheezing, remaining active and with a normal appetite despite the lack of weight gain. This characteristic persisted throughout the hospitalization.

The CT scan objective was to better evaluate the image and showed heterogeneous consolidation in the right hemithorax with excavations. These may be present in pediatric primary TB and may be related to the spread of Ghon's focus and through bronchial obstruction due to lymph node enlargement[11].

In pediatrics, diagnostic tests have different sensitivity, being up to 20%, 40% and 66% in sputum smear microscopy, culture and MRT, respectively[12]. The presence of Mtb in BAL detected by the Xpert Ultra MTB-RIF® confirmed pulmonary TB, maintaining only the RIP regimen until discharge and subsequent outpatient treatment. Bronchoscopy, the examination through which the BAL is obtained, enables a larger sample to be collected, which may increase the chance of diagnosis, given that children under 10 years of age have a low capacity to expel a significant sputum sample for this purpose. The BAL presents different sensitivities and specificities to the diagnostic methods of sputum smear microscopy, Mtb culture and MRT, in which the sensitivity and specificity of sputum smear microscopy are 19% and 96%, respectively, while sensitivity was 50% and specificity of 100% in the culture[13] ; and in relation to TRM the sensitivity and specificity are 100% and 95%, in that order[14]. The combined search by Xpert MTB/RIF in two or more samples from different sites in the airway is more accurate than in just one, despite still having lower sensitivity compared to induced sputum culture (IS) in detecting TB. Considering the difficulty of obtaining satisfactory IE samples for culture in children under 10 years of age, the use of other specimens from VA in the Xpert MTB/RIF enabled the development of new diagnostic strategies[15].

However, another possibility for investigating and diagnosing TB in the patient could be through the scoring system recommended by the Ministry of Health, which includes clinical and radiological findings, contact with an adult with TB, tuberculin skin test and nutritional status. The infant had a total of 40 points (a cough that lasted two weeks, X-ray with condensation without improvement with ATB for pneumonia and contact with an adult with TB), which makes the diagnosis very likely, enabling treatment to begin.

The importance of including pulmonary TB in the differential diagnosis of slowly evolving pneumonia, without therapeutic success with different antimicrobials and maintaining the patient's good general health, is highlighted. Whenever possible, use bacteriological tests, including the rapid molecular test. Negative results do not rule out the disease (paucibacillary nature) and the impossibility of performing them should not delay the start of the TB regimen. Clinical and radiological dissociation reinforces this diagnosis. Thus, it is possible to initiate appropriate treatment and consequently reduce morbidity and mortality in the affected population.

REFERENCES

1. World Health Organization (WHO). Global Tuberculosis Report 2021[Internet]. Genebra: WHO; 2023; [access in 2023 Dec 29]. Available from: https://www.who.int/publications/digital/global-tuberculosis-report-2021/tb-disease-burden.
2. Ministério da Saúde (BR). Sistema de Informação de Agravos de Notificação, DATASUS. Tuberculose - Casos confirmados notificados no sistema de informação de agravos de notificação – Brasil [Internet]. 2023; [acesso em 2023 Dez 29]. Disponível em: http://tabnet.datasus.gov.br/cgi/tabcgi.exe?sinannet/cnv/tubercbr.def.
3. Ministério da Saúde (BR). Secretaria de Vigilância em Saúde. Departamento de Vigilância das Doenças Transmissíveis. Manual de Recomendações para o Controle da Tuberculose no Brasil. Brasília: Ministério da Saúde, 2019; [acesso em 2022 Nov 14]. Disponível em: https://bvsms.saude.gov.br/bvs/publicacoes/manual_recomendacoes_controle_tuberculose_brasil_2_ed.pdf.
4. Dwilow R, Hui C, Kakkar F, Ian Kitai I. Pediatric Tuberculosis. In: Canadian Journal of Respiratory, Critical Care, and Sleep Medicine [Internet]. 2022; [cited 2022 Nov 16]; 6(1):129-48. DOI: https://doi.org/10.1080/24745332.2022.2043055. Available from: https://www.tandfonline.com/doi/full/10.1080/24745332.2022.2043055.
5. Newton SM, Brent AJ, Anderson S, Whittaker E, Kampmann B. Paediatric Tuberculosis. Lancet Infect Dis [Internet]. 2008; [cited 2022 Nov 16]; 8(8):498-510. DOI: https://doi.org/10.1016/S1473-3099(08)70182-8. Available from: https://pubmed.ncbi.nlm.nih.gov/18652996/.
6. Lamb GS, Starke JR. Tuberculosis in Infants and Children. Microbiol Spectr [Internet]. 2017; [cited 2022 Nov 16]; 5(2). DOI: https://doi.org/10.1128/microbiolspec.tnmi7-0037-2016. Available from: https://pubmed.ncbi.nlm.nih.gov/28387193/.
7. Indian Academy of Pediatrics (IAP), Working Groupon Tuberculosis. Consensus statement on childhood tuberculosis. Indian Pediatr [Internet]. 2010; [cited 2023 Jan 20]; 47(1):41-55. DOI: https://doi.org/10.1007/s13312-010-0008-3. Available from: https://pubmed.ncbi.nlm.nih.gov/20139477/.
8. Sant'Anna CC, March MFBP, Aurílio RB. Diagnosis of Tuberculosis among Children and Adolescents. In: Ribón W, editor. Mycobacterium - Research and Development [Internet]. 1st ed. Londres: IntechOpen; 2018; [cited 2023 Jan 20]. DOI: http://doi.org/10.5772/intechopen.69227. Available from: https://www.intechopen.com/chapters/55553.
9. Silva DR, Rabahi MF, Sant'Anna CC, Silva-Junior JLR, Capone D, Bombarda S, et al. Diagnosis of tuberculosis: a consensus statement from the Brazilian Thoracic Association. J Bras Pneumol [Internet]. 2021; [cited 2023 Jan 20]; 47(2):e20210054. DOI: https://doi.org/10.36416/1806-3756/e20210054. Available from: https://pubmed.ncbi.nlm.nih.gov/34008763/.
10. Capone D, Jansen JM, Lopes AJ, Sant'Anna CC, Soares MO, Pinto RS, et al. Diagnóstico por imagem da tuberculose pulmonar. Pulmão RJ [Internet]. 2006; [citado 2023 Dez 20]; 15(3):166-74. Disponível em: https://www.sopterj.com.br/wp-content/themes/_sopterj_redesign_2017/_revista/2006/n_03/07.pdf.
11. Griffith-Richards SB, Goussard P, Andronikou S, Gie RP, Przybojewski SJ, Strachan M, et al. Cavitating pulmonary tuberculosis in children: correlating radiology with pathogenesis. Pediatr Radiol [Internet]. 2007; [cited 2023 Dez 20]; 37:798-804. DOI: https://doi.org/10.1007/s00247-007-0496-z. Available from: https://pubmed.ncbi.nlm.nih.gov/17530241/.
12. Dunn JJ, Starke JR, Revell PA. Laboratory Diagnosis of Mycobacterium tuberculosis Infection and Disease in Children. J Clin Microbiol [Internet]. 2016; [cited 2023 Jul 14]; 54(6):1434-41. DOI: https://doi.org/10.1128/JCM.03043-15. Available from: https://pubmed.ncbi.nlm.nih.gov/26984977/.
13. Jacomelli M, Silva PRAA, Rodrigues AJ, Demarzo SE, Seicento M, Figueiredo VR. Broncoscopia no diagnóstico de tuberculose pulmonar em pacientes com baciloscopia de escarro negativa. J Bras Pneumol [Internet]. 2012; [citado 2023 Jul 14]; 38(2):167-73. DOI: https://doi.org/10.1590/S1806-37132012000200004. Disponível em: https://pesquisa.bvsalud.org/portal/resource/pt/lil-623395#:~:text=A%20broncoscopia%20representa%20um%20m%C3%A9todo,diagn%C3%B3stico%20diferencial%20com%20outras%20doen%C3%A7as.

14. Silva TM, Soares VM, Ramos MG, Santos A. Accuracy of a rapid molecular test for tuberculosis in sputum samples, broncho alveolar lavage fluid, and tracheal aspirate obtained from patients with suspected pulmonary tuberculosis at a tertiary referral hospital. J Bras Pneumol [Internet]. 2019; [cited 2023 Jul 14]; 45(2):e20170451. DOI: https://doi.org/10.1590/1806-3713/e20170451. Available from: https://pesquisa.bvsalud.org/portal/resource/pt/biblio-1040271.

15. Zar HJ, Workman LJ, Prins M, Bateman LJ, Mbhele SP, Whitman CB, et al. Tuberculosis Diagnosis in Children Using Xpert Ultra on Different Respiratory Specimens. Am J Respir Crit Care Med [Internet]. 2019; [cited 2023 Jul 14]; 200(12):1531-8. DOI: https://doi.org/10.1164/rccm.201904-0772oc. Available from: https://pubmed.ncbi.nlm.nih.gov/31381861/.