Residência RP Pediátrica
Publicação Oficial da Sociedade Brasileira de Pediatria
ISSN-Online: 2236-6814

Submitted on: 10/31/2023
Approved on: 01/15/2024

CASE REPORT

Hyperinsulinemic hypoglycemia of childhood refractory to the use of diazoxide in an infant: case report

Ana Beatriz Charantola Beloni[1], Ana Clara Charantola Beloni[2], Mila Pontes Ramos Cunha[3], Fabio Roberto Amar[1]

Keywords:
Hypoglycemia, Congenital hyperinsulinism, Beckwith-Wiedemann syndrome.

Abstract

Introduction: Hyperinsulinemic hypoglycemia in childhood is a rare and serious pathology, but it is the most common etiology of persistent hypoglycemia in children and neonates. It can be congenital, secondary, associated with metabolic diseases and genetic syndromes, such as Beckwith-Wiedmann. **Objective:** To report a case of hypoglycemia refractory to the use of diazoxide and describe the importance of diagnosis and therapy. Case discussion: female infant undergoing investigation for congenital hyperinsulinism unresponsive to diazoxide, with solid-cystic image in pancreas topography. A caudal pancreatectomy was performed, but the patient continued to experience episodes of hypoglycemia and developed abdominal distension and intolerance to the enteral diet. A new abdominal computed tomography showed signs of resection of the pancreatic tail with intestinal loops, without signs of tumor, diagnosing it as nesidioblastosis. The patient maintained hypoglycemia even with the use of Octreotide, and was referred to surgery for subtotal pancreatectomy with excision of the retroperitoneal tumor. After stabilization in the intensive care unit, he was discharged for follow-up in a pediatric endocrinology outpatient clinic and investigation for Beckwith-Wiedmann syndrome. **Conclusion:** The diagnosis is clinical and the therapy consists of the use of oral diazoxide, aiming to prevent hypoglycemic crises and avoid systemic repercussions. Due to its potential severity, delays in correct diagnosis and treatment can lead to lifelong complications, such as severe neurological damage.

[1] PUC-Campinas, Pediatria - Campinas - São Paulo - Brazil.
[2] Iamspe, Clínica Médica - São Paulo - São Paulo - Brazil.
[3] PUC-Campinas, Pediatria e Endocrinologia - Campinas - São Paulo - Brazil.

Correspondence to:
Ana Beatriz Charantola Beloni.
PUC-Campinas. Av. John Boyd Dunlop, S/N - Jardim Londres, Campinas, SP, Brazil. CEP: 13034-685. E-mail: biacbeloni@gmail.com

Resid Pediatr. 2025;15(1). DOI: 10.25060/residpediatr-2025.v15n1-1189

This work is licensed under a Creative Commons Attribution 4.0 International License.

INTRODUCTION

Hyperinsulinemic hypoglycemia of infancy (HHI) is rare, but it is the leading cause of persistent hypoglycemia in children and neonates[1]. The incidence is 1 in 50,000 births[2], but in some populations, it may affect 1 in 2,500-3,000 live births[2,3]. It occurs mainly in boys, neonates, and infants[1]. Once diagnosed, it requires prompt treatment, as it causes deterioration of the central nervous system, impairing neuropsychomotor development. Hypoglycemia has multiple etiologies and molecular alterations, with diffuse enlargement of pancreatic beta cells, known as nesidioblastosis - the most common.

CASE DESCRIPTION

AT, 3 months old, 29 weeks premature, admitted on 05/24/2021 to investigate congenital hyperinsulinism unresponsive to diazoxide. The patient was taking octreotide 34 mcg/kg/day and had an ultrasound and computed tomography (CT) scan of the abdomen showing a solid-cystic image in the pancreas. Thus, a caudal pancreatectomy was performed on 06/01/2021 and reported as a microcystic serous adenoma of the pancreas with complete lesion excision. Immunohistochemistry revealed a benign serous cyst in the pancreas. After surgery, the patient remained hypoglycemic and developed abdominal distension and intolerance to enteral nutrition. A new CT scan of the abdomen (06/16/2021) showed a lesion in the left adrenal gland, measuring approximately 3.0 cm in the largest axial axis, suspected of neoplasia (figures 1 and 2).

Abdominal MRI on 06/22/2021 showed a slightly enlarged liver and scattered focal lesions with restricted diffusion, apparently hypervascularized, suggestive of secondary neoplastic involvement; solid lesion with necrosis and central hematic focus, measuring 2.6 cm, in the left adrenal region, suspicious for neoplasia. Referred to the Support Group for Adolescents and Children with Cancer in São Paulo

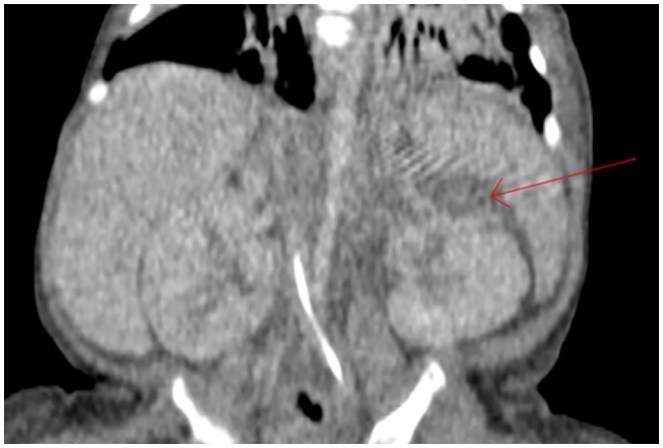

Figure 1. Arrowhead lesion in the adrenal gland. Image from the medical record.

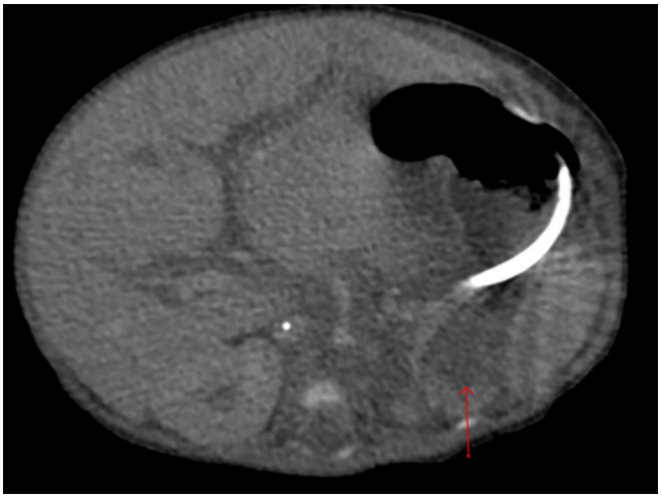

Figure 2. Arrowhead adrenal lesion. Image from medical record.

on 07/06/2021, where an abdominal CT scan showed signs of pancreatic tail resection without signs of tumor formation, ruling out neoplasia and diagnosing nesidioblastosis. Upon return, on 07/20/2021, she maintained hypoglycemia with Octreotide, being referred for subtotal pancreatectomy (80%) with excision of retroperitoneal tumor and liver biopsy on 08/03/2021. The anatomopathological report described pancreatic lymphangioma, adrenal hyperplasia, cirrhosis with moderate cholestasis, and bile duct proliferation. In the postoperative period in the pediatric ICU, she presented multiple hydroelectrolyte disturbances (hyponatremia, hypokalemia, hypomagnesemia, hypocalcemia), suggestive of Transient Adrenal Insufficiency, initiating intravenous hydrocortisone. Exome analysis showed PTCH2 gene with a variant of uncertain significance. After stabilization of the condition, she was admitted to the ward on 03/04/2022, discharged on 03/14/2022 and referred to the pediatric endocrinology outpatient clinic for follow-up. In May 2023, the genetic test showed mosaic hypermethylation of the IC1 center, mosaic hypomethylation of the IC2 center, and normal copy number of the regions studied in 11p15, compatible with a paternal uniparental disomy, confirming the genetic diagnosis of Beckwith-Wiedemann syndrome.

DISCUSSION

It has a congenital etiology, exemplified by mutations in the ABCC8, KCNJ11, HNF4A, HNF1A, GLUD1, GCK, HADH1, UCP2, MCT1, HK1, and PGM1 genes, which do not usually respond to the use of diazoxide[2,4]. Secondary forms are usually transient and related to gestational diabetes mellitus, Rh isoimmunization, perinatal asphyxia, and intrauterine growth restriction. Regarding metabolic diseases, there is tyrosinemia type 1 and glycosylation diseases. And finally, the associated genetic syndromes are Soto, Kabuki, Usher, Timothy, Costello,

Trisomy 13, Turner mosaicism and Beckwith-Wiedemann, the main one[2,4].

IHH derives from abnormal insulin secretion, despite low blood glucose levels[2], which may be associated with 3 possible alterations[1]: defect in insulin signaling in pancreatic islets with normal pancreatic beta cells; increase in pancreatic beta cells; or defect in pancreatic beta cells. The latter is divided into alterations in potassium channels or metabolic alterations [2,5]. ATP-dependent potassium channels are present in pancreatic beta cells and have 4 potassium channels (encoded by the KCNJ11 gene) and 4 sulfonylurea receptors 1-SUR1- (encoded by the ABCC8 gene). When they function normally, they trigger insulin exocytosis. The SUR1 mutation, implicated in IHH, leads to the closure of calcium channels, abnormally secreting insulin[5]. Regarding metabolic alterations, there is a defect in three enzymes: glutamate dehydrogenase, glucokinase and short-chain hydroxyacyl-CoA dehydrogenase[2,5]. Patients with defects in the glutamate dehydrogenase and hydroxyacyl-CoA dehydrogenase enzymes show a response to diazoxide, except for the glucokinase defect, as it reduces the threshold for insulin secretion and can suppress the effect of diazoxide[3]. Many genes involved in IHH are related to monogenic forms of diabetes (MODY), including the glucokinase defect leading to MODY 2 and mutations in the HNF4A and HNF1A genes that are associated with MODY 1 and MODY 3[3].

Histologically, it may be focal, diffuse or atypical[2,5]. The focal form corresponds to 30-40% of lesions and represents pancreatic regions with adenomatosis, being sporadic cases; the diffuse form, in 60-70% of cases, named Nesidioblastosis, may be familial or sporadic; the atypical form is the fusion of the two.

The clinical manifestations are IHH markers but are nonspecific in the neonatal age group. Neonates may present difficulty in breastfeeding, lethargy, pallor, apnea, poor tissue perfusion, hypothermia, seizures, macrosomia (if maternal hyperinsulinemia), hypertrophic cardiomyopathy and hepatomegaly[1,2,3,5].

The diagnosis is based on clinical criteria[1]: nonketotic hypoglycemia (blood glucose below 36 mg/dl) postprandial; hyperinsulinemia (above 3 mU/L) and need for rapid glucose infusion (above 10 mg/kg/min) to maintain blood glucose above 54 mg/dL. If the diagnosis is uncertain, intravenous glucagon can be infused at a dose of 0.03 mg/kg and blood glucose levels can be assessed at 0, 10, 20, and 30 minutes later. The blood glucose level for confirmation is above 30 mg/dl[2]. The gold standard test[2] is positron emission tomography with dopamine and fluorine-18-dihydroxyphenylalanine (PET-CT ((18)F-DOPA), but it is unavailable in many services.

The differential diagnosis includes maternal drug use during pregnancy (beta-blockers and valproic acid), prematurity, adrenal insufficiency, sepsis, insulinoma (pancreatogenic hyperinsulinemic hypoglycemia), among others[2,4]. Therefore, the following are requested: complete blood count, arterial blood gas, blood glucose, lactate, ketone bodies, C-peptide, fatty acids, electrolytes, renal function, growth hormone, cortisol and thyroid hormones[2].

Management aims to prevent hypoglycemic crises and avoid repercussions[2]. It involves intravenous infusion of glucose and glucagon in the emergency room, followed by diazoxide 5 to 20 mg/kg/day orally every 8 hours. This binds to SUR1[2] and keeps the ATP potassium channels open, preventing insulin secretion by pancreatic beta cells; however, it can cause fluid retention, heart failure, leukopenia, eosinophilia, hypertrichosis and, if extreme prematurity is associated with heart disease and lung disease, induce pulmonary hypertension, reopening of the ductus arteriosus, thrombocytopenia and hyperuricemia[4]. It is associated with diazoxide, hydrochlorothiazide, 7 to 10 mg/kg/day orally every 12 hours, due to its synergistic and hyperglycemic effect[5]. If there is no response, octreotide is used, which acts on somatostatin receptors 2 and 5, inhibiting the mobilization of intracellular calcium, reducing insulin secretion by pancreatic beta cells[4]. It starts with 5 µg/kg/day subcutaneously or intravenously, increasing to 30–35 µg/kg/day. Other medications described in the literature are Lanreotide (a somatostatin analogue), glucagon, acarbose, sirolimus and everolimus (both mTOR inhibitors). Nifedipine appears to have beneficial effects, but studies are lacking[1].

Patients need to eat at regular times with supplements of fiber, proteins, long-metabolized carbohydrates and fats. There are studies suggesting that IHH makes the nervous system more susceptible to manifestations of hypoglycemia, with the ketogenic diet being one of the forms of prevention[2].

In case of drug therapy failure, surgical treatment is indicated[1,2], and it is important to differentiate whether the pancreatic involvement is diffuse or focal. Magnetic resonance imaging, intraoperative ultrasound or contrast-enhanced CT can be used to diagnose lesions, such as insulinomas. In negative images for focal lesions, the calcium stimulation test and evaluation of insulin in the gastroduodenal artery are usually recommended. If focal, excision is curative, usually affecting the tail and body of the pancreas. In diffuse lesions, drug therapy is usually ineffective, prioritizing subtotal pancreatectomy[1,2]. In the long term, patients may develop diabetes mellitus before puberty, pancreatic insufficiency and damage to the bile duct [2].

Patients with IHH usually have diffuse lesions, difficulty swallowing and sucking; motor, speech, language and vision delays; seizures; spasms; microcephaly, muscle weakness and even cerebral palsy[2], consequences that negatively impact life. The main one would be neuropsychomotor development, which is more severe when started before 7 days of life and using the maximum dose of diazoxide. These are patients who may depend on long-term multidisciplinary care, but there are still few studies in the literature that evaluate the repercussions and impacts on the quality of life of patients.

CONCLUSION

IHH is a rare, serious entity and the main cause of hypoglycemia in childhood. It presents a nonspecific clinical picture in the neonatal period that makes early diagnosis difficult, requiring additional tests for its elucidation. Treatment involves the use of oral diazoxide to prevent hypoglycemic events and avoid systemic repercussions. Delayed treatment has repercussions on multiple organ systems, especially the central nervous system, which is undergoing rapid development during this period, leading to severe and sometimes irreversible brain damage.

BIBLIOGRAPHIC REFERENCE

1. Goel P, Choudhury SR. Persistent hyperinsulinemic hypoglycemia of infancy: An overview of current concepts. J Indian Assoc Pediatr Surg. 2012;17(3):99-103. doi:10.4103/0971-9261.98119.
2. Krawczyk S, Urbanska K, Biel N, Bielak MJ, Tarkowska A, Piekarski R,et al. Congenital Hyperinsulinaemic Hypoglycaemia-A Review and Case Presentation. J Clin Med. 2022 Oct 12;11(20):6020. doi: 10.3390/jcm11206020. PMID: 36294341; PMCID: PMC9604599.
3. Stanley CA. Perspective on the Genetics and Diagnosis of Congenital Hyperinsulinism Disorders. J Clin Endocrinol Metab. 2016 Mar;101(3):815-26. doi: 10.1210/jc.2015-3651. Epub 2016 Feb 23. PMID: 26908106; PMCID: PMC4803157.
4. Lopes AA, Miranda AC, Maior MS, de Mello RV, Bandeira FA. Nesidioblastosis Associated with Pancreatic Heterotopia as a Differential Diagnosis of Hypoglycemia: A Literature Review and Case Report. Am J Case Rep. 2020 Jul 6;21:e922778. doi: 10.12659/AJCR.922778. PMID: 32624567; PMCID: PMC7360359.
5. Liberatore Junior RDR, Martinelli Junior CE. Hipoglicemia hiperinsulinêmica da infância. Arq Bras Endocrinol Metab [Internet]. 2011Apr;55(3):177-83. doi: doi.org/10.1590/S0004-27302011000300001.