Residência RP Pediátrica
Publicação Oficial da Sociedade Brasileira de Pediatria
ISSN-Online: 2236-6814

Submitted on: 10/31/2023
Approved on: 11/30/2023

CASE REPORT

Early diagnosis of Klinefelter Syndrome: a case report

Guilherme Marcondes Ferreira Santos[1], Tarcísio Lopes[1], Othon Bergantini Waldemarin[1], Lucas Chaves de Medeiros[1], Rita de Cássia Barroso Veríssimo dos Reis[1], Luádria Alves dos Santos[1], Simone de Menezes Karam[2], Linjie Zhang[2]

Keywords:
Klinefelter Syndrome,
Case reports,
Early diagnosis.

Abstract

Klinefelter Syndrome (KS) is a genetic condition characterized by abnormalities in the sex chromosomes, affecting males, with an estimated prevalence of 1:600 live-borns1. It exhibits a wide range of symptoms, including gynecomastia, delayed puberty, reduced pubic and body hair, micropenis, tall stature, testicular dysfunction, azoospermia, speech and language delay. Pediatric diagnosis usually occurs by chance, some Brazilian studies show that approximately 21.2% of individuals with KS were diagnosed before 20 and 6.1% before 10 years old2. In this report, it is described an early diagnosis of Klinefelter Syndrome, motivated by presence of congenital malformation and family history of intellectual disability.

[1] Universidade Federal do Rio Grande, Discente de Medicina - Rio Grande - Rio Grande do Sul - Brazil.
[2] Universidade Federal do Rio Grande, Departamento de Pediatria - Rio Grande - Rio Grande do Sul - Brazil.

Correspondence to:
Guilherme Marcondes Ferreira Santos.
Universidade Federal do Rio Grande. Rua Visconde de Paranaguá, 102, sala 411, Secretaria Geral da FaMed. Rio Grande, RS, Brazil.
CEP 96203-900. E-mail: zguilherme.m@hotmail.com

Resid Pediatr. 2025;15(1). DOI: 10.25060/residpediatr-2025.v15n1-1190

This work is licensed under a Creative Commons Attribution 4.0 International License.

INTRODUCTION

Klinefelter Syndrome (KS) is a sex chromosome anomaly affecting males, with a prevalence of 1 in 600 live births[1]. Cytogenetically, it is characterized by an extra X chromosome (47, XXY) and shows considerable clinical variability, including gynecomastia, delayed puberty, decreased pubic and body hair, micropenis, tall stature, testicular dysfunction, azoospermia, increased gonadotropins, and delays in speech and language. Pediatric diagnoses typically occur incidentally, with Brazilian studies indicating that about 21.2% of KS cases are diagnosed before age 20 and 6.1% before age 10[2].

This report details an early diagnosis of KS. This report is part of a larger project for monitoring congenital anomalies (CAAE: 30886520.9.1001.5327).

CASE REPORT

The patient is a male who was born through vaginal delivery after 40 weeks of gestation, weighing 3,930 grams and measuring 51 centimeters in length. He had an Apgar score of 9/9 and a head circumference of 33.5 centimeters. No information regarding prenatal care was available. The neonatal screening tests were unremarkable.

During the physical examination, cardiac and pulmonary auscultation and the abdominal examination were normal. The patient presented with a hydrocele and a unilateral left incisive transforaminal cleft lip and palate.

Due to the malformation and the family history of intellectual deficits in the mother and siblings, karyotyping was ordered. The result was 47, XXY (Figure 1) in all analyzed cells, consistent with KS. It is important to note that the mother and siblings had already been tested for Fragile X syndrome and other non-cytogenetic conditions.

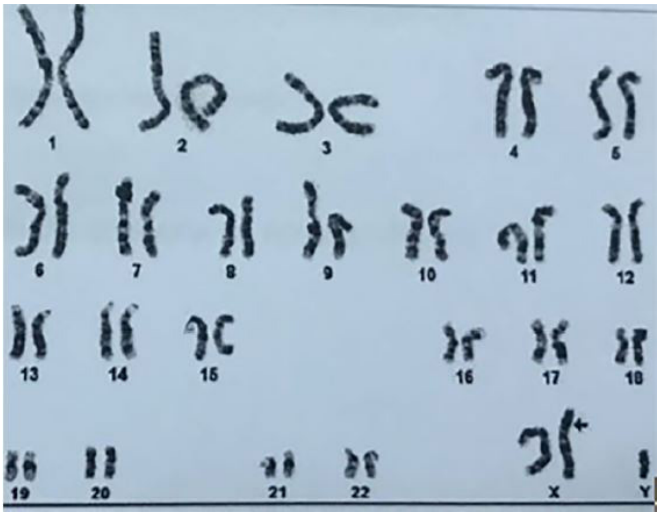

Figure 1. The patient's karyotype shows an extra X chromosome, as indicated by the arrow in the lower right corner.

During the last visit, at 7 months old, the patient weighed 9.8 kg (Z score +1), measured 72 cm in height (Z score +1), had a head circumference of 47 cm (Z score +2), and displayed global development appropriate for his age.

DISCUSSION

KS is an aneuploidy, a numerical anomaly of the sex chromosomes. Males may have extra X chromosomes. Prenatal and neonatal diagnoses of KS are rare. Cases are usually identified during adolescence or adulthood based on symptoms like gynecomastia and microorchidism. Confirmation can be achieved through cytogenetic tests such as karyotyping, chromosomal microarray, or fluorescence in situ hybridization (FISH)[3]. Diagnoses are classified as incidental, very early, early, or late[4].

Incidental and very early diagnoses are considered clinically silent. Incidental findings occur during the prenatal period, typically when cytogenetic tests are conducted for reasons unrelated to the findings, such as advanced maternal age and a family history of genetic diseases. Very early diagnosis can be categorized into two stages: at birth, indicated by the presence of micropenis and cryptorchidism, and in childhood and pre-adolescence, characterized by small testicles, long legs, tall stature, an increased fat-to-lean mass ratio, learning difficulties[3], limited speech, a lack of pubic and facial hair, behavioral and social challenges, and psychological changes.

Unlike the previously described cases, early diagnosis is considered clinically evident. In addition to the evidence observed in very early diagnosis, issues may arise during puberty and can suddenly resolve, such as hypergonadotropic hypogonadism and gynecomastia4. Ultimately, late diagnosis is marked by the complete syndrome. Beyond this, conditions such as osteopenia or osteoporosis, autoimmune disorders, and ophthalmological, dental, cardiac, and sexual problems may also occur, which collectively lead to infertility[5,6]. Furthermore, there is an increased risk of obesity, cardiovascular and metabolic diseases, tumors (including breast, extragonadal germ cell, and Leydig cell tumors), as well as thrombosis and essential tremor[3,7].

It is noteworthy that although hypogonadism is common, men with the non-classical syndrome, occasionally mosaic, present with enlarged or normal testicles[8]. Furthermore, laboratory findings in adults typically show low serum concentrations of total and free testosterone and high concentrations of follicle-stimulating hormone (FSH) and luteinizing hormone[8]. Some comorbidities are attributed to hypogonadism, others to the syndrome itself, while some remain unexplained.

Treatment varies according to the diagnosis age, phenotype severity, and therapeutic objective. It involves a

multidisciplinary team, including primary care physicians, endocrinologists, surgeons, mental health professionals, geneticists, and infertility specialists. The most important long-term aspect of treating adolescent and adult patients with KS is testosterone therapy, which impacts sexual and musculoskeletal development[9, 10].

In Brazil, the syndrome is diagnosed relatively late[2]. The early diagnosis in the reported case raises the question of the benefits of initiating testosterone therapy early, considering the potential occurrence of androgen deficiency during the prenatal period and early childhood. There are three physiological peaks of androgen secretion in men: prenatal, the first four months of life, and adolescence[10]. Low-dose androgen treatment in childhood can assist with psychosocial functioning (anxiety, depression, and social issues) and behavior[11].

For prepubertal boys, orchidopexy is recommended between 6 and 12 months of age[12]. A general physical examination, including testicular, psychiatric, and neurological evaluations and measurements of LH and testosterone levels, should be conducted within the first three months of life if there may be a therapeutic benefit, for instance, in patients with micropenis[13]. Vitamin D and calcium levels and assessments of bone mineral status need to be performed every two years to initiate early treatment for osteoporosis[13]. Prepubertal patients should have regular anthropometric monitoring, including percentiles, standard deviation scores, determination of body proportions, and bone age, as a decrease in testosterone can increase body fat. Finally, speech therapy and psychotherapy are advised whenever necessary[13, 14].

However, even with an early diagnosis, KS is not treated until puberty, and no guidelines have been established to direct early treatment.

No specific treatment is currently being provided for the patient in question. He will continue to be monitored to ensure that the benefits of early diagnosis can inform further investigation and track comorbidities, which will help anticipate potential issues and enhance the prognosis[14].

CONCLUSION

Due to the lack of established protocols and specialists in the field, the few patients diagnosed early do not receive formal treatment, resulting in health risks along with consequences such as the comorbid conditions previously mentioned.

Early diagnosis and treatment can lead to extremely positive outcomes for patients with KS.

REFERENCES

1. Vozzi MSJ de, Corrado MP, Laureano LAF, Pereira CS, Pola L, Tavares ACT, et al. Correlação entre hipótese diagnóstica e diagnóstico citogenético da síndrome de Klinefelter. In: Congresso Brasileiro de Genética. Resumos. 2009; [citado 2023 Nov 17]. Disponível em: https://repositorio.usp.br/item/001784333.
2. Tincani BJ, Mascagni BR, Pinto RDP, Guaragna-Filho G, Castro CCTS, Sewaybricker LE, et al. Síndrome de Klinefelter: diagnóstico raro na faixa etária pediátrica. J Pediatr (Rio J) [Internet]. 2012 Jul; [citado 2023 Nov 17]; 88(4):323-7. DOI: https://doi.org/10.2223/JPED.2208. Disponível em: https://www.scielo.br/j/jped/a/C5HKCpZLLZWGB5MyjqyvZHn/.
3. Gravholt CH, Chang S, Wallentin M, Fedder J, Moore P, Skakkebaek A. Klinefelter Syndrome: Integrating Genetics, Neuropsychology, and Endocrinology. Endocr Rev 2018;39(4):389-423.
4. Zitzmann M, Aksglaede L, Corona G, Isidori AM, Juul A, T'Sjoen G, et al. European academy of andrology guidelines on Klinefelter Syndrome Endorsing Organization: European Society of Endocrinology. Andrology. 2021 Jan;9(1):145-67. DOI: https://doi.org/10.1111/andr.12909.
5. Kamischke A, Baumgardt A, Horst J, Nieschlag E. Características clínicas e diagnósticas de pacientes com suspeita de síndrome de Klinefelter. J Androl. 2003;24(1):41-8.
6. Okada H, Fujioka H, Tatsumi N, Kanzaki M, Okuda Y, Fujisawa M, et al. Síndrome de Klinefelter na clínica de infertilidade masculina. Hum Reprod. 1999;14(4):946-52.
7. Bojesen A, Juul S, Birkebaek NH, Gravholt CH. Morbidity in Klinefelter syndrome: a Danish register study based on hospital discharge diagnoses. J Clin Endocrinol Metab. 2006;91(4):1254-60.
8. Samplaski MK, Lo KC, Grober ED, Millar A, Dimitrimanolakis A, Jarvi KA. Phenotypic differences in mosaic Klinefelter patients as compared with non-mosaic Klinefelter patients. Fertil Estéril. 2014;101(4):950-5.
9. Rogol AD, Tartaglia N. Considerations for androgen therapy in children and adolescents with Klinefelter syndrome (47, XXY). Pediatr Endocrinol Rev. 2010 Dec;8(Suppl 1):145-50.
10. Bhasin S, Brito JP, Cunningham GR, Hayes FJ, Hodis HN, Matsumoto AM, et al. Testosterone Therapy in Men With Hypogonadism: An Endocrine Society Clinical Practice Guideline. J Clin Endocrinol Metab. 2018 May 1;103(5):1715-44. DOI: https://doi.org.br/10.1210/jc.2018-00229.
11. Flannigan R, Patel P, Paduch DA. Síndrome de Klinefelter. Klinefelter Syndrome. The Effects of Early Androgen Therapy on Competence and Behavioral Phenotype. Sex Med Rev. 2018;6(4):595.
12. Chan E, Wayne C, Nasr A, FRCSC para a Associação Canadense de Recursos Baseados em Evidências para Cirurgiões Pediátricos. Momento ideal da orquidopexia: uma revisão sistemática. Pediatr Surg Int. 2014;30(1):87-97.
13. Groth KA, Skakkebæk A, Høst C, Gravholt CH, Bojesen A. Clinical review: Klinefelter syndrome - a clinical update. J Clin Endocrinol Metab. 2013;98(1):20-30.
14. Ferlin A. Strategies to improve early diagnosis of Klinefelter syndrome. Expert Rev Endocrinol Metab. 2020 Nov;15(6):375-8. DOI: https://doi.org/10.1080/17446651.2020.1831912.