Residência RP Pediátrica
Publicação Oficial da Sociedade Brasileira de Pediatria
ISSN-Online: 2236-6814

Submitted on: 01/11/2024
Approved on: 03/13/2024

CASE REPORT

Pott's puffy tumor: a rare complication of a common pediatric disease

Caio Sousa Cortes[1], Paula Brandalise Nunes[1], Luana Deon Dulaba[1], Thayná Siqueira Lipienski[1], Adriano Keijiro Maeda[1], Rafaela Wagner[1]

Keywords:
Osteomyelitis, Streptococcal infections, Epidural abscess, Sinusitis.

Abstract

Introduction: Acute bacterial sinusitis is a common complication of upper respiratory tract infections in the pediatric age group in about 8% of cases. In some cases, it may evolve with intra and/or extracranial complications. **Objective:** The aim of this article is to report a case of a patient who developed a rare complication after sinusitis, called Pott's puffy tumor. **Case report:** 12-year-old male patient with a history of flu-like symptoms and fever for 3 months, developed daily headache with red flag signs, associated with a mass in the frontal region. Magnetic resonance imaging revealed an expansive formation in the extracranial plan of the mid frontal region, extending to the front ethmoidal region, eroding the cranial vault. He underwent surgical drainage of purulent secretion, in which was later identified *Streptococcus intermedius* in culture, corroborating to the diagnosis of Pott's puffy tumor. **Conclusion:** Although rare, sinusitis can progress with severe complications that require surgical intervention and broad-spectrum antimicrobial therapy.

[1] Hospital Infantil Pequeno Príncipe, Pediatria - Curitiba - Paraná - Brazil.

Correspondence to:
Caio Sousa Cortes
Hospital Infantil Pequeno Príncipe. Rua Desembargador Motta, 1070, Água Verde, Curitiba, PR, Brazil. CEP: 80250-060. E-mail: caiosousacortes@hotmail.com

Resid Pediatr. 2025;15(1). DOI: 10.25060/residpediatr-2025.v15n1-1216

This work is licensed under a Creative Commons Attribution 4.0 International License.

INTRODUCTION

Acute bacterial sinusitis is a common complication of upper respiratory tract infections in pediatric patients, accounting for approximately 8% of cases [1,2]. Although most patients respond favorably to antibiotic treatment, some children may develop intracranial complications such as meningitis, epidural abscess, subdural empyema, brain abscess, and cavernous sinus thrombosis. A less common extracranial complication is subperiosteal abscess of the frontal bone with osteomyelitis, which is called Pott's edematous tumor, after the neurosurgeon of the same name who first described it in 1760 [3].

The objective of this paper is to present a case report of a patient with Pott's edematous tumor.

CASE REPORT

A 12-year-old male patient, previously healthy, was admitted to the emergency room of a tertiary pediatric hospital.

About three months ago, he began with upper respiratory symptoms associated with fever. Subsequently, the child developed a daily headache of increasing intensity until he had "the worst headache of his life" the day before the consultation. In addition, the child reported waking up at night due to pain, with sporadic nausea and vomiting during the period. Two months earlier, he had already been seen by a neurologist, who made a clinical diagnosis of migraine due to a positive maternal family history, but the patient had no photophobia and no phonophobia. Subsequently, the child developed a mass in the frontal region of the skull, well outlined, without inflammatory signs, of soft consistency (figure 1). Upon physical examination, no other alterations were found besides the mass already described, and the neurological examination was within normal limits.

Initial laboratory tests detected lymphopenia, with negative evidence of inflammatory activity. A magnetic resonance imaging (MRI) scan of the skull showed an expansive formation with a lobulated appearance centered on the extracranial planes of the median frontal region, which extended to the fronto-ethmoidal region, eroding the locoregional cranial vault (figure 2). After evaluation by the neurosurgery team, drainage was performed in the surgical center, with a large amount of purulent secretion coming out of the frontal region, and the diagnostic hypothesis of Pott's tumor was then raised. In the culture collected from the abscess during surgery, there was growth of the bacteria Streptococcus intermedius and the biopsy showed conjunctival tissue with edema and histiocytic infiltrate, associated with plasma cells, neutrophils, lymphocytes and multinucleated giant cells.

The patient progressed well clinically after drainage, with complete relief of pain. He received antibiotic therapy



Figure 1. Patient with tumor in the frontal region of the face.

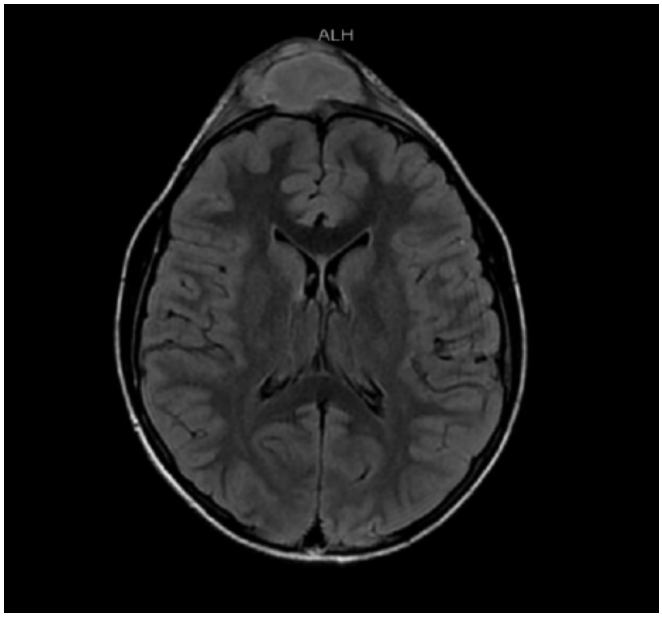

Figure 2. Expansive formation with a lobulated appearance in the extracranial plane of the frontal region with contrast enhancement on T2 with an approximate volume of 15.4 cm^3.

with cefepime, vancomycin and metronidazole for 29 days. After this period, he underwent a new MRI of the skull, which showed no residual component. During hospitalization, he was also evaluated by the immunology team, and after performing additional tests, he was found to have lymphopenia and hypocomplementemia, in addition to a poor response to vaccination. At that time, due to the severity of the infection, it was not possible to differentiate whether the immunodeficiency was primary or secondary, and he was referred for outpatient follow-up, with prophylactic use of amoxicillin and recommendation not to administer live attenuated virus vaccines until further notice.

DISCUSSION

Complications of acute bacterial sinusitis of the frontal sinus may result from embolic and/or contiguous dissemination. In the case reported, the patient not only developed dissemination through the thin anterior wall of the frontal sinus, but also erosion of the posterior wall. Invasion of the infection into the bone also results in associated osteomyelitis. The literature describes the association of Pott's edematous tumor with intracranial complications in up to 85% of cases [3,4].

The patient in this case presents epidemiological and clinical characteristics similar to those of other cases reported in the literature. The prevalence of the disease is higher in adolescents due to the increased blood circulation in the diploic veins of the frontal sinus in this age group, which facilitates hematogenous dissemination. The average age is 11 years and 70% of the affected individuals are boys [5]. The most common symptoms on admission of the reported patients are tense edema in the frontal region of the face, headache, fever, rhinorrhea and photophobia [6].

Surgical intervention, whether external or endoscopic, is the mainstay of treatment with the aim of draining the abscess and removing the bone with osteomyelitis and cannot be replaced by any antibiotic [5,7].

Regarding etiology, Streptococcus intermedius is a gram-positive, alpha-hemolytic coccus bacterium, a member of the Streptococcus anginosus group (SAG), which also includes S. anginosus and S. constellatus. Because it has hydrolytic enzymes, it is responsible for the formation of pus and tissue liquefaction. These bacteria are part of the normal microbiota of the respiratory, gastrointestinal and genitourinary tracts. S. intermedius, one of the most prevalent bacteria in brain abscesses and head and neck infections, is commonly identified in cases of Pott's tumor [6]. Patients with invasive disease caused by S. intermedius evolved with longer hospitalizations and higher mortality rates compared to other bacteria in the SAG group [8]. A review of 101 case reports between 1996 and 2019 indicates that the main symptoms on admission of patients who later tested positive for a site of infection for S. intermedius were intermittent fever and headache, and the main risk factors were a history of sinusitis and dental manipulation. The most used antibiotics were the combination of ceftriaxone, metronidazole, and vancomycin [8].

A review of 95 cases of patients whose cultures identified SAG at Children's Texas Hospital between 2011 and 2018 indicated a mean age of 11.4 years, males (66%), and the most isolated bacterium was S. intermedius (80%). Of these patients, 15.5% had Pott's tumor and more than 80% of the bacteria in the SAG group isolated were sensitive to penicillin [9]. Despite this, studies support the association of antibiotics that penetrate the blood-brain barrier from the beginning of treatment, such as ceftriaxone and vancomycin, with the aim of covering other associated pathogens. Anaerobic bacteria and Staphylococcus aureus, for example, are some of the most isolated agents in polymicrobial cultures [7,9,10]. Although there is no consensus, the average time of antibiotic therapy was 28 days [11].

Although a rare complication, Pott's Edematous Tumor should be considered in all children with a mass in the frontal region associated with a recent history of respiratory symptoms. Complementary investigation with cranial MRI is essential to better study the extent of the infection and treatment should be invasive, with drainage in a surgical center, associated with broad-spectrum antibiotic therapy for a prolonged period.

REFERENCES

1. Demuri GP, Gern JE, Moyer SC, Lindstrom MJ, Lynch SV, Wald ER. Clinical Features, Virus Identification, and Sinusitis as a Complication of Upper Respiratory Tract Illness in Children Ages 4-7 Years. J Pediatr. 2016;171:133-9.e1.
2. Sociedade de Pediatria de São Paulo (SPSP), Departamento de Otorrinolaringologia, Departamento de Reumatologia. Recomendações: atualização de condutas em pediatria. São Paulo: Dezembro 2013;67.
3. Blumfield E, Misra M. Pott's puffy tumor, intracranial, and orbital complications as the initial presentation of sinusitis in healthy adolescents, a case series. Emerg Radiol. 2011;18(3):203-10.
4. Costa L, Mendes Leal L, Vales F, Santos M. Tumor edematoso de Pott: rara complicação da sinusite. Braz j otorhinolaryngol (Impr). 2020;86(6):812-4.
5. Koltsidopoulos P, Papageorgiou E, Skoulakis C. Pott's puffy tumor in children: A review of the literature. Laryngoscope. 2020;130(1):225-31.
6. Tibesar RJ, Azhdam AM, Borrelli M. Pott's Puffy Tumor. Ear Nose Throat J. 2021;100(Suppl 6):870S-2S.
7. Kühn JP, Linsler S, Nourkami-Tutdibi N, Meyer S, Becker SL, Yilmaz U, et al. Pott's puffy tumor: a need for interdisciplinary diagnosis and treatment. HNO. 2022;70(Suppl 1):8-13.
8. Issa E, Salloum T, Tokajian S, Costa L, Mendes Leal L, Vales F, et al. From Normal Flora to Brain Abscesses: A Review of Streptococcus intermedius. Front Microbiol. 2020;11(6):1-12.
9. McNeil JC, Dunn JJ, Kaplan SL, Vallejo JG. Complications of Otitis Media and Sinusitis Caused by Streptococcus anginosus Group Organisms in Children. Pediatr Infect Dis. 2020;39(2):108-13.
10. Issa E, Salloum T, Tokajian S. From Normal Flora to Brain Abscesses: A Review of Streptococcus intermedius. Front Microbiol. 2020;11:1-12.
11. McNeil JC, Dunn JJ, Kaplan SL, Vallejo JG. Complications of Otitis Media and Sinusitis Caused by Streptococcus anginosus Group Organisms in Children. Pediatric Infectious Disease Journal. 2020;39(2):108-13.