Residência RP Pediátrica
Publicação Oficial da Sociedade Brasileira de Pediatria

Submitted on: 10/28/2024
Approved on: 04/05/2025

CASE REPORT

Skin Eruption Mimicking Porokeratosis as a Component of a Rare Syndrome: CDAGS (Craniosynostosis, Deafness, Anal, Genitourinary, and Skin Anomalies) - A Case Report

Isabel Crivelatti[1], Gabriella Di Giunta Funchal[2], André Vinícius Vieira Maciel[1], Andrea Gisele Pereira Simoni[3]

Keywords:
Porokeratosis, Skin Manifestations, Craniosynostoses, Urogenital abnormalities, Anus, imperforate.

Abstract

Objective: This case report aims to detail the clinical findings of a rare congenital syndrome characterized by cutaneous manifestations, craniosynostosis, deafness and anomalies of the genitourinary and anal systems. It also intends to enhance awareness among medical professionals, facilitating the inclusion of this syndrome in clinical reasoning and differential diagnosis. **Case report:** A male newborn presented at birth with a set of clinical findings, including typical facies indicating craniosynostosis, genitourinary and anal malformations. Hearing screening test was altered. Performed chromosomal karyotype analysis and microarray were normal. By three months of age, the patient presented erythematous-scaly plaques with raised keratotic borders in the extremities, and underwent multiple topical and systemic treatments. By fourteen months of age, the infant exhibited clinical and histological characteristics of cutaneous lesions resembling porokeratosis. This skin presentation was subsequently correlated with other anomalies, resulting in a proposed diagnosis following a literature review. After diagnosis, empirical treatments were discontinued in favor of a multidisciplinary management approach. **Discussion:** The syndrome characterized by craniosynostosis, deafness, anal, genitourinary, and cutaneous abnormalities is a rare autosomal recessive disorder, with few cases documented in the literature. Cutaneous manifestations are commonly observed, with clinical and histological findings resembling porokeratosis. To avoid ineffective treatments and their side effects, as well as to facilitate timely multidisciplinary intervention, awareness of the constellation of signs and symptoms associated with this syndrome is essential for medical professionals. This knowledge enables them to consider the diagnosis and initiate prompt treatment for these infants, thereby improving their quality of life.

[1] Hospital Universitário da Universidade Federal de Santa Catarina (HU-UFSC), Serviço de Dermatologia - Florianópolis - Santa Catarina - Brazil.
[2] Hospital Universitário da Universidade Federal de Santa Catarina (HU-UFSC), Serviço de Patologia - Florianópolis - Santa Catarina - Brazil.
[3] Hospital Infantil Joana de Gusmão (HIJG), Serviço de Dermatologia Pediátrica - Florianópolis - Santa Catarina - Brazil.

Correspondence to:
Isabel Crivelatti.
Hospital Universitário da Universidade Federal de Santa Catarina (HU-UFSC). Rua Profa. Maria Flora Pausewang, Trindade, Florianópolis, SC, Brazil.
CEP: 88036-800. E-mail: isabel.crivelatti@gmail.com

Resid Pediatr. 2025;15(4). DOI: 10.25060/residpediatr-2025.v15n4-1359

Creative Commons. Attribution-NonCommercial-ShareAlike 4.0 International.

INTRODUCTION

CDAGS syndrome (craniosynostosis, deafness, anal, genitourinary, and skin anomalies) is a rare autosomal recessive condition, with few reports in the literature, characterized by craniosynostosis, delayed closure of the fontanelles, hearing loss, anal anomalies, genitourinary malformations, and porokeratosis.[1] Recent studies have shown an association between the syndrome and specific chromosomal regions; however, to date, the genes involved have not yet been identified.[2]

The cutaneous lesions are described as erythematous, scaly, reticulated plaques with well-defined borders and crusted surfaces, clinically and histologically resembling porokeratosis. Attention should be given to this dermatological presentation, as it is frequently associated with CDAGS syndrome, warranting consideration of this diagnostic hypothesis and further investigation of other characteristic clinical abnormalities. Genetic evaluation should also be considered in the diagnostic approach.[3]

The objective of this study was to describe the clinical findings, raise awareness about the existence of this disease, and emphasize the importance of including CDAGS syndrome among the differential diagnoses when encountering cutaneous involvement similar to porokeratosis associated with other typical features of the syndrome. Recognizing the disease and its clinical manifestations allows for timely diagnosis, avoiding ineffective treatments with potential side effects, and enabling early multidisciplinary follow-up and appropriate management, thereby improving the patient's condition and quality of life.

CASE REPORT

A full-term male newborn, delivered via cesarean section in December 2022, presented on his first physical examination with typical facial features (oblique palpebral fissures, hypertelorism, high and broad nasal bridge, posteriorly rotated ears with overfolded helix, carp-shaped mouth, high-arched palate, and retrognathia), craniosynostosis associated with turribrachycephaly, clinodactyly, hypospadias, bifid scarf scrotum, and imperforate anus. Additionally, the otoacoustic emissions test was abnormal bilaterally, and hearing loss was later confirmed by brainstem auditory evoked potentials (BAEP/BERA).

From birth to seven months of age, the patient underwent multiple surgical procedures to correct imperforate anus associated with an anorectal fistula, due to recurrent suture dehiscence as a postoperative complication. He also underwent surgical correction of craniosynostosis at five months of age. Karyotype analysis revealed no chromosomal abnormalities (46,XY). Complementary genetic analysis using comparative genomic hybridization (CGH) microarray showed no microdeletions or microduplications in the genetic material.

At three months of age, the child developed pruritic erythematous-scaly plaques with annular and confluent patterns on the limbs, dorsum of hands, and feet, sparing the palms, soles, and flexural areas. The mother noticed mild improvement of the lesions with sun exposure. Various topical corticosteroids and antibiotics were prescribed, as well as 3% salicylic acid ointment, with no visible improvement. The patient also received several systemic antibiotics, both orally and intravenously, requiring two hospitalizations solely for IV therapy. Hydroxyzine was prescribed to relieve itching, and chelated zinc was administered for a limited time due to suspected acrodermatitis enteropathica.

At 14 months of age, the child was referred for the first dermatology consultation. Examination revealed mild xerosis, nummular erythematous-squamous plaques with elevated keratotic borders and fine desquamation on the limbs, dorsum of hands, and feet. In addition, there was scalp hair thinning and absence of eyebrows and eyelashes (Figure 1). The patient was advised to apply moisturizing cream over the entire body two to three times daily and underwent an incisional skin biopsy.

Histopathology showed findings highly consistent with porokeratosis, including interface dermatitis, apoptotic keratinocytes, areas of dyskeratosis, hypergranulosis, and hyperkeratosis (Figure 2). Based on the biopsy results and subsequent literature review, the diagnosis of CDAGS syndrome was considered.

DISCUSSION

CDAGS syndrome is a rare autosomal recessive disorder, with its acronym proposed by Mendoza-Londono et al. (2005)[1]. The term summarizes the main signs and symptoms of the syndrome: craniosynostosis and clavicular hypoplasia (C); delayed closure of the fontanelle and, in some patients, deafness (D); anal anomalies, such as anal atresia and anterior ectopic anus (A); genitourinary malformations, such as hypospadias and urethrorectal fistula (G); and skin eruption, which in some cases may be classified as porokeratosis (S).[1,4]

Due to the rarity of the disease, only 13 cases from different geographic regions have been reported between 1981 and 2017. Although the inheritance pattern is consistent

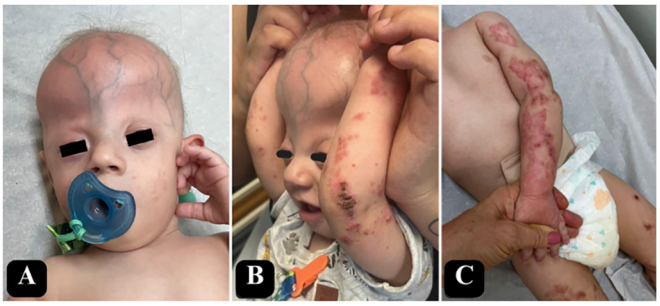

Figure 1. Photos of the patient at 14 months of age. A) Scalp hair thinning and absence of eyebrows and eyelashes. B) Typical facial features evident on inspection. C) Erythematous-squamous plaques with elevated keratotic borders and fine desquamation on the upper and lower limbs and dorsum of the hands.

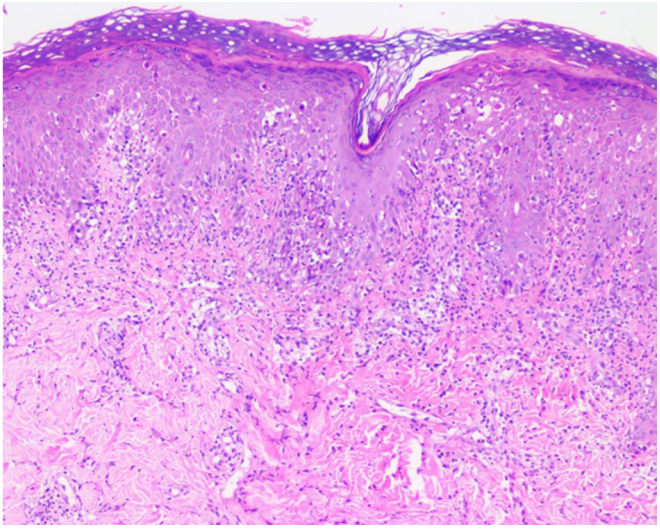

Figure 2. Histology showing typical features of parakeratosis, with interface dermatitis, apoptotic keratinocytes, hypergranulosis, and hyperorthokeratosis.

with an autosomal recessive condition, the specific causative genes have not yet been precisely identified.[5] Recent studies suggest a possible association with certain chromosomal regions, but to date, the genes involved in CDAGS syndrome remain unknown.[3]

Cutaneous manifestations are frequently present in CDAGS syndrome. Therefore, when skin lesions resembling porokeratosis are observed, other clinical alterations—such as craniosynostosis, delayed fontanelle closure, genitourinary malformations, and anal anomalies—should be promptly investigated for early diagnosis. Diagnostic delay results in significant distress for families and is associated with preventable morbidity. Early diagnosis enables more appropriate therapeutic decisions, such as timely surgical correction of malformations, reducing complications from late diagnosis and improving the prognosis of affected individuals. In the reported case, for instance, early surgical management of craniosynostosis and imperforate anus prevented complications such as intracranial hypertension and fistula formation, respectively.

The skin lesions are primarily described as erythematous, scaly plaques and papules, pleomorphic, with well-defined, raised, keratotic borders, resembling porokeratosis, and may exhibit hemorrhagic crusts, as in our patient.[2,4] Scalp alopecia and absence or thinning of eyebrows and eyelashes are also described in CDAGS syndrome, both of which were observed in our case.[2]

Histologically, CDAGS syndrome is also similar to porokeratosis, showing focal vacuolar degeneration of the basal layer and areas of dyskeratosis.[3] It is still unclear whether the skin lesions in CDAGS syndrome represent true porokeratosis or merely porokeratosis-like manifestations. We consider that such lesions may be better classified within the current group of keratinizing autoinflammatory diseases, which includes porokeratosis and chronic lichenoid keratosis—conditions that share a lichenoid tissue response pattern associated with keratinization disorders. Although histologically similar, their behavior differs: cutaneous lesions in CDAGS syndrome tend to improve with sun exposure, whereas porokeratosis lesions characteristically worsen with ultraviolet light.[6,7]

The rarity of the syndrome contributes to delayed diagnosis and consequently to ineffective therapeutic attempts. Conditions such as imperforate anus or anorectal fistula can be surgically corrected and are generally addressed early.[4] In cases of coronal craniosynostosis, surgical correction is recommended between 6 and 9 months of age to correct cranial deformity and prevent intracranial hypertension. Additional procedures, such as fat grafting to the craniofacial skeleton to minimize asymmetries and ptosis correction, may also be necessary.[2,3,8] Regarding the skin lesions, several treatments are often prescribed due to lack of an accurate diagnosis, including topical and systemic corticosteroids, antibiotics, antifungals, systemic retinoids, and zinc or biotin supplementation, typically without success. Non-pharmacological management, particularly daily skin hydration, is essential to maintain skin barrier integrity, prevent secondary infections, and reduce penetration of allergens and irritants.[2] Management of skin lesions should also include treatment of secondary infections when present, and skin surveillance due to the potential risk of squamous cell carcinoma, as observed in porokeratosis.[7]

Due to the small number of reported cases, CDAGS syndrome remains a diagnostic challenge. As part of the diagnostic approach, genetic evaluation should always be

considered. Although some studies have demonstrated potential chromosomal associations, the exact causative genes have not yet been identified. Therefore, further research is required to elucidate its etiology. Finally, aiming to expand awareness and reinforce the recognition of this rare condition among the medical community, we report the case of a patient with the main clinical features encompassed by the CDAGS acronym, highlighting the cutaneous manifestations, which are almost invariably present. Although certain malformations, such as anal anomalies, can be surgically corrected, other non-surgical manifestations, particularly skin lesions, negatively impact quality of life. Thus, early detection of the syndrome allows for timely interventions, improving clinical outcomes and patient well-being.

REFERÊNCIAS

1. Mendoza-Londono R, Lammer E, Watson R, Harper J, Hatamochi A, Hatamochi-Hayashi S, et al. Characterization of a new syndrome that associates craniosynostosis, delayed fontanel closure, parietal foramina, imperforate anus, and skin eruption: CDAGS. Am J Hum Genet. 2005;77(1):161-8. DOI: https://doi.org/10.1086/431654.
2. Pastrana-Ayala R, Peña-Castro GL, Valencia-Herrera AM, Mena-Cedillos CA, Toussaint-Caire S, Akaki-Carrño YI, et al. Craniosynostosis, delayed closure of the fontanelle, anal, genitourinary, and skin abnormalities (CDAGS syndrome): first report in a Mexican patient and review of the literature. Int J Dermatol. 2017;56(4):435-9. DOI: https://doi.org/10.1111/ijd.13504.
3. Xing C, Kanchwala M, Rios JJ, Hyatt T, Wang RC, Tran A, et al. Biallelic variants in RNU12 cause CDAGS syndrome. Hum Mutat. 2021;42(8):1042-52. DOI: https://doi.org/10.1002/humu.24239.
4. Chouery E, Guissart C, Mégarbané H, Aral B, Nassif C, Thauvin-Robinet C, et al. Craniosynostosis, anal anomalies, and porokeratosis (CDAGS syndrome): case report and literature review. Eur J Med Genet. 2013;56(12):674-7. DOI: https://doi.org/10.1016/j.ejmg.2013.09.012.
5. Cohen-Sors R, Devauchelle B, Vabres P, Jain M, Demeer B, Carmi E. Syndrome CDAGS (craniosténose, surdité, anomalie anale et génito-urinaire avec éruption cutanée) [CDAGS syndrome (craniostenosis, deafness, anal abnormalities and genitourinary malformations with skin rash)]. Ann Dermatol Venereol. 2020;147(12):868-72. DOI: https://doi.org/10.1016/j.annder.2020.10.016.
6. Blicharz L, Czuwara J, Rudnicka L, Torrelo A. Autoinflammatory Keratinization Diseases-The Concept, Pathophysiology, and Clinical Implications. Clin Rev Allergy Immunol. 2023;65(3):377-402. DOI: https://doi.org/10.1007/s12016-023-08971-3.
7. Taylor A, Nguyen RH, Glass DA 2nd, Agim NG. JAAD Grand Rounds. Annular plaques and craniosynostosis. J Am Acad Dermatol. 2013;68(5):881-4. DOI: https://doi.org/10.1016/j.jaad.2011.12.005.
8. Ghizoni E, Denadai R, Raposo-Amaral CA, Joaquim AF, Tedeschi H, Raposo-Amaral CE. Diagnosis of infant synostotic and nonsynostotic cranial deformities: a review for pediatricians. Rev paul pediatr. 2016;34(4):495-502. DOI: https://doi.org/10.1016/j.rppede.2016.02.005.