Residência RP Pediátrica
Publicação Oficial da Sociedade Brasileira de Pediatria
ISSN-Online: 2236-6814

Submitted on: 12/23/2025
Approved on: 04/02/2025

CASE REPORT

Primary hyperparathyroidism due to parathyroid adenoma in a pediatric patient: a case report

Paola R. F. Suhet[1,2], Claudia A. Polloni[1,2], Leandro A. Barros[3], Antônio Bertelli[3], Paula B. Cunha[4], Matheus A. Alvares[4]

Keywords:
Hyperparathyroidism,
Hyperparathyroidism, primary,
Hypercalcemia,
Pediatrics.

Abstract

Primary hyperparathyroidism (PHPT) in childhood is a rare condition of extreme clinical importance. The anomalous increase in the activity of the parathyroid gland, leading to inappropriate production of parathyroid hormone (PTH), results in an imbalance in calcium metabolism, leading to direct impacts on bone development and the renal system. The aim of this article is to report a case of PHPT due to parathyroid adenoma in a 13-year-old girl in which the only clinical manifestation was renal lithiasis. Laboratory analysis showed calcium up to 14.8 md/dL and parathyroid hormone up to 305 pg/mL. The patient underwent surgical removal of the adenoma with intraoperative PTH measurements showing a drop of more than 80% in serum hormone values ??after the excision of one of the glands.

[1] Hospital Infantil Sabará, Pediatria - São Paulo - São Paulo - Brazil.
[2] Instituto PENSI - São Paulo - São Paulo - Brazil.
[3] Hospital Infantil Sabará, Cirurgia de Cabeça e Pescoço - São Paulo - São Paulo - Brazil.
[4] Hospital Infantil Sabará, Endocrinologia Pediátrica - São Paulo - São Paulo - Brazil.

Correspondence to:
Paola R. F. Suhet.
Hospital Infantil Sabará. Av. Angélica, 1987 - Consolação, São Paulo - SP, 01227-200. E-mail: romanisuhet@gmail.com

DOI: 10.25060/residpediatr-2025.v15n4-1385
Creative Commons. Attribution-NonCommercial-ShareAlike 4.0 International.

INTRODUCTION

Primary hyperparathyroidism (PHPT) is typically an adult disease, most common between the fourth and sixth decades of life, with a predominance in postmenopausal women[1,2]. In children and adolescents, its prevalence is estimated at 2 to 5 cases per 100,000 individuals[3]. The most common causes of PHPT in the pediatric population include sporadic parathyroid adenomas, glandular hyperplasia, and, less frequently, parathyroid carcinoma. Genetic syndromes, such as multiple endocrine neoplasia type 1 (MEN1) and type 2A (MEN2A), are also associated with this condition. Although rare in the pediatric population, PHPT may present as an early-onset form similar to the typical adult presentation. Understanding its epidemiology is essential for the early identification of risk factors and clinical patterns, enabling timely diagnosis and appropriate disease management.

The pathophysiology of PHPT involves inappropriate regulation of parathyroid hormone (PTH) secretion by the parathyroid glands, leading to chronically elevated serum calcium levels secondary to increased renal, intestinal, and bone calcium reabsorption, as well as phosphaturia, resulting in hypophosphatemia. This leads to alterations in bone and kidney tissues, with significant clinical consequences. In addition to nephrolithiasis, neuromuscular symptoms, constipation, and psychiatric manifestations, pediatric patients may present with growth delay, bone pain, muscle weakness, fatigue, polyuria, polydipsia, and, in severe cases, neurological symptoms such as lethargy, confusion, and seizures[1].

Clinical diagnosis of PHPT in childhood is often challenging, as symptoms may be nonspecific and 80% of patients may be asymptomatic[3]. In a patient with hypercalcemia, normal renal function, and elevated PTH levels, the diagnosis of PHPT is established. Imaging studies requested to continue diagnostic investigation include cervical ultrasonography, which may reveal gland enlargement, and parathyroid scintigraphy, which confirms increased glandular activity by identifying the diseased gland. Early diagnosis of PHPT prevents the progression of complications secondary to abnormalities in calcium and phosphorus metabolism, ensuring lower morbidity in the pediatric population. The patient described here was minimally symptomatic but arrived at our service with a history of previous surgical interventions due to nephrolithiasis resulting from delayed diagnosis.

CLINICAL CASE

A 13-year-old female patient with a history of nephrolithiasis was referred to the pediatric emergency department due to elevated total calcium levels found in laboratory tests requested for the investigation of renal lithiasis. She denied asthenia, fatigue, malaise, respiratory or gastrointestinal symptoms. She also denied pathological fractures, bone pain, and other concomitant diseases.

Physical examination showed no abnormalities, including cervical palpation, which revealed no nodules or other findings. Among the laboratory tests obtained at admission, the corrected serum calcium level was notably elevated at 14.4 mg/dL, and PTH was 282.5 pg/mL, more than 10 times above the upper limit of normal. Additional laboratory tests were requested for diagnostic investigation, including measurement of phosphorus and 25-OH vitamin D, given the association between PHPT and hypophosphatemia and hypovitaminosis D[4]. These and the remaining laboratory results are presented in Table 1.

A cervical ultrasound was performed, which showed nodular images located along the posterior aspect of the middle third of the right lobe and near the inferior pole of the left lobe. Subsequently, the patient underwent a parathyroid scintigraphy, which confirmed persistent radiopharmaceutical uptake in the projection of the lower third of the left thyroid lobe, corresponding to the nodular image near the inferior left pole observed on the ultrasound.

While awaiting scintigraphy to define the surgical approach, hypercalcemia was managed with a loop diuretic (Furosemide), intravenous hyperhydration, and a bisphosphonate (Pamidronate). The progression of serum calcium levels is shown in Graph 1.

The patient underwent surgical treatment for hyperparathyroidism with resection of the left inferior parathyroid gland (Figure 1). Intraoperative PTH levels showed a reduction of more than 80% in serum hormone values after excision of the gland; these values are presented in Table 2.

DISCUSSION

Primary hyperparathyroidism (PHPT) is a rare condition in childhood, with an estimated incidence of 2 to 5 cases per 100,000 children[3]. It is characterized by excessive secretion of parathyroid hormone (PTH) by the parathyroid glands, leading to hypercalcemia and its systemic consequences[1,3].

In children, PHPT presents with a wide range of clinical manifestations, from mild and nonspecific symptoms to severe conditions. Common symptoms include bone pain, muscle weakness, fatigue, polyuria, polydipsia, and constipation[3,4]. In more severe cases, neurological symptoms such as lethargy, confusion, and, in extreme situations, seizures may occur[3]. In this patient, renal lithiasis was the initial finding that prompted further investigation and ultimately led to the diagnosis.

Table 1: Patient's laboratory tests at admission.

Test	Method	Result	Reference Value
Total Calcium	Colorimetric	14.4 mg/dL	8.8-10.7
Ionic Calcium	Potentiometry	1.77 mmol/L	1.16-1.32
PTH	Chemiluminescence	282.5 pg/Ml	18.5-88
25-OH-Vitamin D	Chemiluminescence	7.3 mmol/L	19.9-79.3
Phosphorus	Colorimetric	2.9 mg/dL	3-5.4

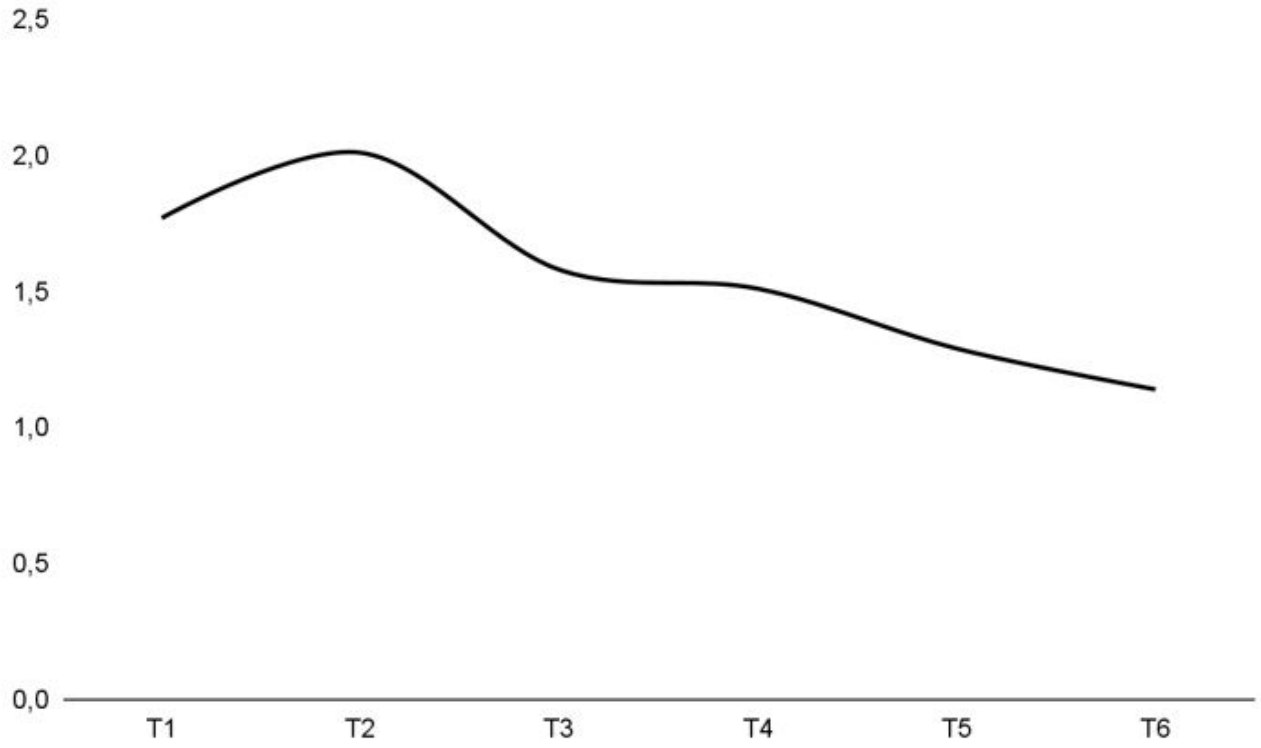

Graph 1. Ionized calcium values throughout hospitalization in nmol/L on the Y-axis. The X-axis shows the time points from hospital admission — (T1) Admission; (T2) Pre-bisphosphonate administration; (T3) 48 hours after bisphosphonate administration; (T4) Preoperative; (T5) 24 hours postoperative; (T6) Hospital discharge.

The diagnosis of PHPT in children is often challenging due to its rarity and the wide spectrum of symptoms that may mimic other conditions. Measurement of serum calcium and PTH is fundamental, confirming hypercalcemia associated with elevated PTH levels[1]. In the reported case, laboratory tests revealed persistent hypercalcemia and elevated PTH, suggesting PHPT. Subsequently, to differentiate nodular lesions from parathyroid hyperplasia, cervical ultrasound and technetium-99m sestamibi scintigraphy were performed, identifying a nodular image in the parathyroid gland[1,5]. Ultrasound is a noninvasive test useful for identifying gland enlargement, but parathyroid scintigraphy remains the exam of choice to confirm increased glandular activity[5,6].

PHPT may have several etiologies, including parathyroid adenomas, parathyroid hyperplasia, and, more rarely, parathyroid carcinoma[3,4]. Multiple endocrine neoplasia (MEN) syndromes — particularly MEN1 and MEN2A — are important etiological considerations, as both are associated with multiple endocrine tumors, including parathyroid adenomas that cause PHPT. MEN1 is caused by mutations in the MEN1 gene, whereas MEN2A is associated with mutations in the RET proto-oncogene[3,6]. Differential diagnoses for PHPT also include familial hypocalciuric hypercalcemia, caused by mutations in the calcium-sensing receptor gene, resulting in benign hypercalcemia, and granulomatous diseases such as sarcoidosis, which may cause hypercalcemia due to



Figure 1. A) Enlarged left inferior parathyroid gland observed intraoperatively. **B)** Parathyroid gland after surgical resection, measuring approximately 2.5 cm.

Table 2. Intraoperative PTH values.

Time	PTH (pg/mL)
Pre-anesthetic induction	265
Post-anesthetic induction	305
10 minutes after gland resection	44
20 minutes after gland resection	33.1

excessive calcitriol production. In this patient, the initial evaluation did not reveal symptoms suggestive of MEN or other complex etiologies. However, careful outpatient follow-up is crucial to monitor for late manifestations and to consider genetic testing if needed, particularly given the patient's age and the potential long-term impact. Follow-up will include periodic laboratory tests and clinical evaluations to ensure early detection of any complications or associated conditions, providing a comprehensive and individualized approach to PHPT management[4,6].

Management of PHPT in pediatric patients generally requires surgical intervention, with parathyroidectomy being the treatment of choice. This approach aims to remove the adenoma, normalize calcium and PTH levels, alleviate symptoms, and prevent long-term complications. Intraoperative PTH monitoring is highly effective for confirming complete removal of hyperfunctioning parathyroid tissue, resulting in high rates of calcium normalization and resolution of hyperparathyroidism symptoms[5,6,7]. This technique allows for a more precise and minimally invasive surgical procedure, reducing the need for extensive exploration and lowering recurrence rates[5]. Furthermore, the combined use of preoperative imaging and intraoperative PTH significantly improves clinical outcomes by increasing surgical accuracy and optimizing patient management.

It is also noteworthy that in the reported case, a single 60 mg dose of the bisphosphonate pamidronate was effective in providing temporary reduction of serum calcium levels while the patient awaited definitive surgical treatment[4,5].

FINAL CONSIDERATIONS

Early identification and accurate diagnosis are essential to prevent complications associated with PHPT, such as bone disorders, nephrolithiasis, and impaired development. This case reinforces the importance of maintaining a high clinical suspicion in children and adolescents who present with symptoms compatible with hyperparathyroidism, even though the condition is rare in this age group.

Parathyroidectomy proved to be an effective intervention for this patient, resulting in normalization of calcium and PTH levels and resolution of clinical symptoms. However, successful treatment depends on strict postoperative follow-up to monitor and manage potential complications, such as transient hypocalcemia.

Furthermore, this case highlights the importance of a multidisciplinary approach in the management of PHPT, involving endocrinologists, surgeons, radiologists, and other healthcare professionals. Collaboration among these specialties is essential to ensure accurate diagnosis, effective treatment, and adequate follow-up, providing the best possible outcomes for pediatric patients. Such coordinated care supports normal growth and development and allows for early detection of recurrence or late complications.

REFERENCES

1. Bilezikian JP, Brandi ML, Eastell R, Silverberg SJ, Udelsman R, Marcocci C, et al. Evaluation and management of primary hyperparathyroidism: summary statement and guidelines from the Fifth International Workshop. J Bone Miner Res. 2020;37(11):2293-314.
2. Madeira IR, Carvalho JR, Calliari LEP, Monterio AC, Kochi C. Hiperparatireoidismo primário associado a epifisiólise de cabeça do fêmur em adolescente. Arq Bras Endocrinol Metab. 2005;49(2):314-8.
3. Minisola S, Arnold A, Belaya Z, Bilezikian JP, Fukumoto S, Gafni RI, et al. Epidemiology, pathophysiology, and genetics of primary hyperparathyroidism. J Bone Miner Res. 2022;37(11):2315-26.
4. Walczyk A, Wójcik M, Krzyżaniak A, Borowińska J, Gosztyła K. Primary hyperparathyroidism: a rare endocrinopathy in children. Two case reports. Endokrynol Pol. 2011;62(4):346-50.
5. Tupchong L, Scuderi C, Sanders S, Romei C, Singh N, Fischer H, et al. Evaluation of the performance and clinical impact of a rapid intraoperative parathyroid hormone assay in conjunction with preoperative imaging and concise parathyroidectomy. World J Surg. 2014;38(5):1280-6.
6. Punchihewa GL, Nayak P, Bandarage GN, Seneviratne SA. Rare skeletal manifestations in a child with primary hyperparathyroidism: a case report. BMC Endocr Disord. 2017;17(1):45.
7. Bilezikian JP, Khan AA, Potts JT, Eastell R, Rejnmark L, Silverberg SJ, et al. Guidelines for the management of asymptomatic primary hyperparathyroidism: summary statement from the Fourth International Workshop. J Clin Endocrinol Metab. 2014;99(10):3561-9.