Residência RP Pediátrica
Publicação Oficial da Sociedade Brasileira de Pediatria

Submitted on: 01/29/2025
Approved on: 04/05/2025

CASE REPORT

IgM Nephropathy: A Steroid-Dependent Case with Management Challenges

Dora Pedroso Kowacs[1], Camille Midori Okuyama[1], Alexandre Marochi de Castro[2], Isabela Bertoncello[1], Ronaldo Martins Cravo[1], Karen Previdi Olandoski[3], René Scalet dos Santos Neto[4]

Keywords:
Immunoglobulin M, Nephrotic Syndrome, Drug Therapy, Immunosuppressive Agents.

Abstract

Objetive: Describe the case of a patient with steroid-dependence immunoglobulin M nephropathy treated with multiple immunosuppressant, levamisole, cyclophosphamide, cyclosporine, mycophenolate mofetil and rituximab, with frequent relapses and poor response to second line treatment, in an attempt to encourage the study this pathology and its treatment. **Case description:** A 18 months-old female presented with edema, high blood pressure, diarrhea, and perineal candidiasis. Investigations revealed significant proteinuria, hypertriglyceridemia, hypoalbuminemia, and positive Epstein-Barr virus serology. Initial treatment with dietary changes, diuretics, antihypertensives, and prednisolone led to partial remission but steroid dependence and relapses. Steroid-sparing agents, including levamisole, cyclophosphamide and rituximab showed limited benefit. A renal biopsy indicated mesangioproliferative nephritis with mild activity, chronicity and an immune pattern for immunoglobulin M at immunofluorescence. Treatment with mycophenolate mofetil and cyclosporine resulted in temporary improvement. Despite attempts to reduce steroids, patient continues with fluctuating proteinuria and recurrent nephrotic syndrome. **Comments:** This case highlights challenges in managing steroid-dependent immunoglobulin M nephropathy despite multiple immunosuppressants, underscoring the need for more effective treatments and long-term studies to guide therapy. Further research on steroid-sparing options and their efficacy in immunoglobulin M nephropathy is critical for improving patient outcomes.

[1] Universidade Positivo, Curso de Medicina - Curitiba - Paraná - Brazil.
[2] Faculdade Evangélica Mackenzie do Paraná, Curso de Medicina - Curitiba - Paraná - Brazil.
[3] Hospital Pequeno Príncipe, Departamento de Nefrologia Pediátrica - Curitiba - Parana - Brazil.

Correspondence to:
Dora Pedroso Kowacs.
Universidade Positivo. Rua Professor Pedro Viriato Parigot de Souza, 5300, Mossunguê, Curitiba, PR, Brazil. CEP: 81280-330. E-mail: d.pkowacs@gmail.com

DOI: 10.25060/residpediatr-2026-1413

Creative Commons. Attribution-NonCommercial-ShareAlike 4.0 International.

INTRODUCTION

Immunoglobulin M (IgM) nephropathy (IgMN), first described in 1978, is an idiopathic glomerulonephritis characterized by diffuse mesangial IgM deposits at immunofluorescence and variable histological finding at light microscopy, from minor changes to focal glomerulosclerosis.[1,2] Clinically, it presents as a nephrotic syndrome, asymptomatic proteinuria and/or isolated hematuria.[3-6] Prevalence ranges from 1.8% to 18.5% of kidney biopsies and mostly affects children and young adults.[1,3-5]

Although knowledge about IgMN´s pathogenesis is still scarce and controversial, several studies reveal a significant increase of IL-6 and IL-1 in renal tissue of patients with IgMN.[3,4,7] In vitro conditions, those proteins can stimulate mesangial cells to proliferate and secrete substances that may cause glomerular damage and sclerosis.[3] Functional abnormalities of both T lymphocytes and B cells might justify the increased production of IgM, which binds to injured glomeruli, activating the complement system amplifying renal damage.[2,4]

Steroids remain the main treatment, although resistance is found in 55-62% of the cases.[1,4] While no long-term effective treatment is known, alternative therapies, including calcineurin inhibitors, mycophenolate and rituximab are used in attempt to achieve better outcomes.[1,4] Even in the absence of clinical trials, the similarities between IgMN and other glomerulonephritis, such as minimal change disease and focal segmental glomerulosclerosis, supports the use of those alternative therapies in clinical practice.[3,4]

In attempt to encourage the study of IgM nephropathy, given the high prevalence of low response to steroids, the risk of chronic renal failure and the effect on young patients.[1,4] We describe the case of a patient with IgM dependence. IgM steroids treated with levamisole, cyclophosphamide, cyclosporine and mycophenolate mofetil and rituximab.

CASE REPORT

A 9-years-old female presented first symptoms of nephropathy at 18-months. At that time, she was hospitalized with generalized edema, high blood pressure, diarrhea and perineal candidiasis. Investigation revealed massive proteinuria (4+ protein on urinalysis), hypertriglyceridemia (295 mg/dL), hypoalbuminemia (1.7 g/dL), urine protein-creatinine ratio (UPCR) of 14.1 mg/mg and positive serology for Epstein Barr virus. She was treated with a low sodium diet, water restriction, diuretic, antihypertensive drugs, ganciclovir and antibiotics. After infection control, she was discharged with prednisolone 2 mg/kg/day, enalapril 1.35 mg/day and hydrochlorothiazide 12.5 mg.

Partial remission of proteinuria was initially achieved with steroid therapy however frequent relapses occurred during the following months, leading to steroid-dependence. Therefore, a switch to steroid-sparing drugs was pursue. Levamisole 2.5 mg/kg on alternative days for six months was prescribe, followed by cyclophosphamide 2 mg/kg/day, both with poor response. She suffered two episodes of nephrotic syndrome associated with flu. Three pulses of intravenous methylprednisolone 1g/dose were then administered, followed by cyclosporine 6 mg/kg/day.

At the age of three, renal biopsy was undertaken, revealing mesangioproliferative nephritis, presence of double contour and spicules in the glomerular basement membranes in 4 glomeruli, discrete chronic tubulo-intestitial, and discrete degenerative changes of the tubules, with 2/23 activity indices and 2/12 chronicity indices. At immunofluerescence, an immune pattern for IgA 1+/+++ and IgM 2+/+++. Consequently, mycophenolate mofetil 1200 mg/m²/day was introduce in association to prednisolone, cyclosporine and antihypertensive drugs.

Renal function improved and proteinuria was less frequent for a few months. From September of 2021 to May of 2022 UPCR and serum albumin levels fluctuated between 0.16 to 0.11 g/g and 3.6 to 2.9 g/dL, respectively, and protein on urinalysis was undetectable. Although, after trying to wean steroids, the patient suffered frequent relapses. Despite the further increase of prednisolone, in September of 2022 her urine protein-creatinine ratio was 22.3 mg/mg and she had been hospitalized over four times.

She suffered from nephrotic decompensation secondary to a) spontaneous bacterial peritonitis b) crusted impetigo associated with H3N2 respiratory infection, respiratory failure and acute pulmonary edema c) scabies d) pure nephrotic syndrome. At this stage, our plan was to use two doses of rituximab 375 mg/m²/each. Mycophenolate was withdrawn and one dose of rituximab was administered. Three weeks after infusion, her UPCR increased from 0.88 to 12.3 mg/mg and atopic dermatitis dramatically worsened. Therefore, her second dose of rituximab was avoid.

After that, no further attempts to change the immunosuppressant regime were undertaken, and she remains on use of prednisolone, cyclosporine, enalapril and amlodipine. Both lab results and decompensation episodes fluctuated over time, always worsening at attempts of dose reduction. Over the last two years, she suffered seven episodes of nephrotic syndrome that required albumin replacement and intravenous diuretic therapy. On 2023, all episodes were associated with flu. She continues proteinuric (2+ to 3+ protein on urinalysis), with UPCR and serum albumin levels varying from 0.08 to 8.31 g/g and 1.6 to 4.6g/dL, respectively.

In light of prolonged exposure to high doses of corticosteroids, the patient continues to undergo regular ophthalmological and radiological surveillance, including evaluation of long bones, showing no abnormalities to date. Despite the corticosteroid´s influence on increased blood pressure and elevated triglyceride levels, the patient's hypertension and hypertriglyceridemia are more likely attributable to an underlying condition.

DISCUSSION

This is the first Brazilian report of a patient with the diagnosis of IgM nephropathy treated with several immunosuppressant. There are few studies about IgMN published and most of the reports in the literature are from Asia, Europe and North America.[5,7-12]

Along with literature, our patient presented nephrotic syndrome as a first manifestation. Other clinical manifestations include high blood pressure, hematuria and proteinuria, were present in our case.[1,2,13]

Currently, oral steroids are the first line treatment for IgMN, though response is frequently poor.[4] Proportion of steroid-resistant (SR) and steroid-dependent (SD) cases varies considerably among the studies. Over 28% patients were SR and 36% were SD in a Finnish study, while in a Colombian report this frequency was around 38% and 8%, respectively.[4,5] The highest SR rate was 66%, reported by Mokhtar.[6]

Second line treatments are immunosuppressant, such as cyclosporine, cyclophosphamide, tacrolimus, mycophenolate and, more recently, rituximab.[9,11] In the past years, several reports showed successful treatment of IgMN with rituximab.[5,8,11,14] Therapeutic approaches differ from each study (table 1).

In our case, after dependence to first line treatment, alternative drugs were introduce. First, levamisole 2.5 mg/kg on alternate days, followed by cyclophosphamide 2 mg/kg/day. Since no remission was achieve, the patient underwent three pulses of methylprednisolone 1 g/dose, followed by cyclosporine 6 mg/kg/day and mycophenolate mofetil 1200 mg/m²/day divided in two doses. After two years of unsuccessful treatment, mycophenolate was switch to rituximab 375 mg/m²/dose. Different from several reports, our patient worsened renal function and had a dramatic side effect after the first infusion of rituximab.

Clinical course and prognosis of IgMN are variable due to the lack of long-term studies. Decrease of renal function is highly reported, with kidney failure and end-stage renal disease rate varying from 4-23%.[2,4] In a 15 years follow-up study, renal failure occurred in 35% of cases and ESRD in 23%.[15] Proteinuria and hypertension are consider predicting factors.[1,2,15] Those factors are present in our case. Since nephropathy symptoms onset, continuous use of two antihypertensive drugs from different classes and high steroid doses were necessary for blood pressure and proteinuria control.

Throughout the time of follow-up, our patient used five different steroid-spare drugs, had no response to levamisole and cyclophosphamide, worsened with rituximab and remained steroid-dependent with cyclosporine. The key events and drugs records are represented in figure 1.

Long term high dose steroids can lead to several side-effects, especially in pediatric patients. Growth retardation, weight gain, adrenal dysfunction and increased susceptibility to infection are some examples.[4] To avoid those potential harms, it is important to reduce steroids dose or to switch it for other drugs. This study reported a case in which no immunosuppressant was able to replace steroids used to

Table 1. Second-line therapies.

Patient Information	Therapeutic Approach	Outcome	Ref
26-year-old male	Cyclophosphamide, cyclosporine, peritoneal dialysis and kidney transplant. After recurrence in the kidney transplant: Methylprednisolone 1g three pulses IV followed by 375 mg/m²/month for 2 months.	One year of remission. Kidney biopsy with no mesangial deposits of IgM	Betjes MCG, et al.[8]
1-year-old male	Cyclosporine A for a year followed by rituximab 375 mg/m²/week for 2 weeks with mycophenolate mofetil 20 mg/kg/day	Two years of remission	Gu Ja, et al.[9]
3-year-old female	Tacrolimus 87 ug/kg/day for 15 months, followed by rituximab 375 mg/m²/week for 2 weeks, followed by mycophenolate mofetil 17.5 mg/kg/day	Two years of remission	Gu Ja, et al.[9]
23-year-old male	Cyclosporine 200-250 mg/day for several months followed by rituximab 1g/month for 2 months	One year of remission	Downie E, et al.[5]
30-year-old female	Methylprednisolone 750 mg/day three pulses IV followed by cyclophosphamide 500 mg/m² every 3 weeks followed by rituximab 375 mg/m²/week for 4 weeks followed by cyclosporine and tacrolimus	Remission	Park KS, et al.[14]
27-year-old male	Cyclophosphamide followed by cyclosporine 5 mg/kg/day	Remission	Gurova GA, et al.[10]
59-year-old male	Rituximab 1g for two months.	Remission	Almed FA, et al.[12]
40-year-old male	Mycophenolate mofetil 1.5 g/day for 6 months followed by cyclophosphamide 2 mg/kg/day for 4 months followed by rituximab 1 g/month for 2 months.	One year of remission	Faroque O, et al.[11]

Legends: g: grams; mg: milligrams; ug: micrograms; m^2: square meters; kg: kilograms; Ref: references.

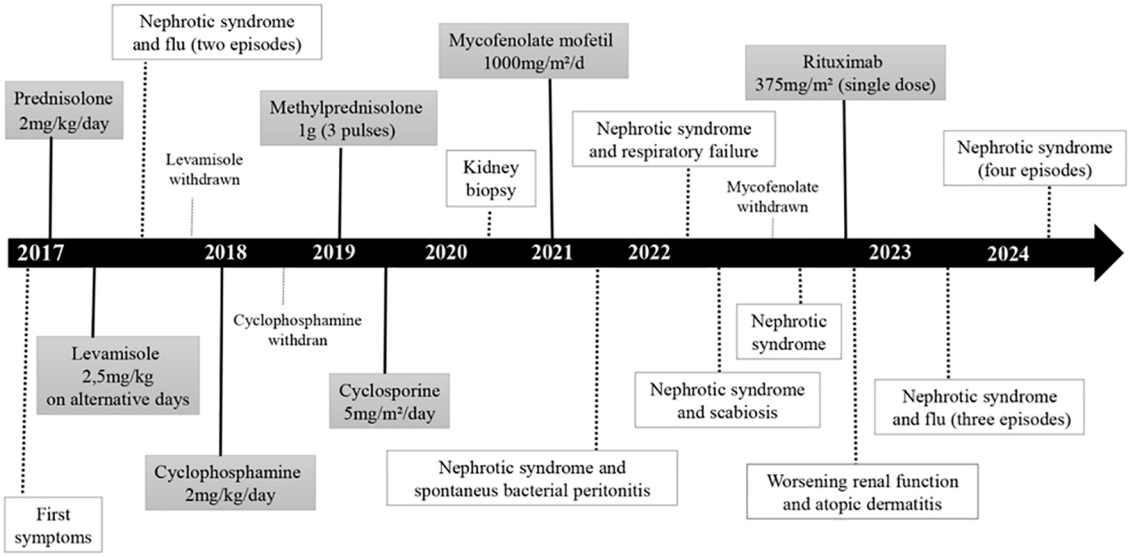

Figure 1. Timeline of key events.

treat IgMN. However, current literature cites many cases where those drugs were efficient in maintaining remission of nephropathy.[11,12] Therefore, the use of steroid-spare drugs such as levamisole, cyclophosphamide, cyclosporine and mycophenolate mofetil and rituximab in patients with IgM nephropathy should be better evaluate with long-term studies and clinical trials.

REFERENCES

1.Chae Y, Yoon HE, Chang YK, Kim YS, Kim HW, Choi BS, et al. Renal outcome of IgM nephropathy: A comparative prospective cohort study. J Clin. Med. 2021;10:4191. https://doi.org/10.3390/jcm10184191

2. Mubarak M, Kazi JI. IgM nephropathy revisited. Nephro-Urol Mon. 2012;4(4):603-8 https://doi.org/10.5812/numonthly.2805

3. Chen WP, Lin CY. Augmented expression of interleukin-6 and interleukin-1 genes in the mesangium of IgM mesangial nephropathy. Nephron 1994;68:10-9. https://doi.org/10.1159/000188217

4. Arias LF, Prada MC, Velex-Echeverri C, Serna-Higuta LM, Serrano-Gayubo AK, Ochoa CL, et al. IgM nephropathy in children: clinicopathologic analysis. Nefrologia; 2013;33(4):532-8.

5. Downie E, Diep J, Sungala N, Wong J. IgM nephropathy complicated by cerebral venous sinus thrombosis: a case study. BMC Nephrology. 2020;21:390. https://doi.org/10.1186/s12882-020-02048-5

6. Mokhtar GA. IgM nephropathy: clinical picture and pathological findings in 36 patients. Saudi J Kidney Dis Transpl. 2011;22(5):969-75.

7. Shakeel S, Mubarak M, Kazi JI, Lanewala. The prevalence and clinicopathological profile of IgM nephropathy in children with steroid-resistant nephrotic syndrome at a single centre in Pakistan. J Clin Pathol 2012;65:1072-76. https://doi.org/10.1136/jclinpath-2012-200933

8. Betjes MCG, Roodnat JI. Resolution of IgM nephropathy after rituximab treatment. Am J Kidney Dis. 2009;53(6):1059-62. https://doi.org/10.1053/j.ajkd.2008.10.038

9. Gu JA, Xia Y, Mao J, Fu H, Liu AM. Rituximab followed by mycophenolate mofetil in children with IgM nephropathy. Indian Pediatr. 2012;49:831-3. https://doi.org/10.1007/s13312-012-0168-4

10. Gurova DV, Chebotareva NV, Vinogradov AA, Stavrovskaya EV, Lysenko LV. Successful treatment of a rare variant of mesangioproliferative glomerulonephritis with IgM deposits with cyclosporin A. Therapeutic archive. 2020;92(6):73-5. https://doi.org/10.26442/00403660.2020.06.000673

11. Faroque O, Bari A, Islam SF, Hadiussaman KBM, Hossain EM, Islam MN. Rituximab in IgM nephropathy resistant to multiple immunosuppressives: A case report. Sch J Med Case Rep. 2022;10(12):1266-8. https://doi.org/10.36347/sjmcr.2022.v10i12.032

12. Ahmed FA, El-Meanaewy A. IgM nephropathy - Successful treatment with rituximab. Saudi J Kidney Dis Transpl. 2019;30(1):235-8. https://doi.org/10.4103/1319-2442.252917

13. Zeis PM, Kavazarakis E, Nakopoulou L, Moustaki M, Messaritaki A, Zeis MP, et al. Glomerulopathy with mesangial IgM deposits: Long-term follow up of 64 children. Pediatr Int. 2001;43:287-92. https://doi.org/10.1046/j.1442-200x.2001.01396.x

14. Park KS, Kang EW, Kie JH. A case report of immunoglobulin M nephropathy manifesting as crescentic glomerulonephritis and nephrotic syndrome in an adult. BMC Nephrology. 2019;20:335. https://doi.org/10.1186/s12882-019-1528-2

15. Myllymaki J, Saha H, Mustonen J, Helin H, Pasternack A. IgM nephropathy: Clinical picture and long-term prognosis. Am J Kidney Dis. 2003;41:343-50. https://doi.org/10.1053/ajkd.2003.50042