Residência RP Pediátrica
Publicação Oficial da Sociedade Brasileira de Pediatria
ISSN-Online: 2236-6814

Submitted on: 05/02/2025
Approved on: 06/02/2025

CASE REPORT

Granulomatosis with polyangiitis mimicking fungal infection: a case report

Alice Leite Mesquita[1], Marne Rodrigues Pereira Almeida[1], Caroline Graça de Paiva[1], Sarah Polyane Silva Veloso[1], Alanna Ferreira Alves[1], Silvana Augusta Jacarandá de Faria[2]

Keywords:
Granulomatosis with Polyangiitis.
Fusarium Infections.
Antibodies, Antineutrophil Cytoplasmic.
Case Reports.

Abstract

Granulomatosis with polyangiitis (GPA) is the main vasculitis associated with antineutrophil cytoplasmic antibody (ANCA), in which 12.4% of patients develop the disease before age 18. This study describes the case of a female adolescent with pulmonary and subcutaneous nodules initially attributed to infection by the fungus *Fusarium* spp. isolated in bronchial lavage culture. After extensive investigation, other organic lesions (upper airways, renal, bronchial) and ANCA antibodies were identified, corroborating the diagnosis of systemic vasculitis by the EULAR/PRINTO/PRES criteria 2010. This case report highlights the importance of suspecting the diagnosis of vasculitis in pediatric patients presenting systemic inflammation and multiorgan involvement of undetermined causes.

INTRODUCTION

Granulomatosis with polyangiitis (GPA), previously known as Wegener's granulomatosis, is a necrotizing small-vessel vasculitis typically associated with inflammatory granulomas, glomerulonephritis, upper and lower respiratory tract involvement, and the presence of anti-neutrophil cytoplasmic antibodies (ANCA)[1]. It is the main ANCA-associated vasculitis, with an incidence of 0.4 to 6.4 cases per 1,000,000 children in international cohorts from Europe and the United States[2].

Although rare, a Brazilian cohort showed that 12.4% of adults diagnosed with GPA had disease involvement during the pediatric age range[3], highlighting the importance of suspicion and recognition of the disease during childhood. The diagnosis is sometimes initially confused with more prevalent diseases (infectious, neoplastic, and otorhinolaryngological), so confirmation may occur late[4].

The aim is to report a case of GPA in an adolescent initially diagnosed as fusariosis. For this purpose, the classification criteria established by the European League Against Rheumatism (EULAR)/ Paediatric Rheumatology International Trials Organisation (PRINTO)/Paediatric Rheumatology European Society (PRES) in 2010 were used[5]. This study was approved under the Certificate of Presentation for Ethical Consideration (CAAE): 85703325.4.0000.0144.

[1] Hospital da Criança de Brasília, Reumatologia Pediátrica - Brasília - Distrito Federal - Brazil.
[2] Hospital da Criança de Brasília, Pneumologia Pediátrica - Brasília - Distrito Federal - Brazil.

Correspondence to:
Alice Leite Mesquita
Hospital da Criança de Brasília, Reumatologia Pediátrica - Brasília - Distrito Federal – Brazil. Av. L2 Sul, Quadra 608 Módulo a, Brasília, DF, 70203-900.
E-mail: aliceish@rocketmail.com / aliceleitemesquita@gmail.com

Resid Pediatr. 2026;16(2). DOI: https://doi.org/10.25060/residpediatr-2026-1472

Creative Commons. Attribution-NonCommercial-ShareAlike 4.0 International.

CASE DESCRIPTION

A previously healthy 13-year-old female patient was admitted to a pediatric intensive care unit (PICU) due to respiratory failure requiring mechanical ventilation. The patient had hemoptysis, progressive dyspnea, intermittent fever, and weight loss with onset 5 months earlier. There was a record of hospitalization at an outside hospital 2 months prior, with previous use of oxacillin, ceftriaxone, and cefepime, as well as a negative investigation for tuberculosis (nonreactive tuberculin skin test, smear microscopy, molecular rapid test—Xpert MTB/RIF—and negative fungal cultures from bronchoalveolar lavage [BAL]). In parallel with the prior hospitalization, an inflammatory nodule appeared in the left gluteal region, which was biopsied and treated with amoxicillin–clavulanate, without response.

At admission, chest computed tomography (CT) showed diffuse pulmonary nodules and mediastinal lymphadenopathy. Laboratory tests showed an elevated erythrocyte sedimentation rate (ESR) of 75 mm/h, C-reactive protein (19 mg/dL), leukocyte count of 14,670 cells/µL, and anemia (hemoglobin 10 mg/dL), normocytic and normochromic, with negative hemolysis tests and a negative direct Coombs test. Considering the possibility of fungal disease, liposomal amphotericin B, cefepime, levofloxacin, and sulfamethoxazole/trimethoprim were started empirically. Anti-HIV serology was negative, as were blood cultures for bacteria and fungi. Despite these negative results, given suspicion of septic embolism, an echocardiogram was performed and was normal.

After 10 days, the patient progressed with resolution of fever, a decrease in inflammatory markers, and tolerated extubation. Upon awakening, she complained of severe pain in the left lower limb and developed epistaxis. CT of the paranasal sinuses showed pansinusopathy. Due to suspected deep vein thrombosis (DVT), Doppler ultrasound of the affected limb did not detect DVT. Because of persistent pain, electromyography was requested and identified neuropathic involvement of the sciatic nerve, and gabapentin was prescribed. In addition, to complement diagnostic evaluation, magnetic resonance imaging (MRI) of the neuroaxis was performed and showed no abnormalities.

Once clinical stability was achieved, a new BAL was collected, with a second Xpert MTB/RIF test and galactomannan assay both negative. Direct mycological examination showed hyaline yeasts and, subsequently, fungal culture returned positive for *Fusarium* spp. Imaging evaluation of the gluteal region was indicative of infectious cellulitis associated with myositis of the right gluteus maximus (Figure 1), also attributed to probable fungal infection.

Approximately 40 days after admission, the patient was discharged with outpatient follow-up, receiving voriconazole and gabapentin. Two weeks later, she again developed hemoptysis and fever, requiring readmission. A new chest CT (Figure 2) showed diffuse bilateral cavitary lesions, and orbital MRI revealed right dacryocystitis causing mild proptosis, as well as sphenoid, maxillary, and ethmoidal sinus disease. Another bronchoscopy was performed, which identified thickening at the level of the carina and friable mucosa.

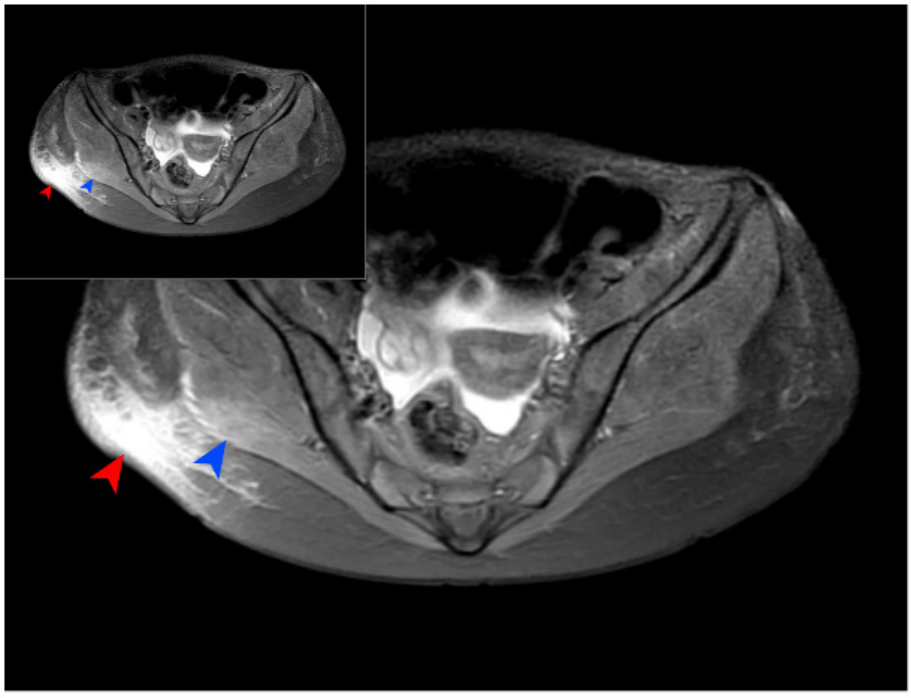

Figure 1. Axial MRI slice (SPAIR sequence) showing ill-defined subcutaneous enhancement (red arrow) extending to the region of the right gluteus maximus (blue arrow), consistent with cellulitis associated with myositis.

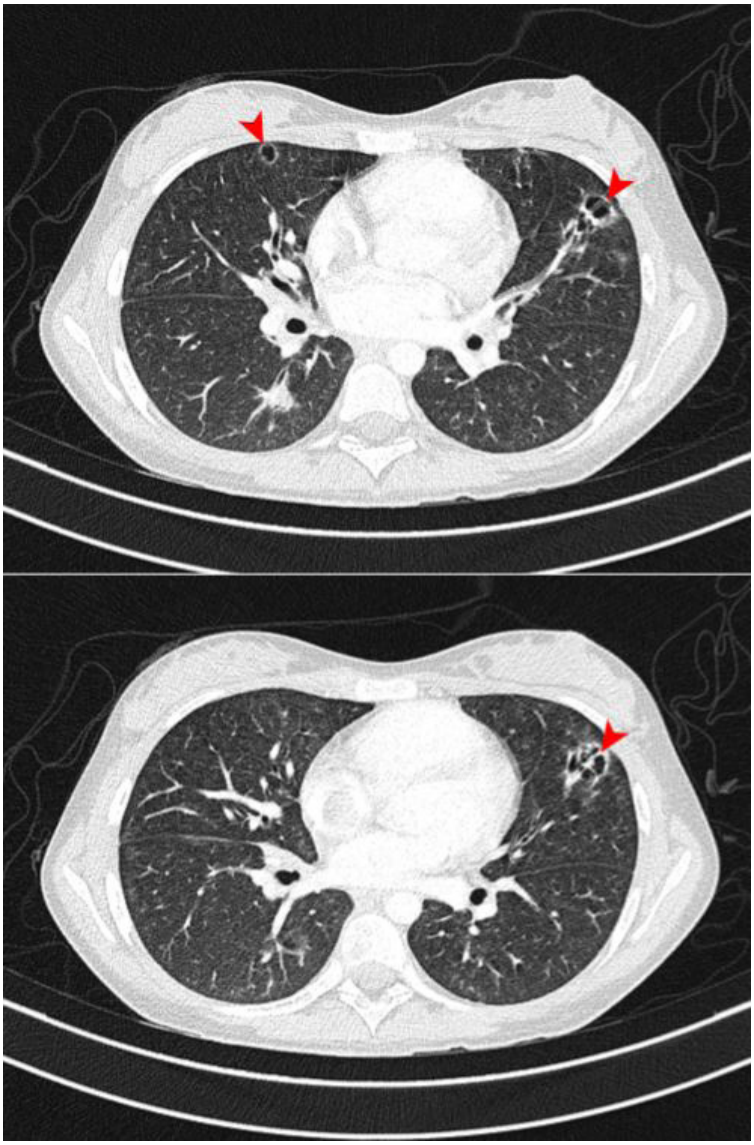

Figure 2. Axial chest CT images showing cavitated pulmonary nodules (red arrows).

To investigate alternative diagnoses, a rheumatology evaluation was requested after a positive p-ANCA result at a titer of 1:80. In addition, antinuclear antibody (ANA) testing was positive at a titer of 1:320 with a fine speckled nuclear pattern, and lupus anticoagulant and anti-myeloperoxidase (MPO) antibodies were reactive. Testing for anti–double-stranded DNA, c-ANCA, anti-Ro, anti-La, anti-Scl-70, anticardiolipin antibodies, and anti–β2-glycoprotein I was negative. For sarcoidosis investigation, angiotensin-converting enzyme (ACE) levels were also normal.

During readmission, the pathology report of a gluteal skin biopsy indicated panniculitis with a mixed cellular infiltrate associated with granulomatous necrosis, which, together with the rheumatologic assessment, supported the diagnosis of ANCA-associated vasculitis. For renal evaluation, a spot urine protein-to-creatinine ratio (P/C) of 0.6 was obtained, and renal function had remained preserved since the beginning. Urinalysis showed no abnormal elements, and urine sediment examination revealed no abnormalities.

After the diagnosis of GPA was established, the patient received pulse therapy with methylprednisolone 30 mg/kg for 3 consecutive days, combined with intravenous cyclophosphamide 750 mg/m² of body surface area. After 48 hours of corticosteroid therapy, fever resolved and inflammatory markers decreased. An ultrasound-guided renal biopsy performed 2 weeks after pulse therapy, with a sample of 29 glomeruli, showed no inflammatory changes and only 1 globally sclerotic glomerulus. After the

procedure, the patient was discharged on prednisone 1.5 mg/kg/day, sulfamethoxazole–trimethoprim, acetylsalicylic acid, voriconazole, gabapentin, calcium carbonate, and vitamin D.

DISCUSSION

This case illustrates the complexity of the diagnostic journey of an adolescent who initially presented with fever, hemoptysis, and severe dyspnea. Compared with adult-onset disease, pediatric GPA is more severe at initial presentation, with a greater need for hospitalization and ventilatory support[4]. In addition, pediatric disease predominates in girls, with a mean age at onset of 14 years[6], whereas in adulthood it predominates in males[2].

Initially, the patient was treated with different beta-lactams under the hypothesis of bacterial pneumonia, without improvement, and was subsequently investigated for pulmonary tuberculosis—an endemic disease in Brazil—with the diagnosis ruled out. The good clinical course after antifungal therapy, together with growth of Fusarium spp. in BAL culture and the report of a gluteal nodule, preliminarily supported a diagnosis of fusariosis. Fusarium species are ubiquitous and widely distributed in air, soil, and water, and the most common infections are superficial (onychomycosis and keratitis). In immunocompromised patients, who are more susceptible to invasive forms, the disease manifests predominantly as pneumonia (ground-glass opacities and nodules), bronchiectasis, and skin lesions resembling ecthyma[7].

Progression of pulmonary lesions to cavitation and recurrence of the initial symptoms prompted a search for differential diagnoses after readmission. Reactive p-ANCA and anti-MPO results were decisive for the diagnosis because, after these were obtained, sufficient classification criteria were met (3/5). The autoantibody pattern observed in this case is not the most characteristic of GPA (c-ANCA and anti–proteinase 3); however, it is noteworthy that a reactive ANCA of any type is sufficient as a criterion and may be found in up to 90% of cases[5].

It should be noted that, had the skin biopsy report been available earlier, clinical suspicion and confirmation might also have occurred sooner. Ultimately, all five EULAR/PRINTO/PRES GPA classification criteria were met[5]: skin histopathology; upper airway involvement (epistaxis and sinus disease); tracheobronchial involvement (tracheal stenosis); pulmonary involvement (cavitated nodules); renal involvement (P/C ratio > 0.3 mg/mg); and ANCA positivity. Despite so many criteria being present, the most common manifestations are renal (83%), pulmonary (74%), and upper airway (70%)[2].

The renal biopsy did not support the diagnosis, and a possible explanation is that it was performed after pulse therapy. The finding of pauci-immune and/or necrotizing glomerulonephritis is consistent in 94% of GPA cases and is the main determinant of disease morbidity and mortality[6].

The largest pediatric GPA cohort showed that subglottic stenosis is uncommon (10%); however, it is notable for its specificity in childhood-onset disease, being five times more frequent than in adult-onset disease. Its inclusion in the EULAR/PRINTO/PRES classification criteria reflects the relevance of this lesion[2].

Although not criteria for GPA, both dacryocystitis and sciatic mononeuritis were attributed to the disease. Ocular manifestations such as conjunctivitis, episcleritis, retro-orbital masses, and proptosis may occur in up to 40%, whereas more severe neurological manifestations such as neuropathy, stroke, and muscle weakness occur in less than 3%[6].

The proposed treatment followed SHARE (Single Hub and Access point for paediatric Rheumatology in Europe) recommendations for severe GPA[8], including prophylactic antiplatelet therapy and sulfamethoxazole–trimethoprim for Pneumocystis jirovecii prophylaxis. Given the expectation of prolonged immunosuppression, secondary prophylaxis for pulmonary fusariosis was maintained.

CONCLUSION

Diagnosing primary vasculitis in pediatric patients is challenging due to the wide variety of clinical manifestations, which depend on the location and extent of disease, and the similarity of its presentation to other conditions. In the present case, the cutaneous and pulmonary manifestations were initially fully attributed to Fusarium spp. fungal infection; however, subsequent involvement of other target organs, as well as histopathology and ANCA results, were crucial for establishing the diagnosis. Vasculitis should be considered in the differential diagnosis of patients presenting with systemic inflammation of unexplained origin and/or multiorgan involvement.

REFERÊNCIAS:

1. Bohm M, Gonzalez Fernandez MI, Ozen S, Pistorio A, Dolezalova P, et al. Clinical features of childhood granulomatosis with polyangiitis (Wegener's granulomatosis). Pediatr Rheumatol Online J. 2014;12:18. http://www.doi.org/10.1186/1546-0096-12-18
2. Cabral DA, Morishita K. Antineutrophil cytoplasmic antibody associated vasculitis. In: Petty RE, Laxer RM, Lindsley CB, Wedderburn LR, Mellins ED, Fuhlbrigge RC, editors. Textbook of paediatric rheumatology. 8th ed. Philadelphia: Elsevier; 2021. p. 484-497. http://www.doi.org/10.1016/B978-0-323-24145-8.00036-3
3. Belem JMFM, Pereira RMR, Perez MO, do Prado LL, Calich AL, Sachetto Z. Epidemiologic features of systemic vasculitides in the southeast region of Brazil: hospital-based survey. J Clin Rheumatol. 2020;26(7 Suppl 2):S106-S110. http://www.doi.org/10.1097/RHU.0000000000001041

4. James KE, Xiao R, Merkel PA, Weiss PF. Clinical course and outcomes of childhood-onset granulomatosis with polyangiitis. Clin Exp Rheumatol. 2017;35 Suppl 103:202-208. Disponível em: https://pubmed.ncbi.nlm.nih.gov/27749233/

5. Ozen S, Pistorio A, Iusan SM, Bakkaloglu A, Herlin T, Brik R, et al. EULAR/PRINTO/PRES criteria for Henoch-Schönlein purpura, childhood polyarteritis nodosa, childhood Wegener granulomatosis and childhood Takayasu arteritis: Ankara 2008. Part II: final classification criteria. Ann Rheum Dis. 2010;69(5):798-806. http://www.doi.org/10.1136/ard.2009.116657

6. Cabral DA, Canter DL, Muscal E, Nanda K, Wahezi DM, Spalding SJ, et al. Comparing presenting clinical features in 48 children with microscopic polyangiitis to 183 children who have granulomatosis with polyangiitis (Wegener's): an ARChiVe cohort study. Arthritis Rheumatol. 2016;68(10):2514-2526. http://www.doi.org/10.1002/art.39729

7. Nucci M, Anaissie E. Invasive fusariosis. Clin Microbiol Rev. 2023;36(4):e00159-22. http://www.doi.org/10.1128/cmr.00159-22

8. de Graeff N, Groot N, Brogan P, Ozen S, Avcin T, Bader-Meunier B, et al. European consensus-based recommendations for the diagnosis and treatment of rare paediatric vasculitides: the SHARE initiative. Rheumatology (Oxford). 2019;58(4):656-671. http://www.doi.org/10.1093/rheumatology/key322