Residência RP Pediátrica
Publicação Oficial da Sociedade Brasileira de Pediatria

INTERACTIVE CASE

Two siblings with diffuse micronodular lung disease: What is the diagnosis?

Moacyr Starich Guerra Barreto[1], Selma Sias[2], Adriana Paiva de Mesquita[3], Terezinha Micelli Martire[4], Pedro Augusto Daltro[5]
Coordenadoras: Sandra Mara Amaral[6], Patrícia Fernandes Barreto Costa[7]

CASE 1

Female patient, 6 years old, living in the rural area of Rio de Janeiro State presenting with cough, dyspnea, and fever, along with exercise-induced dyspnea for 3 weeks. She was treated (Figure 1A) with amoxicillin and erythromycin without improvement (Figure 1B). Physical examination revealed a thin and moderately dyspneic child with cutaneo-mucous pallor. Axillary temperature was 37.4°C and oxygen saturation in the air was 87%. Respiratory rate was 56 bpm. Thorax was atypical, with preserved lung expansion, wheezing, and fuzzy rales. BCG vaccination scar was present. Presence of hepatomegaly.

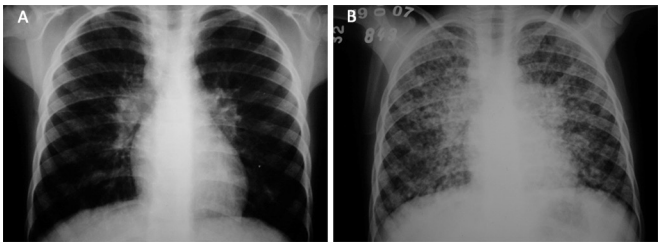

Figure 1. A: Chest X-rays with increased suggestive hilar enlarged lymph nodes. **B:** CXR held in the revaluation due the worsening of symptoms: accentuation of the increase in hilar suggestive of lymphadenopathy and diffuse micronodular infiltrate.

Chest x-ray showed diffuse bilateral micronodular infiltrate in addition to increased hilar regions suggestive of adenomegaly. (Figures 1A and 1B).

CASE 2

Male patient, 12 years old, presenting with fever, cough, dyspnea, and chest pain, not responsive to oral antibiotics.

On examination, it was observed mild respiratory distress, with FR = 32 bpm, 97% saturation. respiratory auscultation with MV This bilaterally with crackles in both lung bases

The simple chest radiographs demonstrated evolution similar to the case 1, an increase of regions suggestive of hilar lymphadenopathy progressing to an undercover micronodular diffuse and bilateral (Figures 2A and 2B).

The patients lived in the city of Nova Friburgo and had recently stayed on a farm in the Rio Preto Valley, which is a habitat for birds and bats living in the trees where the children played.

The patients were hospitalized and the following tests were ordered: CBC, PPD, *Mycobacterium tuberculosis* culture in 3 sputum samples, culture of 3 sputum samples, HIV serum assay, and serum immunoglobulin assay. Chest CT scan confirmed the X-ray findings. (Figures 3A and 3B).

[1] MD. Graduated in Universidade Federal do Estado do Rio de Janeiro (UNIRIO).
[2] Adjunct Professor. Universidade Federal Fluminense(UFF).
[3] Pediatric Pulmonologist. Hospital Municipal Jesus do Rio de Janeiro.
[4] Associated Professor. Universidade Federal do Estado do Rio de Janeiro (UNIRIO).
[5] Pediatric Radiologist. Instituto Nacional da Saúde da Mulher Criança e Adolescente Fernandes Figueira (FIOCRUZ).
[6] Pediatrician. Retired staff, Federal Hospital for State-Level Government Employees, Rio de Janeiro, RJ, Brazil.
[7] Professor of Pediatric Pulmonology. Federal University of Rio de Janeiro (UNIRIO). Physician, Department of Pulmonology, IFF/Fiocruz, Rio de Janeiro, RJ, Brazil.

Correspondence to:
Patricia Barreto Costa.
IFF. Av. Rui Barbosa, nº 716, Flamengo, Rio de Janeiro, RJ, Brazil. CEP: 22250-020. E-mail: pfbcosta@gmail.com

Residência Pediátrica 2016;6(2):66-71.

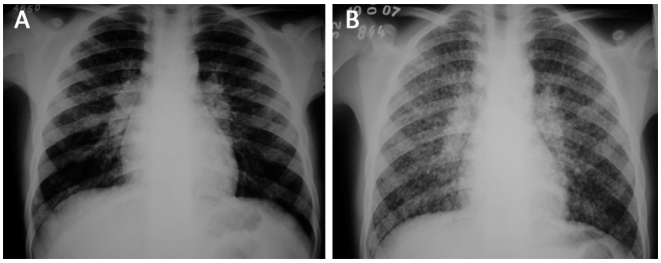

Figure 2. A: CXR: increased hilar volume suggestive enlarged lymph nodes and reticulonodular infiltrate. **B:** CXR held in the revaluation; there was worsening of symptoms, Accentuation of hilar ymphadenopathy and diffuse micronodular infiltrate.

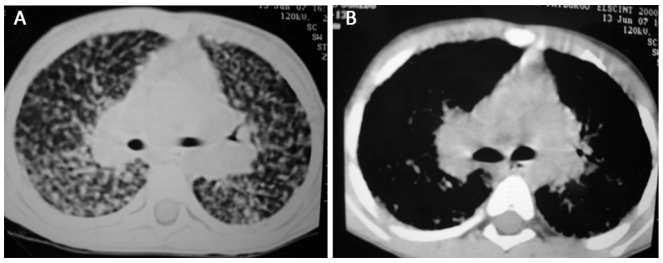

Figure 3. A: Computed tomography of chest (case 1) - Micronodular diffuse infiltrate. **B:** CT - mediastinum window with bulky mediastinal lymphadenopathy.

QUESTIONS:

1) Diffuse micronodular appearance in chest x-rays of pediatric patients can be observed in which clinical conditions?

(A) Tuberous sclerosis
(B) Alveolar microlithiasis
(C) Histoplasmosis
(D) Metastasis of papillary carcinoma of the thyroid
(E) All of the conditions listed above

• In Brazil, the main cause of diffuse micronodular disease is miliary tuberculosis. All of the diseases listed above may manifest as diffuse micronodular disease in pediatric patients. This radiological pattern may also be observed in other fungal infections, viral infections, and sarcoidosis[1-4].

• Malignant neoplasm of thyroid in children is considered rare. Among these tumors, the most common are carcinomas derived from differentiated follicular cells (Papillary, follicular and its less aggressive variants). The medullary tumor and poorly differentiated one(insular, Hürthle, tall cells, etc.) constitute only 5 to 10 % of the total. In children, in general, this gland tumors are much more aggressive and with great number of metastases to diagnosis[5].

• Pulmonary alveolar microlithiasis is a rare disease with chronic evolution, with non defined etiology and pathogenesis. It is basically characterized by numerous small calculi (calciferites, calcospherites or microliter) within the airspaces. In a study subpleural linear calcifications were also found in 90% of the patients[6].

2) The concomitant presence of hilar/mediastinal adenopathy reinforces the diagnostic hypothesis of:

(A) Tuberous sclerosis
(B) Alveolar microlithiasis
(C) Histoplasmosis
(D) Metastasis of papilliferous carcinoma of the thyroid
(E) All of the above.

• In Brazil, the main cause of hilar and mediastinal adenopathy is tuberculosis. Other causes are fungal infections such as histoplasmosis (acute forms), coccidioidomycosis, and infections such as mononucleosis, Varicella zoster, mycoplasma pneumonia and *Chlamydia pneumoniae*, as well as sarcoidosis/Blau syndrome; Castleman disease, hypersensitive reactions to drugs, and neoplasms such as lymphoma, leukemia, etc.

• In cases of histoplasmosis mediastinal lymphadenopathy are described the following clinical and radiological forms: pulmonary acute, widespread severe, lung cavity, mediastinal lymphadenitis and mediastinal granuloma.

• In rare cases, the adenophaty can achieve great dimensions and compress thoracic structures as trachea, bronchi, and large vessels. In more severe cases, can occur pericarditis with effusion and pleural effusion, similarly to tuberculous constictive pericarditis[7,8].

• The mediastinal lymph node enlargement in TB can compresses extrinsicaly compresses the patient´s airway causing airflow obstruction or fistulae and bronchopneumonia and endobronchial granuloma.

3) In light of the patient information, what tests should be ordered to confirm the diagnosis?

(A) Bronchoscopy with broncho-alveolar lavage and oil red coloring
(B) Lung biopsy with electron microscopy
(C) Specific skin tests
(D) Radial immunodiffusion and culture
(E) Test for specific mutation

• The presence of a disease in two siblings is suggestive of either an infectious disease or a genetic cause, but the simultaneous condition in patients of different ages strengthens the hypothesis of infection. There is very important epidemiological data in the patient history: they stayed in an environment contaminated with bird and bat feces, which is rich in nitrogen and which promotes the growth of *Histoplasma capsulatum*.

• Definitive diagnosis of histoplasmosis is made by demonstration of the fungus via histopathology, cytopathology, or culture. After staining with hematoxylin-eosin or methenamine silver, the oval-shaped yeast cells can be seen in the tissue or encompassed within the macrophages. Culture can take up to 6 weeks to show a positive result and is therefore not a method for early diagnosis[9].

• Antigen detection (galactomannan) is fast, non-invasive, and highly sensitive. Combined testing of serum and urine has sensitivity exceeding 80% in cases of acute pulmonary histoplasmosis and exceeding 90% in cases of disseminated histoplasmosis. Sensitivity increases with the severity of the disease and in immunosuppressed/immunocompromised patients. Testing for this antigen can be performed on other fluids such as broncho-alveolar lavage, cerebro-spinal fluid, pericardial fluid, pleural fluid, and ascites. Cross reactions can occur with blastomycosis, *Penicillium marneffei* infection, paracoccidioidomycosis, and more rarely, aspergillosis[10].

• Tests for the presence of antibodies using complement fixation (CF), radial immunodiffusion (ID), or enzyme immunoassay are commonly applied to diagnose histoplasmosis. Immunodiffusion tests for two precipitins, which are known as the M and H bands. The H band is present in about 25% of cases and usually disappears within 6 months after infection. Ideally, ID and FC are performed[10].

• Antibodies usually appear 4-8 weeks after acute infection, and the tests may still be negative when symptoms begin to appear[10]. A fourfold increase in titers during the convalescence phase is a diagnostic criterion. Immunosuppressed patients, especially those undergoing solid organ transplants, may have negative test results[10].

• The PCR value is unreliable, and a skin test with histoplasmin is more valuable in terms of epidemiology than diagnosis[10].

Patients underwent endoscopy Respiratory bronchoalveolar lavage with giving out the equipment whitish, thick with negative acid-fast bacilli staining, culture for common negative germs, white color positive for *Histoplasma capsulatum* strain (Figure 4).



Figure 4. Broncho-alveolar lavage: whitish and thick material.

Positive radial immunodiffusion and examination of the broncho-alveolar lavage confirmed the diagnosis of acute histoplasmosis.

4) Which statement is correct?

(A) Most infected patients are asymptomatic.
(B) Most infected patients present an acute flu-like illness.
(C) Histoplasmosis can compromise the adrenals, but does not cause adrenal insufficiency.
(D) Histoplasmosis can affect the eyeball, but does not cause endophthalmitis.
(E) Histoplasmosis can affect the heart - especially the myocardium.

• Most patients infected with *Histoplasma capsulatum* exhibit latent infection. Some patients present a flu-like respiratory condition. Symptoms usually occur after exposure to high amounts of an inoculum, in very elderly or young patients, in immunosuppressed patients, or when the species is very virulent[10].

• Histoplasmosis can spread and affect various organs[13]. Histoplasmosis can cause shock, respiratory failure, and adrenal gland failure.

• The eyeball can be affected by histoplasma in three different ways: endophthalmitis, solitary chorioretinal granuloma, and presumed ocular histoplasmosis syndrome. Histoplasmosis can be a cause of central vision loss in young patients, especially in endemic areas[14].

• The endocardium and pericardium may be affected[10].

5) With regard to the mediastinal involvement of histoplasmosis, we can state that:

(A) In chronic histoplasmosis, exuberant adenomegaly is not observed.
(B) In mediastinal adenitis, the ganglia evolve as in tuberculosis, with fistulization and calcification.
(C) Mediastinal adenitis tends to occur in patients older than 20 years of age.
(D) Most patients with mediastinal lymphadenitis tend to present symptoms such as chest pain and chronic cough.
(E) The pericardium is not affected.

• Mediastinal histoplasmosis may occur as adenitis, granuloma, and fibrosing mediastinitis[10].

• Mediastinal adenitis generally occurs in patients younger than 20 years of age; most patients are likely asymptomatic. It presents itself as a homogeneous mass consisting of nodes that do not calcify or fistulize, but the increase in volume can compress organs such as the esophagus, causing airway obstruction and superior vena cava syndrome[9].

• In endemic areas, it may be accompanied by fever and chest pain. The pain may be intense and suggestive of pleurisy or pulmonary embolism[9].

• Another cause of chest pain in mediastinal adenitis is pericarditis[9].

6) Which statement concerning mediastinal granuloma of histoplasmosis is correct?

(A) Histological identification of the granulomatous lesion is essential for diagnosis
(B) In general, it causes chest pain and symptoms resulting from the mass effect.
(C) Unlike in tuberculosis, the lymph nodes tend to remain isolated, without coalescing or fistulizing.
(D) It is a structure usually surrounded by a thick capsule
(E) In pre-school-aged patients, it can affect the trachea and superior vena cava.

• Mediastinal histoplasmosis granuloma is a heterogeneous mass of mediastinal lymphatic ganglia that is affected by necrosis; it is surrounded by a thin capsule. Diagnosis is macroscopic. Its location generally is paratracheal or subcarinal. In most cases, it is asymptomatic[9,10].

• In young children (2-5 years of age), it can affect the trachea and superior vena cava[9].

• As in tuberculosis, the ganglia in mediastinal histoplasmosis granuloma coalesce are necrotized, and may calcify and fistulize to adjacent organs such as the esophagus, to the airway, or through surgical pathways, as in the case of mediastinoscopy[9].

7) One of the complications of histoplasmosis is fibrosing mediastinitis. The main sign/symptom of this clinical condition is:

(A) Dyspnea
(B) Pleuritic-type chest pain
(C) Hemoptysis
(D) Edema of the cervical region
(E) Perennial wheezing

• Fibrosing mediastinitis is a complication of histoplasmosis resulting from an exuberant fibrotic process. It may have other etiologies. The most common symptom is recurrent hemoptysis.

8) With regard to fibrosing mediastinitis, we can state that:

(A) It affects very young children, such as preschoolers
(B) It causes pulmonary amputation, usually of the left lung.
(C) It may cause superior vena cava syndrome and pulmonary infarction.
(D) It evolves rapidly and causes acute symptoms.
(E) It is a frequent complication of histoplasmosis.

• In general, fibrosing mediastinitis (FM) is a dense and homogeneous mass of fibrotic tissue that causes fusion of the surrounding tissue and blocks blood vessels and airways. It is rare in children younger than 10 years of age and is more frequent in patients 20-30 years of age.

• Clinical manifestations arise from the imprisonment and obstruction of adjacent structures.

• Typical presentation of FM is pulmonary auto-amputation, particularly on the right due to occlusion of the pulmonary artery. It can also cause superior vena cava syndrome[10].

• Often a significant and even complete occlusion may not cause symptoms, leading to the assumption of slow evolution. However, when symptoms do appear, they may be acute[10].

• It is an infrequent complication of histoplasmosis, but may reach a significant prevalence in endemic areas[9].

9) In disseminated histoplasmosis, the most affected organs are:

(A) The skin and the liver
(B) The gastrointestinal tract and the adrenals
(C) The spleen and the bone marrow
(D) The nervous system and the liver
(E) The skin and the bone marrow

• Hematogenous dissemination occurs during the acute phase as in tuberculosis, but is rarely clinically diagnosed[10].

• It is more common in immunosuppressed patients, young children, and elderly patients[10,12].

• It is important to investigate immunodeficiency[10].

• The most affected organs are the liver, spleen, bone marrow, and gastrointestinal tract[10].

• It can also affect the skin, the nervous system, and the adrenals[10].

• Pulmonary involvement translates to diffuse, interstitial, or miliary reticulonodular infiltrate[10].

• It can lead to shock and adrenal insufficiency[10].

10) For the treatment of histoplasmosis in childhood, is correct:

(A) Since the diagnosis was always treated.
(B) In chronic pulmonary histoplasmosis, amphotericin is drug of choice.
(C) The different forms of presentation histoplasmosis require therapeutic strategy differentiated.

(D) The imidazole derivatives should be choice for fibrosing mediastinitis.

(E) The Histoplasma has natural resistance ketoconazole.

• Pulmonary histoplasmosis is classified as a self-limiting disease, with few serious clinical consequences. The treatment varies according to the degree the severity of the disease and the host´s immune state[15].

• Spontaneous regression of symptoms and clinical cure with clinical observation without antifungal treatment occurs in the most of the patients[16].

• In the forms in which it is necessary treatment, imidazole and its derivatives are recommended. Histoplasma is sensitive to many antifungals such as ketoconazole, itraconazole, fluconazole and B amphotericin[10].

• Cases of primary pulmonary histoplasmosis or reactivation present hypoxemia or needing ventilatory support. The patient should receive B amphotericin associated with itraconazole orally at least up to 12 weeks

• In chronic pulmonary form, itraconazole is also a drug of choice, for a long time (1 to 2 years).

Evolution:

The girl, who had more serious symptoms of respiratory failure, required oxygen therapy for 7 days and was treated with intravenous amphotericin B for 21 days followed by the administration of itraconazole. Her brother was treated on an outpatient basis with itraconazole. Both had favorable outcomes.

Both patients only attended two visits to review and, after completion of treatment, despite the team guidance on the need to monitoring, no longer attended the consultations marked.

In 2012, five years after the treatment, it was possible locate patients through active epidemiological search. At the time it was identified that the female patient (case 1) had respiratory symptoms such as dyspnea small efforts and cough. Brother (case 2), in contrast, It was asymptomatic.

The boy's X-ray was normal and girl chest tomography showed calcified Micronodules diffusely with calcified pretracheal right lymph nodes, infracariniais and hilar bilaterally (Figures 5A and 5B).

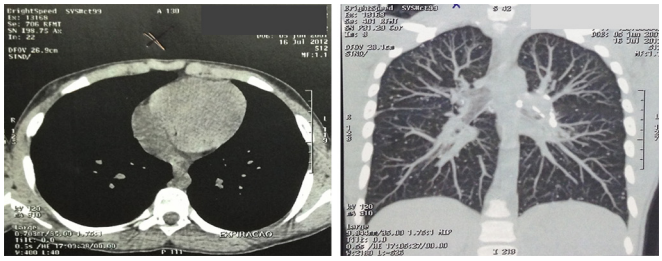

Figures 5A and B. CT : calcified diffuse micronodules (Case 1).

REFERENCES

1. Andreu J, Mauleón S, Pallisa E, Majó J, Martinez-Rodriguez M, Cáceres J. Miliary lung disease revisited. Curr Probl Diagn Radiol. 2002;31(5):189-97.
2. Raoof S, Amchentsev A, Vlahos I, Goud A, Naidich DP. Pictorial essay: multinodular disease: a high-resolution CT scan diagnostic algorithm. Chest. 2006;129(3):805-15.
3. Furqan M, Butler J. Miliary pattern on chest radiography: TB or not TB? Mayo Clin Proc. 2010;85(2):108.
4. Sharma BB. Miliary nodules on chest radiographs: A diagnostic dilemma. Lung India. 2015;32(5):518-20.
5. Cardoso AA, Pianovski MAD, França SN, Pereira RM, Boguszewski M, Sandrini R, et al. Câncer de tireóide na infância e adolescência: Relato de 15 casos. Arq Bras Endocrinol Metab 2004;48(6):835-41.
6. Nin CS, de Souza VV, do Amaral RH, Schuhmacher Neto R, Alves GR, Marchiori E, et al. Thoracic lymphadenopathy in benign diseases: A state of the art review. Respir Med. 2016;112:10-7.
7. Kabangila R, Semvua K, Rambau P, Jackson K, Mshana SE, Jaka H, et al. Pulmonary histoplasmosis presenting as chronic productive cough, fever, and massive unilateral consolidation in a 15-year-old immunocompetent boy: a case report. J Med Case Rep. 2011;5:374.
8. Marchiori E, Gonçalves CM, Escuissato DL, Teixeira KIS, Rodrigues R, Barreto MM, et al. Microlitíase alveolar pulmonar: achados na tomografia computadorizada de alta resolução do tórax em 10 pacientes. J Bras Pneumol. 2007;33(5):552-7.
9. Hage CA, Azar MM, Bahr N, Loyd J, Wheat LJ. Histoplasmosis: Up-to-Date Evidence-Based Approach to Diagnosis and Management. Semin Respir Crit Care Med. 2015;36(5):729-45.
10. Wheat LJ, Azar MM, Bahr NC, Spec A, Relich RF, Hage C. Histoplasmosis. Infect Dis Clin North Am. 2016;30(1):207-27.
11. Fischer GB, Mocelin H, Severo CB, Oliveira Fde M, Xavier MO, Severo LC. Histoplasmosis in children. Paediatr Respir Rev. 2009;10(4):172-7.
12. Kleiman MB. Histoplasmosis. In: Cherry J, Demmler-Harrison GJ, Kaplan SL, Steinbach WJ, Hotez P, eds. Feigin and Cherry's Textbook of Pediatric Infectious Diseases. Philadelphia: Saunders; 2014. p. 2807-32.
13. Aidé MA. Capítulo 4: histoplasmose. J Bras Pneumol. 2009;35(11):1145-51. 2009.
14. Moorthy RS. Histoplasmosis. In: Yanoff M, Duker J, eds. Ophtalmology. Philadelphia: Saunders; 2014. p. 729-32.

15. Santos JWA, Michel GT, Lazzarotto M, Figaro JK, Spilmann D, Homrich GK. Histoplasmose pulmonar cavitária crônica. J Bras Pneumol. 2009;35(11):1161-4.

16. Unis G, Pêgas KL, Severo LC. Histoplasmoma pulmonar no Rio Grande do Sul. Rev Soc Bras Med Trop. 2005;38(1):11-4.

SUPPLEMENTARY LITERATURE

Wheat LJ, Freifeld AG, Kleiman MB, Baddley JW, McKinsey DS, Loyd JE, et al. Clinical practice guidelines for the management of patients with histoplasmosis: 2007 update by the Infectious Diseases Society of America. Clin Infect Dis. 2007;45(7):807-25.

Coura JR. Dinâmica das doenças infecciosas e parasitárias - Volume 2. 2a ed. Rio de Janeiro: Guanabara Koogan; 2013.

Smith JA, Kauffman CA. Pulmonary fungal infections. Respirology. 2012;17(6):913-26.

Dylewski J. Acute pulmonary histoplasmosis. CMAJ. 2011;183(14):E1090.

Hage CA, Wheat LJ. Diagnosis of pulmonary histoplasmosis using antigen detection in the bronchoalveolar lavage. Expert Rev Resp Med. 2010;4(4):427-9.

Ferreira MS, Borges AS. Histoplasmose. Rev Soc Bras Med Trop. 2009;42(2):192-8.