Residência Pediátrica
Publicação Oficial da Sociedade Brasileira de Pediatria

Submitted on: 10/26/2016
Approved on: 07/25/2017

CASE REPORT

Bilateral renal lymphangiectasia: a case associated with pleural effusion, ascites and polycythemia

Nathalia Gravina Bottino[1], Marcio Fernandes Nehab[2]

Keywords:
Pleural Effusion, Ascites, Polycythemia, Kidney, Lymphangiectasis.

Abstract

Renal lymphangiectasia is a rare and benign disorder of the renal lymphatic system, reported in both adults and children. It can be either congenital or acquired. Knowledge of this condition is based on isolated case reports. The presentation is varied, and the condition may be symptomatic or asymptomatic. This article reports the case of a 13-year-old patient with bilateral renal lymphangiectasia associated with polycythemia, pleural effusion, and ascites during hospitalization in the pediatric ward.

[1] Second-year Pediatrics Resident at the Fernandes Figueira National Institute for the Health of Women, Children and Adolescents (IFF), Rio de Janeiro, Brazil.
[2] Master's degree - Pediatrician and Preceptor of Pediatrics Residents at the Fernandes Figueira National Institute for the Health of Women, Children and Adolescents (IFF), Rio de Janeiro, Brazil.

Correspondence to:
Marcio Fernandes Nehab.
Fernandes Figueira National Institute for the Health of Women, Children and Adolescents (IFF). Avenida Rui Barbosa, nº 716, Flamengo, Rio de Janeiro - RJ. Brasil. CEP: 22.250-020. E-mail: marcio.nehab@gmail.com

INTRODUCTION

Renal lymphangiectasia is a rare and seldom known condition[1-3]. It is a benign disorder of the renal lymphatic system that has been reported in both adults and children. It may be either congenital or acquired[1,2]. Knowledge of this condition is based on reports of isolated cases[1,2]. Several forms of presentation have been described either as an asymptomatic imaging finding or associated with hematuria, proteinuria, flank pain, abdominal pain or distension, palpable abdominal masses, swelling of extremities, hypertension, polycythemia, pleural effusion, and ascites[2-5]. In some cases, kidney failure may occur[2-5].

Treatment will depend on the severity and complications[2,3,5]. A total of 43 cases of renal lymphangiectasia were reported between 1890 and 1993[2]. Only 14 cases have been described since 1993 in the literature, three of them with pleural effusion[2,6,7] and four with polycythemia[2,6,8,9]. The objective of this article is to report the case of a 13-year-old patient with bilateral renal lymphangiectasia associated with pleural effusion, ascites, polycythemia, and unimpaired kidney function during hospitalization in a pediatric ward.

CASE REPORT

A male patient (13 years old, 165 cm, black) was diagnosed with bilateral renal lymphangiectasia 4 years before. He was referred to the Intensive Care Unit (ICU) our hospital from a primary health care unit, with a pneumonia that, after 10 days with fever, progressed with shortness of breath and a hypertensive peak of 160 × 100 mmHg (above 135 × 90 mmHg, calculated as the 99th blood pressure percentile for age and height). On admission to the ICU, the patient was hemodynamically stable, requiring oxygen therapy with a mask. Cefepime, azithromycin, and oseltamivir were started.

After 2 days, he was transferred to the infirmary, breathing ambient air, and was in good general condition, eupneic, BP = 129 × 75 mmHg. Physical examination revealed the following changes: reduced vesicular breath sounds in the bases of both hemithoraces, palpable mass in the right and left flanks, with pain on deep palpation of the left flank. Laboratory tests evidenced polycythemia (hematocrit: 52.4%, hemoglobin: 16.2 g/dL), leukocytes: 14,000/mm^3 (0/2//0/0/10/63/13/12), normal urinalysis, no proteinuria or hematuria, normal kidney function, urea: 10 mg/dL, creatinine: 0.59 mg/dL, CRP: 6.9 mg/dL (< 0.5 mg/dL).There were no changes in the echocardiogram.

Past medical history revealed urinary incontinence and nocturnal enuresis without medical follow-up for 2 years.

An abdominal ultrasound evidenced enlarged kidneys (~18 cm) with multiple bilateral peripheral cysts in the renal pelvis, not compatible with multicystic kidney disease. Thoracic ultrasound evidenced a small right-sided homogeneous pleural effusion and a left laminar pleural effusion with atelectasis.

CT scan showed a small bilateral pleural effusion, larger on the left side, and ascites. The kidneys were in the normal position, substantially enlarged, with lobulated contours, and diffuse parenchymal thickening. (Figures 1 and 2)

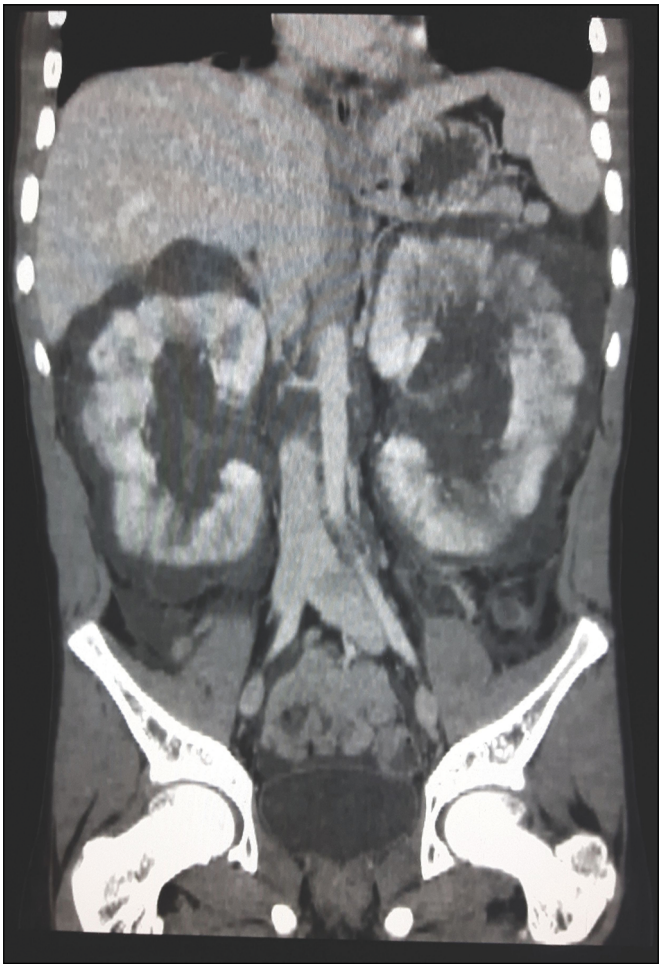

Figura 1. Kidneys in the normal position but substantially enlarged, with lobulated contours and diffuse parenchymal thickening, with no signs of pyelocaliceal or ureteral dilation. Presence of sparse cortical cysts and cystic formations located in the perirenal spaces and renal sinuses that distort and distend the collecting system without causing dilation, compatible with parapyelic cysts. The hypothesis of lymphangioma/renal lymphangiectasia was considered. CT scan of the abdomen.

The patient brought a 2011 renal biopsy report:

Renal capsule with highly vascularized fibro-fatty tissue, permeated by polymorphonuclear inflammatory infiltrate, alongside large vascular structures of hyaline walls and flattened lining, compatible with lymphangiectasia.

Renal parenchyma with fibrous tissue and capsular vascular proliferation, associated with an extensive subcapsular hyalinization area containing a few necrotic ducts. Glomeruli of varying sizes with dilation of Bowman's spaces, focal glomerulosclerosis, predominantly mononuclear inflammatory infiltrate permeating the parenchyma, which shows fibrosis and focal dilation of ducts.

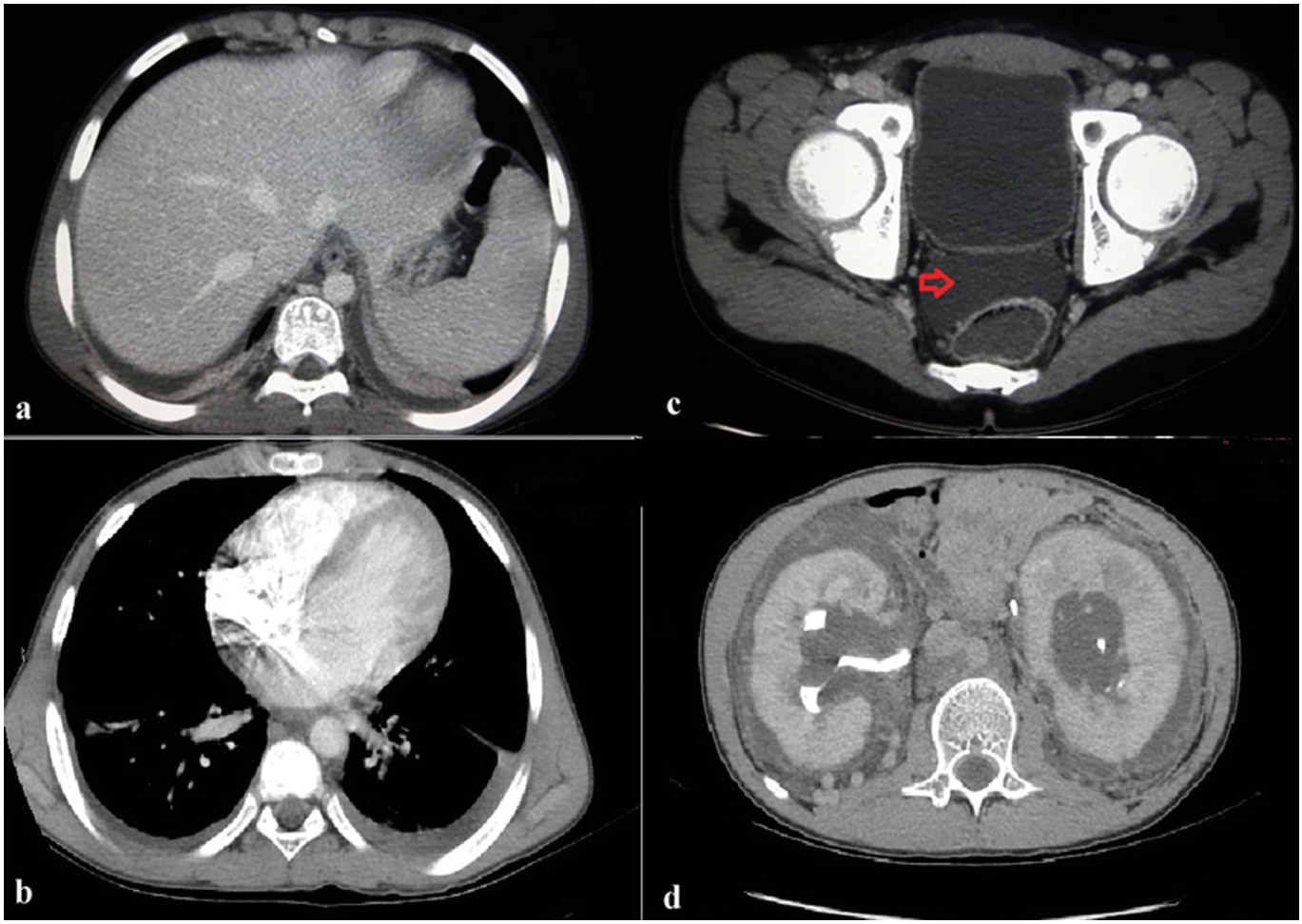

Figura 2. a) Small bilateral pleural effusion, with compressive atelectasis of the corresponding pulmonary parenchyma. b) Larger pleural effusion on the left. c) Small amount of free fluid in the abdominal cavity (red arrow). d) Presence of fluid infiltration in the pararenal spaces. Presence of right pararenal venous collateral circulation that creates a communication between the right renal vein and the vena cava. CT scan of the chest, abdomen, and pelvis.

Diffuse vascular ectasia is observed in between ducts and glomeruli, sometimes to the degree of microcysts.

Histology, associated with imaging and the clinical history, is compatible with nephromegaly due to chronic pyelonephritis and renal lymphangiectasia from compression. This material had no embryonic or neoplastic remains.

Thoracentesis was unnecessary, because the patient was eupneic and stable.

Cefepime treatment lasted 10 days, and azithromycin 5 days. The BP of the patient remained normal, after initial stabilization, for the rest of the hospitalization period (below 124 × 78 mmHg, within the estimated percentile for height and age). He did not require antihypertensive drugs, and kidney function was normal. The patient was discharged and referred to follow-up with general pediatrics and urodynamics.

DISCUSSION

A little more than 50 cases of symptomatic renal lymphangiectasia have been described since 1890[2,6]. The condition may occur at any age, regardless of sex, with the majority (90%) being bilateral and asymptomatic[2,10]. The symptomatic form has been associated with abdominal pain in the flanks, hematuria, proteinuria, abdominal distension or masses, hypertension, polycythemia, pleural effusion, ascites, fatigue, weight loss, pyelonephritis, and rarely, kidney failure[2,5,6,10].

Its pathogenesis remains uncertain, but there is a hypothesis that it results from a malformation in the development of the renal lymphatic tissue, causing obstruction and lymph accumulation in the parenchyma, subcapsular space, and hilum[6,10]. Another proposed mechanism is injury acquired after trauma, healing, or inflammation[6,11].Some authors suggest it is a benign neoplastic process[1,11].

Differential diagnoses include polycystic kidney disease, nephroblastomatosis, lymphoma, multilobular cystic nephroma, hydronephrosis, hematoma, abscesses, and other causes for renal masses[7,10,12].

The diagnosis of renal lymphangiectasia is based on clinical data in conjunction with ultrasound, MRI, and CT scan findings.[1] It can be confirmed with needle aspiration of chylous fluid and perinephric collections that evidence a lymphocytic predominance (> 90%), but this is rarely necessary[1,2,11].

Imaging findings include peripelvic cysts and perirenal fluid collection[7]. Ultrasound shows simple anechoic cysts with well-defined walls[7]. Kidneys may be enlarged and have a reduced corticomedullary ratio[7]. CT scan also shows fluid collections, but the septa may not be well defined[7].

Adjacent structures are typically not invaded, although they can be in contiguity or displaced by the injury[5,7]. In case of expansion to the pelvis or retroperitoneal region, the differential diagnoses become more likely[10]. In polycystic kidney disease, the main differential diagnosis, the cysts occur in the renal cortex, whereas in lymphangiectasia, the renal cortex is normal, and the pyelocaliceal system is not dilated[12].

In the present case, computed tomography showed substantially enlarged kidneys, with lobulated contours, and diffuse parenchyma thickening, without signs of pyelocaliceal or ureteral dilation, in addition to cystic formations located in the perirenal spaces and renal sinus that distorted and distended the collecting system, without dilation. In other words, it showed cysts located in the renal pelvis, typical of lymphangiectasia. Other diagnoses, such as nephroblastoma, lymphoma, and cystic multilocular nephroma, could also be ruled out by the fact that all of them involve the renal parenchyma[12].

Asymptomatic cases are treated by conservative management[12]. Diuretics and antihypertensives can be administered to symptomatic patients[12]. Complicated cases can be treated with nephrectomy (if unilateral), percutaneous drainage, or marsupialization of the cysts to the retroperitoneum, especially in case of pain, hematuria, or renin-dependent hypertension [1,7,8]. This procedure is associated with recurrent ascites, which can be treated with diuretics[8].

Although the diagnosis is based on imaging examinations, renal biopsy has been performed in a few cases[2]. In the present case, the patient had already undergone renal biopsy upon diagnosis when he was 8 years old, and it corroborated the diagnosis by showing vascular structures of hyaline walls and flattened lining in the renal capsule, which was compatible with lymphangiectasia. It also detected chronic pyelonephritis by compression. Neoplasms were discarded.

In the present report, the patient presented pleural effusion, ascites, and polycythemia, with no change in renal function. The patient had an early hypertensive peak, but maintained normal blood pressure through the rest of the hospital stay.

There are few cases of association with pleural effusion in the literature[2]. Our patient presented a small bilateral pleural effusion and did not require thoracentesis, although he had shortness of breath upon admission. At that time, when the underlying disease was unknown, treatment for pneumonia was initiated, and antibiotic therapy was completed. However, we consider it more likely that the pleural effusion was transudative and related to lymphangiectasia, rather than parapneumonic, although we cannot test this hypothesis. In any case, we believe that it is valid to consider that even in case of pneumonia, a patient with renal lymphangiectasia can present pleural effusion, not due to a parapneumonic process, but rather due to the underlying disease. Ascites could corroborate the diagnosis of a transudative process as well as the presence of polycythemia and a painful abdominal mass, which are characteristics associated with the underlying disease.

The patient presented hematocrit and hemoglobin levels higher than normal for his age, was not a smoker, and had no other likely cause for polycythemia. The proposed mechanism for polycythemia is ischemia caused by renal compression and consequent secretion of erythropoietin by perinephric lymphangiomas[8-10]. There were no associated complications, and no treatment was necessary for this.

The treatment of polycythemia secondary to renal lymphangiectasia is controversial[10]. There are reports of cases that required intervention, and phlebotomies were performed to control hemoglobin levels[9,10].

Some authors have mentioned that, in case of surgical management, marsupialization is preferred over percutaneous drainage[10]. However, there is no evidence that marsupialization of the cysts improves polycythemia, in addition to causing significant morbidity; thus, it is not recommended for these cases[8]. Sclerotherapy is reported to be a promising treatment[10].

CONCLUSION

Renal lymphangiectasia is a rare condition, often congenital, that can progress to renal failure. Its knowledge comes from reports of isolated cases, making its early diagnosis and management of its complications difficult, especially in urgent and emergency situations. It is important that pediatricians be informed about this disease and its possible associations, benefiting patient diagnosis, treatment, and follow-up. We have presented a case of renal lymphangiectasia associated with pleural effusion, ascites, polycythemia, and a painful abdominal mass that required support treatment. Follow-up should be conducted with CBC control, monitoring of renal function and blood pressure, and imaging examinations.

REFERENCES

1. Pianezza ML, Mokhtassi A, Wu L, D'A Honey RJ. Case report: renal lymphangiectasia. Can J Urol. 2006;13(4):3204-7.

2. Nassiri AA, Lotfollahi L, Bakhshayeshkaram M, Kiani A, Haghighi S, Alavi Darazam I, et al. Renal Lymphangiectasia: A Curious Cause of Pleural Effusion. Tanaffos. 2015;14(3):213-6.
3. Sanchez F, Prieto JC, Koral K, Baker LA. Childhood renal lymphangiectasia. Int Braz J Urol. 2008;34(6):772-3. DOI: http://dx.doi.org/10.1590/S1677-55382008000600013
4. Vasconcelos RA, Pereira ES, Bauab Jr T, Valente RS. Renal lymphangiectasia: incidental finding at multislice computed tomography and literature review. Radiol Bras. 2012;45(3):178-80.
5. Restrepo JM, Amaya JEL, Sepúlveda NA, Vélez MU, Massaro M. Renal lymphangiectasia. MDCT and MRI findings. Rev Colomb Radiol. 2011;22(3):1-8
6. Bazari H, Attar EC, Dahl DM, Uppot RN, Colvin RB. Case records of the Massachusetts General Hospital. Case 23-2010. A 49-year-old man with erythrocytosis, perinephric fluid collections, and renal failure. N Engl J Med. 2010;363(5):463-75.
7. Al-Dofri SA. Renal lymphangiectasia presented by pleural effusion and ascites. J Radiol Case Rep. 2009;3(10):5-10. DOI: 10.3941/jrcr.v3i10.317
8. Shaheen M, Hilgarth KA, Hawes D, Badve S, Antony AC. A Mexican man with “too much blood”. Lancet. 2003;362(9386):806.
9. Burton IE, Sambrook P, McWilliam LJ. Secondary polycythaemia associated with bilateral renal lymphocoeles. Postgrad Med J. 1994;70(825):515-7. DOI: 10.1136/pgmj.70.825.515
10. Blanc M, Schmutz G, Belzile F, Sabbagh R. Renal lymphangiectasia presenting with hypertension and polycythemia. Can Urol Assoc J. 2014;8(1-2):E163-6. DOI: 10.5489/cuaj.1596
11. Ramseyer LT. Case 34: renal lymphangiectasia. Radiology. 2001;219(2):442-4.
12. Rastogi R, Rastogi V. Computed tomographic scan in the diagnosis of bilateral renal lymphangiectasia. Saudi J Kidney Dis Transpl. 2008;19(6):976-9.