Residência RP Pediátrica
Publicação Oficial da Sociedade Brasileira de Pediatria

Submitted on: 06/02/2016
Approved on: 10/28/2018

REVIEW ARTICLE

Microcephaly: investigation and diagnostic approach

Livia dos Santos Pires[1], Larrissa Nogueira de Freita[2], Leticia Baldez de Almeida[1], Livia Caroline Saviolo Cunha[1], Lohayne Marins Teixeira[1], Marleany Garcia Barros Mohallem Corrêa[1], Amanda Ramos Neves Araújo[3], Clarisse Pereira Dias Drumond Fortes[4]

Keywords:
Microcephaly, Genetic Diseases, Inborn, Flavivirus Infections, Congenital Abnormalities, Neurologic Manifestations.

Abstract

The brazilian Ministry of Health declared, in November 2015, national health emergency due to an outbreak in Pernambuco of microcephaly in neoantes, with 268 cases registration. This number is considerably higher than the average for the period 2010-2014, that was nine cases by year. Since then, it has increased the number of diagnoses of cases of microcephaly throughout the national territory, drawing the attention of experts and general population. According to the World Health Organization (WHO), microcephaly is characterized by measuring the skull performed by standard technical equipment and on the head circumference (HC) present as less than minus two (-2) standard deviations below the average specific for sex and gestational age. It also considers that the smallest as least three (-3) standard deviations is defined as severe microcephaly. Although, in the present context, an important part of microcephaly diagnoses is being linked to congenital infection Zika virus, microcephaly have complex and multifactorial etiology. It may be related to genetic inheritance or syndromes, maternal malnutrition, use of drugs and drug use during pregnancy, metabolic syndromes and congenital infections. This literature review aims to discuss the concept, epidemiology, symptomatology and causes of microcephaly, contextualizing it in the current scenario of Zika virus infection.

[1] Aluno de graduação em medicina no Centro Universitário de Volta Redonda (UniFOA).
[2] Aluna de Graduação de Medicina - UniFOA.
[3] Graduada em Medicina. Residente (R1) de Pediatria do Hospital São João Batista/Volta Redonda/ RJ.
[4] Mestre em Planejamento, Política e Administração em Saúde pelo Instituto de Medicina Social pela FM/ UERJ. Professora-assistente de pediatria para medicina do Centro Universitário de Volta Redonda (UniFOA).

Correspondence to:
Clarisse Pereira Dias Drumond Fortes.
UniFOA. Rua 154, 2001/ 702 - Laranjal - Volta Redonda/ RJ - CEP 27255-085. E-mail: clarisse.dias@globo.com

INTRODUCTION

In November 2015, the Brazilian Ministry of Health declared a state of national health emergency due to an outbreak of microcephaly among neonates in Pernambuco, with a total of 268 registered cases, which is considerably more than the average of 9 cases/year registered in 2010–2014[1]. Since then, the number of diagnosed cases of microcephaly has been increasing throughout the national territory, drawing the attention of experts and the general population.

According to the World Health Organization (WHO), microcephaly is defined by the cephalic perimeter (CP) measured using standard techniques and equipment as being less than two (−2) standard deviations below the mean for sex and gestational age. Moreover, cases with less than three (−3) standard deviations are considered severe[2].

Although a considerable number of cases of microcephaly are being linked to congenital Zika virus infection in the current context, this condition has a complex and multifactorial etiology. It may be related to genetic inheritance or syndromes, maternal malnutrition, use of medication or illicit drugs during pregnancy, metabolic syndrome, and congenital infections.

This literature review aims to discuss the concept, epidemiology, signs, symptoms, and causes of microcephaly, contextualizing it with the current scenario of Zika virus infection.

SIGNS AND SYMPTOMS OF MICROCEPHALY

Examination of the skullcap is initiated with inspection and palpation. Examiners should check for asymmetries, bulging, and concavities, and sutures and fontanelles should be palpated. The fontanelles or "soft spots" are open spaces between bones that facilitate brain growth without compression of its structures.[2,3]

At birth, an infant usually has two palpable fontanelles, anterior and posterior fontanelles. The anterior fontanelle is located at the junction of the frontal and parietal bones and can vary in size; it usually closes between 15 and 18 months of age. In turn, the smaller posterior fontanelle located between the parietal and occipital bones usually closes between 3 and 6 months of age. However, regardless of the age at which fontanelle closure occurs, monitoring CP and psychoneuromotor development in infants is paramount to ensure that their head undergoes normal growth and that there are no signs of brain compression[2,3].

CP is the measurement of the fronto-occipital circumference; it is an anthropometric parameter routinely evaluated during pediatric consultations to monitor possible developmental deviations. CP should be measured by passing a measuring tape across the glabella and occipital protuberance, the most prominent point of the occipital bone. This measure reflects brain growth and should be assessed and plotted at each consultation using charts matched for age and sex. In Brazil, the vaccination booklets distributed by the Ministry of Health feature these charts[2,3].

According to the Pan American Health Organization and WHO[4], CP below the 10th percentile (P10) or above P90 are the indicators of probable developmental delay and require psychoneuromotor evaluation.

Head size is the most obvious sign of microcephaly to examiners, which is considerably smaller in children with microcephaly than that in normal children of the same sex and age. In children born at term, those with CP < 32 cm at birth are considered microcephalic. However, this value changes in the case of prematurity, which is directly proportional to gestational age.

With microcephaly, a simultaneous characteristic craniofacial deformity may be observed, resulting from a discrepancy between the skull and facial growth. Consequently, on examination, patients present a small head with a "loose" and slightly wrinkled scalp, a short and backward-projected forehead, and disproportionately large ears[2].

EPIDEMIOLOGY

As a consequence of the substantial increase in the number of cases of microcephaly at the end of 2015, the Brazilian Ministry of Health and Brazilian states have escalated their investigation. Since October 2015, of 6,776 cases reported nationwide, 4,291 suspected cases of microcephaly related to Zika virus infection are undergoing investigation. A bulletin released on March 26, 2016, also indicated that there are 944 confirmed cases of microcephaly and/or other central nervous system (CNS) disorders, suggestive of congenital infections. Another 1,541 reported cases presented normal test results or were confirmed to have non-infectious causes[5].

Since October 2015, a total of 208 deaths related to microcephaly or CNS alterations have been reported following stillbirth or during pregnancy (miscarriage or stillbirth). Of these, 47 cases were confirmed to be associated with Zika virus infection; in 22 cases, this relation was eliminated, and another 139 cases are under investigation[5].

NORMAL NEUROLOGICAL EMBRYOLOGY

To better comprehend the genesis of microcephaly, it is necessary to understand the formation of the CNS and skullcap of an embryo. The CNS develops from the neural plate (part of the dorsal ectoderm) that invaginates and subsequently forms the neural groove, which has neural folds on each side. The neural folds begin to merge from the 4th week, forming the neural tube, which has open ends, i.e., rostral and caudal neuropores[6].

The cranial end of the neural tube forms the encephalon, the precursor of the prosencephalon, mesencephalon, and rhombencephalon. The prosencephalon forms the cerebral hemispheres and diencephalon, mesencephalon forms the adult mesencephalon, and rhombencephalon forms the pons, medulla oblongata, and cerebellum. The neural canal, represented by the lumen of the neural tube, becomes the

brain ventricles and the central canal of the medulla oblongata and spinal cord. The walls of the neural tube thicken due to the proliferation of its neuroepithelial cells, giving rise to all nerves and macroglial cells of the CNS[7].

The skull, in turn, originates from the mesenchyme of the neural crest around the developing brain. It comprises the viscerocranium and neurocranium. The viscerocranium composes the facial bones and arises from the first pharyngeal arches of the embryo. Consecutively, the neurocranium comprises the skullcap and skull base. The latter undergoes endochondral ossification, whereas the skullcap undergoes intramembranous ossification. The bones that form the skullcap are separated by the fibrous sutures of dense connective tissue (cranial sutures)[8].

These sutures are found only between the skull bones and limit their movements, but they impart certain elasticity to the skull. In the skulls of fetuses and newborns, in which ossification is incomplete, there are more interposed fibrous connective tissue, which explains the broader separation between the bones and greater mobility. The fibrous areas located at the points of union of the sutures are called fontanelles; during delivery, the fontanelles contribute to a large reduction of the fetal head volume by overlapping the skull bones, facilitating the expulsion of the fetus into the external environment[8].

Provided the sutures and fontanelles are open, an infant's brain can grow and develop, leading to normal head growth and intellectual development. Palpation of the sutures or fontanelles following their closure is impossible. Table 1 presents the mean age of closure of each suture and fontanelle.

EMBRYOLOGY OF MICROCEPHALY

Microcephaly is a neurological condition characterized by abnormalities in cranial growth usually presented as an abnormally reduced brain growth. It can be caused by defects in neurogenesis, synaptogenesis, and neuronal migration and is associated with macroscopic CNS malformations and cerebral parenchymal calcifications. These defects mainly occur in the first 4 months of gestation when genetic defects or the action of environmental agents (infectious, chemical, and nutritional) may interfere with the cortical development of the brain. Another frequent cause of microcephaly is craniostenosis involving premature closure of the cranial sutures, which may also be related to environmental and genetic causes[9,10].

In a recent study conducted at Duke University in the United States (2015), the development of neural cells in mice was analyzed and some defects that may explain microcephaly were identified. The researchers argued that this malformation in fetuses is mainly caused by a slow division of neuronal progenitor cells fated to become neurons. Slower mitosis results in fewer neurons, and the formed neurons are more likely to die[9,10].

In general, scientists believe that this brain malformation is caused by several concurrent problems, namely, reduced production of progenitor cells, slow production of these cells, and an abnormal "preference" of directly differentiating into neurons without first passing through the stage of intermediate cells, which divide up to three more times before becoming neural cells[9,10].

According to these scholars, Zika virus also possibly causes this delay in cell division during neuronal formation, although this hypothesis has not been proven as yet. The mechanism of lesion formation by congenital infections, including that by Zika virus, has not yet been completely elucidated, but it appears to involve the mechanisms of early meningoencephalitis and vasculitis with changes in neurogenesis, synaptogenesis, and neuronal migration[9,10].

Table 1. Average age of closure of each suture and fontanelle.

Type	Age at closure
Metopic	9 months to 2 years (may persist in adulthood)
Coronal, sagittal, and lambdoid	40 years
Anterior fontanelle	15–18 months
Posterior fontanelle	3–6 months
Anterolateral fontanelle	3 months
Posterolateral fontanelle	2 years

1. CLASSIFICATION OF MICROCEPHALY ACCORDING TO ITS ORIGIN

Microcephaly can be divided into primary and secondary forms[3].

Primary microcephaly is an expression of abnormal brain development in the initial months of gestation due to genetic/chromosomal or environmental anomalies. In secondary microcephaly, the brain completes its normal development but subsequently undergoes damage that disrupts its later growth. Normal CP at birth followed by failure of normal head growth generally indicates secondary microcephaly, although some genetic disorders are an exception to this rule.

The main causes of microcephaly are divided into the following: genetic, perinatal, postnatal, and environmental[3,9].

GENETIC CAUSES

True microcephaly

This term is used to describe the genetic defects of autosomal recessive inheritance that reduce brain volume with no alterations in its architecture. Patients present evident microcephaly in the neonatal period and a non-progressive intellectual deficit[3,10]. Genetic alterations lead to a change in mitosis in neurons, subsequently leading to decrease in brain volume[10].

Aicardi–Goutières syndrome

This genetic syndrome is characterized by cerebral atrophy, leukodystrophy, intracranial calcifications, chronic

lymphocytosis, and high interferon-alpha in cerebrospinal fluid. This syndrome is phenotypically similar to intrauterine viral infection; therefore, it is important to include it in the differential diagnosis. Clinical presentation may begin at a few weeks of age, with irritability and vomiting. Progressively, severe neurological manifestations are observed, including microcephaly, epilepsy, impaired neuropsychomotor development, and spasticity; one-third of the cases result in death during infancy[11,12].

Rett syndrome

This genetic disorder is caused by a mutation in the MECP2 gene and is clinically characterized by remarkable neuropsychomotor involution with progressive loss of previously acquired motor and language skills and acquisition of repetitive stereotypic hand movements, hypotonia, autonomic dysfunction, and moderate to severe mental retardation[13].

In the majority of cases, females are commonly affected typically between the 6th and 18th month of age[14].

After birth, a deceleration in cephalic measurements occurs that can be observed from 3 months to 1 year of age. It should be emphasized that a deceleration of the HC does not necessarily imply microcephaly; in many patients, CP may remain within normal parameters. A deceleration of weight and length gain is also observed. The hallmark of the classic form of the disease is stereotypic hand movements such as washing or twisting hands, clapping hands, squeezing or slapping, and hitting one of the hands on some other part of the body (usually the mouth). These movements tend to be exacerbated in exciting or stressful situations. The diagnosis is done using clinical suspicion and genetic confirmation[14].

Patau syndrome (trisomy 13)

Patau syndrome is the least common of the autosomal trisomies owing to its high-rate intrauterine mortality[15].

The anomalies frequently observed in Patau syndrome involve congenital malformations of the urogenital tract, cardiovascular system, craniofacial structures, and CNS. Growth retardation and severe mental retardation are observed along with facial phenotypes such as cleft lip and palate, microphthalmia, microcephaly, low ear implantation, prominent heel, arched feet, closed hands, and polydactyly[16].

Edwards syndrome (trisomy 18)

Edwards syndrome is characterized by the presence of an extra copy of chromosome 18 and is the second most common autosomal trisomy[16]. Its most common clinical manifestations include microcephaly, low weight for gestational age, mental deficiency, hypertonia, and growth retardation. Patients present cranial anomalies such as a prominent occiput, dysmorphia and low implantation of the ears, small palpebral fissures, micrognathia, short palatal arch, and microstomia. Other clinical characteristics include cardiac, renal, and pulmonary congenital malformations[15,17].

Down syndrome (trisomy 21)

Down syndrome is a congenital defect resulting from trisomy 21. It is the most frequent chromosomal disease among those that allow post-gestational survival. Its most common features are hypotonia; articular hypermobility; excess neck skin; flat face; eyes with oblique palpebral fissures; small and/or anomalous ears; bent fifth finger; increased distance between the first and second toes, sometimes with a vertical fold between them; tibial arch in the hallucal regions; large, protruding, and grooved tongue; a single fold in the palms; and a flattened occipital region. Microcephaly is observed in 85% of cases[18].

CRANIOSTENOSIS

Craniostenosis is a cranial asymmetry with premature fusion of one or more cranial sutures. It can be classified into two main types: (1) simple craniostenosis wherein only one suture is affected and (2) combined form wherein two or more sutures are affected and may or may not be related to certain genetic syndromes such as Apert and Crouzon syndromes[19]. In addition, they may be secondary to metabolic disorders such as hypothyroidism and mucopolysaccharidosis or fetal exposure to harmful substances. The associated risk factors include advanced maternal age, white maternal race, male sex, maternal smoking, mother living in high attitude regions, use of medications (nitrofurantoin, chlordiazepoxide, chlorpheniramine, valproic acid, and phenytoin) during pregnancy, and fertility treatments[3].

Table 2 describes the possible abnormal forms of the skull.

The shape of the head can be influenced *in utero* by constriction forces, such as a bicornuate uterus or presence of multiple fetuses, and by molding during vaginal delivery[3]. Thus, these asymmetries may originate from deformations or synostosis, and this should be the focus of differential diagnosis when assessing infants with such deformities[18].

It is worth mentioning that the incidence of deformity involving asymmetries has increased after 1992 following the American Academy of Pediatrics' "back to sleep" campaign, which recommends the placement of children in the supine position during sleep to prevent sudden death. The most common postural deformities are plagiocephaly and brachycephaly[18]. Therefore, differentiation between lambdoid synostosis and positional plagiocephaly is of utmost importance. In the latter, it is common to observe hair rarefaction in the region of greater pressure (occipital region). To prevent positional plagiocephaly, parents should be instructed to alternate the position in which the child is placed when asleep and to avoid using the car seat when the child is not present in the car[3].

Diagnosis of craniostenosis is clinical and confirmed by neuroimaging, and it is surgically treated. The best period for intervention is between the 3rd and 9th months of age[3].

Table 2. Possible abnormal forms of the skull.

Denomination	Phenotype	Early closed suture(s)
Acrocephaly or turricephaly	Tall, tower-like skull with vertical forehead	All or coronal + any other
Brachycephaly	Broad skull with lower forehead and flattened in the occipital area	Coronal and/or lambdoid
Oxycephaly	Pointed skull	Only one side of the head is affected
Plagiocephaly	Flattening on one side of the head	Coronal or lambdoid unilateral
Scaphocephaly	Abnormally long and narrow skull in profile	Sagittal (more common)
Trigonocephaly	Triangular skull with prominent vertical crest in the middle part of the forehead	Metópica

PERINATAL CAUSES

This group is associated with conditions such as hypoxic–ischemic encephalopathy, intracranial hemorrhage, and obstetric trauma. The affected children are born with a normal CP, and microcephaly is observed in the first 2 years of age. Common initial manifestations are neonatal encephalopathy and seizures[3].

POSTNATAL CAUSES

Children with chronic diseases and malnutrition present hypodevelopment. While complete growth is compromised, CP generally is less affected than height and weight. If the systemic disorder is not corrected, brain damage can occur, brain growth can delay, and CP may fall into the microcephaly range[3].

ENVIRONMENTAL CAUSES

In addition to congenital infections, discussed in the following section, drugs and toxic substances such as alcohol, tobacco, cocaine and other illegal drugs, antiepileptic drugs, mercury poisoning, and radiation are considered the environmental causes of microcephaly when mothers are exposed to them.

INFECTIOUS CAUSES

Some congenital infections have been completely or partially eradicated through public health measures, especially in developed countries. However, in less developed countries, congenital infections remain an important cause of childhood morbidity and mortality and of microcephaly[20].

The primary congenital infections that produce neurological manifestations comprise the TORCH syndrome, i.e., (t)oxoplasmosis, (o)ther agents, (r)ubella, (c)ytomegalovirus, and (h)erpes simplex. The main route of fetal infection is the transplacental route. However, due to the presence of microorganisms in the vaginal tract, fetal infection may occur via the ascending route and during the passage through the birth canal. Infections can produce destructive effects secondary to the mechanisms triggered by the inflammatory process; they can also induce teratogenic effects, causing a series of cerebral malformations[20].

In general, the neurological conditions are non-progressive and manifest as macro- or microcephaly, intracranial calcifications, chorioretinitis, developmental delay, motor deficits, mental retardation, and epilepsy. Because infections usually manifest in a similar manner, it is necessary to assess patients using laboratory, serological, and neuroimaging examinations[20].

Toxoplasmosis

In congenital toxoplasmosis, a fetus is contaminated via the transplacental route after primary infection of a pregnant woman who in turn becomes contaminated through the ingestion of undercooked meat or contact with cat feces. Mothers and fetuses are usually asymptomatic, and the severity of fetal infection depends on the gestational period during which the infection occurred. It most commonly occurs during the last trimester, but it is most severe when it occurs in the first 6 months of gestation. Pneumonia, myocarditis, and hepatitis are the common symptoms of third-trimester infections, although they are usually asymptomatic. Jaundice, anemia, thrombocytopenia, chorioretinitis, and lack of weight gain can also be observed. However, if the infection occurs in the second trimester, prematurity and central involvement may be more evident including encephalitis, convulsions, cerebrospinal fluid pleocytosis, and intracranial calcifications. Sabin's tetrad, which may be present, comprises microcephaly with hydrocephalus, chorioretinitis (most common clinical finding), cognitive delay, and cerebral calcifications[20-22].

The diagnosis is primarily based on serological tests. When the suspicion is late, serology can be complemented by an IgG avidity test and polymerase chain reaction (PCR). Diffuse calcifications are observed on transfontanellar ultrasonography and cranial tomography. Fetal magnetic resonance, with maternal serology, facilitates prenatal diagnosis[21,22].

Prevention is the best course; seronegative pregnant women should only eat well-cooked food and avoid contact with cats. Treatment includes administration of spiramycin, pyrimethamine, sulfadiazine, and folic acid through different drug combinations and for variable periods, with few side effects and good prognosis. In children born with infection (symptomatic or not), the same drugs can be used.

Rubella

Rubella used to be one of the most common and feared congenital infections, accounting for numerous cases of deafness, blindness, encephalopathy, and cardiopathy. Currently,

the situation has changed owing to vaccination available at all Brazilian healthcare units, with a significant decrease in cases of congenital rubella[20,23].

Its transmission is transplacental, and pregnant women are normally asymptomatic. Infected newborns are also asymptomatic or oligosymptomatic, but some evidence of the disease may be observed in the initial years of life as a result of prolonged viremia. Neurological impairment is related to the infection in the first 4 months of gestation. The rubella virus produces inflammatory and teratogenic effects, and it can interfere with neuronal proliferation. Thus, microcephaly is believed to be caused by a decrease in the number of neurons and glial cells. Common neurological manifestations include microcephaly, mental retardation, and epilepsy. Furthermore, microphthalmia, chorioretinitis, hearing loss, behavioral disorders, cardiopathy, and involvement of the reticuloendothelial system may be observed[20].

The rapidest and most useful method of its diagnosis is detection of specific IgM levels in blood during the initial weeks of age. A late diagnosis can be done through other serological tests and virus isolation in the urine, cerebrospinal fluid, feces, and eye lens until the second year of life. In addition, neuroimaging changes can be observed[20].

Prevention through vaccination is the optimal method to avoid congenital rubella. The treatment of affected children is supportive and aims to reduce the possible deficiencies observed in each case[20].

Cytomegaly

Cytomegalovirus infection, also called as cytomegalic inclusion disease, is the most prevalent congenital infection. The infection pathway is transplacental, and it may be the result of a primary maternal infection or reactivation of a previous infection. Infection can also occur through the birth canal or breastfeeding, and these cases are more often symptomatic.

The neurological signs and symptoms are caused by the inflammatory process and teratogenic effect; polymicrogyria is observed in most cases. Microcephaly, periventricular calcifications, and chorioretinitis are common manifestations and may be observed from birth or become apparent later. Furthermore, motor development delay, mental retardation, epilepsy, hypoacusis of varying degrees, learning difficulties, and behavioral deficits are observed. In most cases, neurological impairment is static, but it may be progressive, and new alterations in neuroimaging tests are observed over time[20]. It is the main differential diagnosis with congenital Zika virus infection.

Cytomegalovirus can be isolated from urine samples, which is the rapidest method; the microorganism can also be isolated through culture or antigen detection, a method that takes days or weeks, or viral DNA screening by PCR, in less than 24 h. Moreover, serological tests and neuroimaging tests may be useful[20].

Currently, there are no effective preventive measures, and a vaccine is still in the experimental phase. However, acyclovir can be used for the treatment of infected children, with good results for prevention or reduction of auditory deficit. Further, rehabilitation therapies are recommended, preventing or alleviating complications of encephalopathy[20].

Herpes simplex infection

Most herpes infections are of neonatal origin and are acquired at birth when the child has contact with herpetic vesicles located in the maternal vaginal tract. Maternal infection may be asymptomatic or symptomatic and primary or reactivated, and the maternal serological condition is important for determining the risk of neonatal infection. Pregnant women with recent infections are more likely to infect their children. Infection may also occur via the ascending or transplacental routes[20].

The herpesvirus found in neonatal forms is type 2 virus, representing one of the most symptomatic congenital infections. The manifestations vary from localized disease, with vesicles on the scalp or in the gluteal region in those with cephalic or pelvic presentation, respectively, to disseminated forms, with involvement of organs and systems. The nervous system is compromised by inflammation; the onset of symptoms occurs on the 10th day following birth, with irritability, meningeal signs, seizures, and coma. Those who manage to survive present severe sequelae such as microcephaly, mental retardation, epilepsy, and motor deficits[20].

For diagnosis, it is important to observe the presence of herpetic vesicles. Furthermore, viral isolation, screening for cytopathic effects produced in cultured cells from gallbladder samples, and serological studies can be performed. Cerebrospinal fluid analysis, electroencephalography, and neuroimaging are important examinations in the assessment of neurological manifestations, with high morbidity and mortality[20].

For prevention, cesarean delivery is indicated when herpetic vesicles are visualized in the genital tract. Nonimmune pregnant women should abstain from sexual intercourse if their partners have genital herpes. In particular, in the third trimester, repeated serologies should be performed to identify a possible primary infection. Aciclovir therapy is indicated in suspected neonatal infections. Anticonvulsants and intensive care treatment may also be required[20].

Congenital syphilis

Epidemiological surveillance and the use of penicillin have resulted in a reduction of cases of congenital syphilis. *Treponema pallidum* infects fetuses through the placenta mainly in the second and third trimester; fetal impairment is more intense at earlier stages of untreated maternal infection and during longer exposures to the infectious agent.

Involvement of the nervous system is of the inflammatory type, and neurological manifestations are divided

into early (from birth to 2 years of age) and late (after 2 years of age). Early manifestations include meningoencephalitis, cranial nerve injury, hydrocephalus, and cerebrovascular injury, whereas late manifestations include optic atrophy and deafness, general and progressive paralysis, juvenile tabes dorsalis, microcephaly, stigmas (Hutchinson's teeth, saddle nose, "Olympian brow," saber tibia, and rhagade), and hypersensitivity reactions (keratitis and deafness).

Diagnosis is most commonly done using serological tests such as VDRL in addition to FTA-ABS, preferably selected due to its higher specificity and sensitivity. Infection is confirmed by serial testing with persistent positive results as maternal antibodies may be passed to the child. Presence of *T. pallidum* on dark-field microscopy in samples obtained from skin lesions or other organic fluids is also an indication for diagnosis. Neurological impairment is confirmed with a CSF study[20,24].

Preventive measures are crucial using STD awareness campaigns and quality prenatal care with early infection screening and treatment of pregnant women and their partners. Newborns with suspected infection should be administered crystalline or procaine penicillin; doses and treatment duration are determined by the presence or absence of clinical manifestations and history of treatment undergone by the mother[20].

Acquired immunodeficiency syndrome

Vertical HIV transmission is common, occurring in 30% of infected pregnant women via the transplacental route through the passage of the child during delivery or breastfeeding. Clinical manifestations are often not observed for a long time and are more related to the host's immune response capacity than to the inflammatory effects of congenital infection. The neuropathological signs of meningoencephalitis, cerebral atrophy secondary to neuronal and glial loss, vasculopathy, loss of myelin in the medulla, and stroke-like alterations may be observed.

Symptomatic cases behave as static or progressive encephalopathies, with an overall developmental delay, acquired microcephaly, motor deficits, and mental retardation of different degrees. In more compromised patients, cerebellar signs, signs of extrapyramidal involvement, and seizures may be observed. Furthermore, neuromuscular disease, opportunistic infections, and lymphomas may occur[20].

The Brazilian Ministry of Health considers a child to be infected after two positive samples are tested using viral culture methods, plasma viral RNA quantification, pro-viral DNA detection, and p24 antigen detection. If performing these tests is considered impossible before 18 months of age, infection should be considered in the presence of two positive serologies associated with suggestive clinical manifestations. In those aged over 18 months, infection should be considered in the presence of two positive ELISA tests using different methods[20].

To prevent the spread of the disease, the Brazilian Ministry of Health advocates the identification of infected pregnant women who should be prescribed antiretroviral drugs in prenatal care; antiretroviral chemoprophylaxis during delivery to the pregnant woman and newborn; and postnatal care of the mother and child. In the Brazilian Unified Health System, antiretrovirals are provided free of charge, facilitating a better quality of life and prolonged survival among infected children. Patients with encephalopathy also require rehabilitation to alleviate the consequences of neurological impairment[20].

RELATIONSHIP WITH ZIKA VIRUS

Zika is a RNA virus belonging to the *Flaviviridae* family that presents a clinical picture similar to that of dengue fever. The most common signs and symptoms are a rash (often maculopapular), fever, arthralgia, myalgia, headache, and conjunctivitis. Occasionally, edema, sore throat, cough, vomiting, and diarrhea may occur. Its symptoms are self-limiting for 3–6 days. The main route of transmission is through the bite of the *Aedes aegypti* mosquito. The incubation period ranges from 3–6 days after the bite of the infected mosquito[25,26].

The Brazilian Ministry of Health has confirmed the association between Zika virus infection and occurrence of microcephaly. The virus was isolated by the researchers of the Evandro Chagas Institute in blood and tissue samples from a newborn infant with microcephaly and other congenital malformations in Ceará.

The complications of Zika virus infection are still not well understood. Recently, the Brazilian Ministry of Health associated this infection with cases of microcephaly and Guillain–Barré syndrome. Further research on microcephaly and its relationship with Zika virus should clarify issues such as the transmission of this agent and its action in the human body. Zika screening was included by the Brazilian Ministry of Health in the management protocol for microcephaly cases in the country. Treatment for the virus is symptomatic[25,26].

In other countries in the Americas, cases of Zika virus infection have also been recorded. The Pan American Health Organization released an epidemiological update reporting that 18 countries and territories confirmed local transmission: Brazil, Barbados, Colombia, El Salvador, Ecuador, Guatemala, French Guiana, Guyana, Haiti, Honduras, Martinique, Mexico, Panama, Paraguay, Puerto Rico, Saint Martin, Suriname, and Venezuela. In light of the estimate that, in 2016, 3–4 million cases of Zika virus infection would be registered worldwide and considering the strong suspicion of its relation to cases of microcephaly and neurological syndromes, Margaret Chan, Director-General of WHO, announced the creation of an International Health Regulations and Emergency Committee on 28th January that year[25].

Occurrence of severe fetal brain damage associated with infection with vertical transmission is well established.

Recently, Zika virus was found in the amniotic fluid of fetuses with microcephaly, consistent with intrauterine transmission. Potential damage to the placenta caused by the virus has also been demonstrated. Among the few reports of the teratogenic effects of flaviviruses, studies have indicated the brain and eyes to be the primary targets. The virus has not been detected in any fetal organ other than the brain, and no pathological alterations have been observed outside this organ, suggesting a strong neurotropism of the virus.

The location of the immunofluorescence signal and morphological appearance of calcifications, resembling destroyed neuronal structures, indicate a possible location of the virus in neurons. As a consequence, this infection can halt the development of the cerebral cortex at the embryonic age of approximately 20 weeks. The mechanism involved in Zika's neurotropism remains unclear. The number of viral copies detected in fetal brain is substantially higher than that reported in the serum samples of adult patients infected with Zika virus[27].

There is no indication for changing the delivery route, i.e., Zika virus infection or microcephaly per se are not indications for a cesarean section. Further, it is important to note that an unnecessary cesarean delivery increases the risk of complications for mothers and infants[25].

The Brazilian Ministry of Health has also stated that surveillance and appropriate care to children with microcephaly should continue to be prioritized; therefore, it has released protocols for surveillance, healthcare, and response to cases of microcephaly related to Zika virus infection in addition to a protocol for early stimulation of children with microcephaly. Furthermore, the ministry has made efforts and resources available for this purpose. The federal government set forth strategies for assessing microcephaly.

Despite the decline in fecundity, approximately 3 million births still occur in Brazil annually. With the rapid spread of the Zika virus epidemic, the main suspected causative agent of microcephaly, it is possible to expect a growth in the prevalence of this infection, despite the comprehensive measures being undertaken to prevent its transmission[28].

The serious microcephaly epidemic highlights the urgent need for substantial investments aimed at improving the living conditions of urban populations in Brazil. On one hand, the lack of water distribution into households leads to domestic storage, creating breeding grounds for mosquitoes; on the other hand, rainfall favors water accumulation in precarious households or at dumpster sites, creating favorable environments for vector proliferation. A massive implementation of solid waste selective collection programs, with adequate separation and destination of recyclable waste, is an important measure not only for vector control but also from an environmental perspective. Open sewers and dumping grounds are other inexhaustible sources of breeding grounds for *A. aegypti* and other vectors, and these must be eliminated. It is worth mentioning that increased access to water and sanitation are paramount for the prevention of arbovirus; these measures are also associated with a higher life expectancy and lower mortality and have positive impacts on infant, child, and maternal mortality[29].

Publishing reliable and timely information is essential for guiding healthcare professionals and the general population. To this end, *Epidemiology and Health Services: a Journal of the Brazilian Unified Health System* (in Portuguese, *Epidemiologia e Serviços de Saúde: Revista do Sistema* Único *de Saúde do Brasil*) is an important instrument; it publishes articles that can contribute to the improvement of health surveillance actions related to vector control, arbovirus infection, and microcephaly[29].

According to the Secretariat of Health Surveillance's protocol (2015), laboratory assessment should be based on non-specific blood count tests, serum AST/TGO and ALT/TGP levels, serum bilirubin levels, direct and indirect serum bilirubin dose, serum lactate dehydrogenase and other markers of inflammatory activity (C-reactive protein and ferritin), echocardiography, ophthalmologic evaluation with ocular fundus examination, otoacoustic emission examination, abdominal ultrasound, and cranial computed tomography without contrast. The specific laboratory diagnosis of Zika virus is based mainly on the detection of viral RNA from clinical specimens. The viremic period remains partially established, but it is believed to be of short duration. Therefore, it would be possible to directly detect the virus within 4–7 days following the onset of symptoms. However, it is recommended that the examination of samples is ideally performed by the 5th day following the onset of symptoms. In Brazil, the recommended test for confirmation of Zika virus is reverse transcriptase PCR performed at reference laboratories of the Brazilian Unified Health System network.

ALGORITHM

In light of the content discussed in this study, the authors propose the following algorithm for the causal diagnosis of microcephaly Figura 1.

CONCLUSION

Considering the current status of increased prevalence of Zika virus infection and its relation with congenital microcephaly, many other causes of this alteration have been neglected.

The authors conclude that, in this context, it is extremely important to be aware of the other possible causes of malformation and to disseminate knowledge about them as well as to create a sequenced diagnostic method to prevent errors and avoid misdiagnosis of the actual cause of microcephaly in each patient.

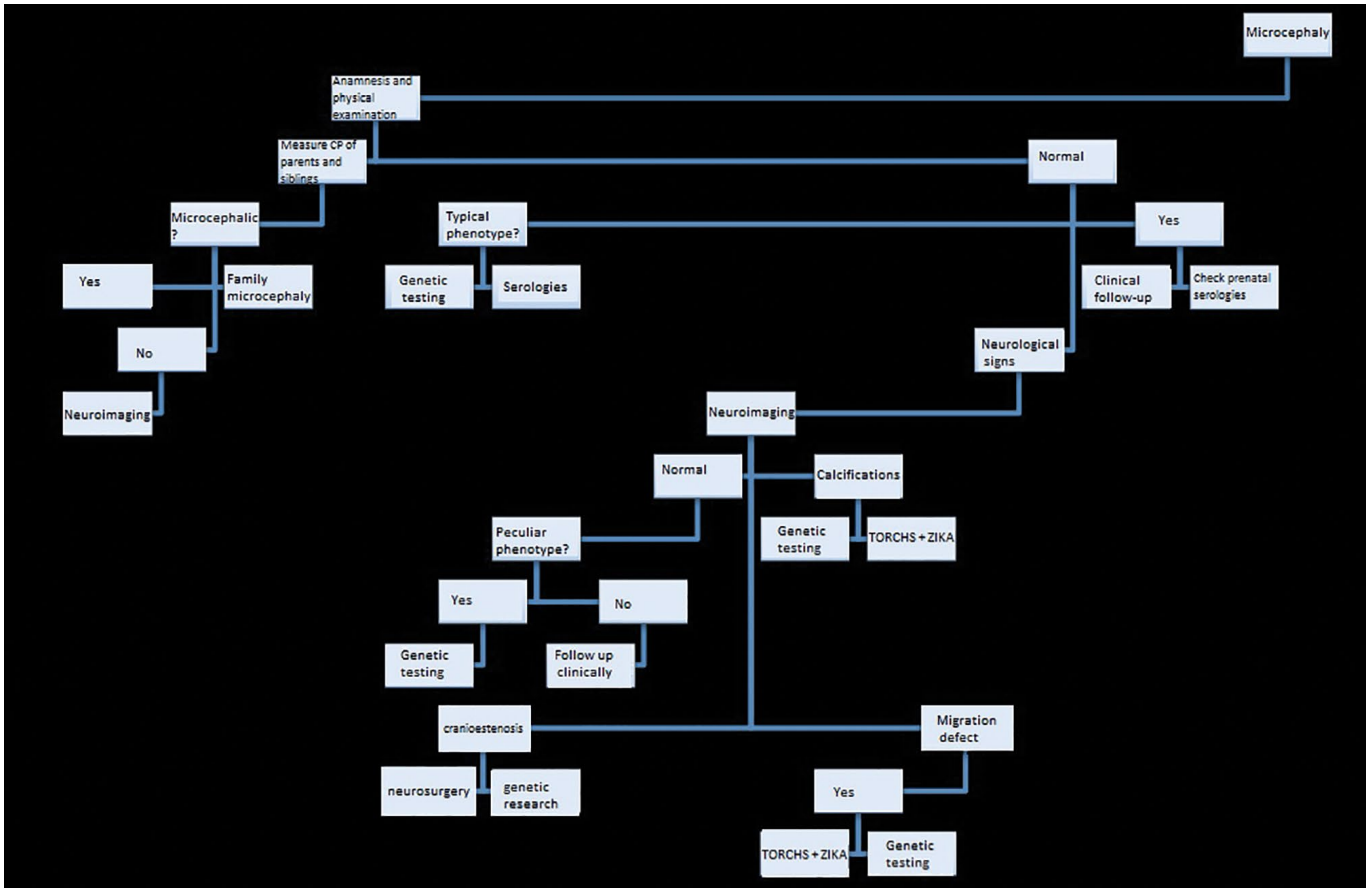

Figure 1. Causal diagnosis of microcephaly.

REFERENCES

1. Reis RP. Aumento dos casos de microcefalia no Brasil. Rev Med Minas Gerais. 2015; 25(Supl 6):88-91.
2. Brasil. Ministério da Saúde. Protocolo de Vigilância e resposta à ocorrência de microcefalia e/ou alterações do Sistema Nervoso Central (SNC). Brasília-DF. Atualizado em 09/12/2015.
3. Araújo APQC, Fortes CPDD, Trindade ROC. Alterações de tamanho e formato do crânio. In: Bases da Pediatria. 1 ed. São Paulo: Editora Rubio; 2013.
4. OPAS. Organização Pan-Americana de Saúde. Manual para vigilância do desenvolvimento infantil no contexto da AIDIPI. Washington, DC: OPAS, 2005. Série OPS/FCH/CA/05.16.P.

5.Brasil. Ministério da Saúde. Microcefalia: Casos em Investigação chegam a 3.935 no País. Disponível em: < http://portalsaude.saude.gov.br/index.php/cidadao/ principal/agencia-saude/22202-microcefalia-casos-em-investigacao-chegam-a-3-935-no-pais>. Acesso em: 21 de abril de 2016.

6. Moore KL. Embriologia clínica. 9 ed. Editora Elsevier; 2013.
7. Garcia SML, Fernandez CG. Embriologia. 3 ed. Editora Artmed; 2012.
8. Dumm CG. Embriologia humana. 1 ed. Editora Guanabara Koogan; 2006.
9. Carod-Artal FJ. Epidemiología y complicaciones neurológicas de la infección por el vírus del Zica: um nuevo vírus neurotropo emergente. Rev Neurol. 2016; 62(7):317-28.
10. Faheem M, Naseer MI, Rasool M, Chaudhary A, Kumosani TA, Ilyas AM, Pushparaj PM, Ahmed F, Algahtani HA, Al-Qahtani MH , Jamal HS. Molecular genetics of human primary microcephaly: an overview. BMC Medical Genomics. 2015; 8(Suppl 1):S4.
11. Juarez ALF, Pozón LS, Prades AM, Planac JC, Ribera RP. Síndrome de Aicardi-Goutières. Barcelona: An Pediatr. 2008; 68(1):70-82.
12. Crow YJ, Vanderver A, Orcesi S, Kuijpers TW, Rice GI. Therapies in Aicardi-Goutières syndrome. Clin Exp Immunol. 2014 Jan; 175(1):1-8.
13. Feldman D, Banerjee A, Sur M. Developmental dynamics of Rett syndrome. Neural Plasticity. Volume 2016, ID 6154080, 9 pag.
14. Sociedade Brasileira de Síndrome de Rett. Síndrome de Rett. Disponível em: <http://www.abrete.org.br/sindrome_rett.php>. Acesso em: 25 de abril de 2016.
15. Borges-Osório MR, Robinson WM. Genética humana. 2 ed. Editora Artmed; 2001.
16. Thompson JS, Thompson MW. Genética médica - Thompson & Thompson. 6 ed. Rio de Janeiro: Editora Guanabara Koogan. 2008; 388p.
17. Wink DV, Paz FS, Machado RB, Wittmann R. Síndrome de Edward. Trabalho de Conclusão de Curso. Fundação Faculdade Federal de Ciências Médicas. Porto Alegre – RS; 2001.
18. Siqueira V. Síndrome de Down: translocação robertsoniana. Saúde & Ambiente em Revista. 2006; 1(1):23-29.
19. Pinto FCG, Matarazzo CG. Assimetria craniana: cranioestenose ou plagiocefalia posicional? Blucher Medical Proceedings. 2014; 1(4).
20. Aires V. Práticas pediátricas. Editora Atheneu. 2006; 119p.
21. Amorín B, Pérez L, Martinez L. Seguimiento clínico y serológico de recién nacidos con igm materna reactiva para toxoplasmosis. Policlínica de Infectología Pediátrica. Hospital Escuela Del Litoral, Paysandú. Años 2008-2013. Arch Pediatr Urug. 2015; 1(86)14-25.

22. Brasil. Ministério da Saúde. Secretaria de Vigilância em Saúde. Departamento de Vigilância Epidemiológica. Doenças infecciosas e parasitárias: guia de bolso. Brasília: Ministério da Saúde, Secretaria de Vigilância em Saúde, Departamento de Vigilância Epidemiológica. 8 ed rev; 2010.
23. Brasil. Ministério da Saúde. Secretaria de Vigilância em Saúde. Departamento de Vigilância Epidemiológica. Brasil livre da rubéola: campanha nacional de vacinação para eliminação da rubéola, Brasil, 2008: relatório. Ministério da Saúde, Secretaria de Vigilância em Saúde, Departamento de Vigilância Epidemiológica. Brasília: Ministério da Saúde. 2009; 196p.
24. Brasil. Ministério da Saúde. Secretaria de Vigilância em Saúde. Programa Nacional de DST e Aids. Diretrizes para o Controle da Sífilis Congênita. Ministério da Saúde, Secretaria de Vigilância em Saúde. Programa Nacional de DST e Aids. Brasília: Ministério da Saúde; 2005.
25. WHO. World Health Organization. WHO to convene an International Health Regulations Emergency Committee on Zika virus and observed increase in neurological disorders and neonatal malformations. Geneva: World Health Organization; 2016.
26. Luz KG, Santos GIV, Vieira RM. Febre pelo vírus Zika. Epidemiol Serv Saúde. 2015; 24(4):785-88.
27. Musso D, Roche C, Robin E, Nhan T, Teissir A, Cao-Lormeau VM. Potential sexual transmisson of Zika vírus. Emerg Infect Dis. 2015; 21:359-361.
28. Maranhão AGK, Vasconcelos AMN, Zoca B, Porto D, Poncioni I, Lecca R. Como nascem os brasileiros. In: Ministério da Saúde (BR). Secretaria de Vigilância em Saúde. Departamento de Vigilância de Doenças e Agravos Não Transmissíveis e Promoção da Saúde. Saúde Brasil 2014: uma análise da situação de saúde e das causas externas. Brasília: Ministério da Saúde; 2015.
29. Mujica OJ, Haeberer M, Teague J, Santos-Burgoa C, Galvão LAC. Health inequalities by gradients of access to water and sanitation between countries in the Americas, 1990 and 2010. Rev Panam Salud Publica. 2015; 38(5):347-354.
30. Crow YJ, Vanderver A, Orcesi S, Kuijpers TW, Rice GI. Therapies in Aicardi-Goutières syndrome. Clin Exp Immunol. 2014 Jan; 175(1):1-8.