Residência RP Pediátrica
Publicação Oficial da Sociedade Brasileira de Pediatria
ISSN-Online: 2236-6814

Submitted on: 26/07/2018
Approved on: 26/04/2019

ORIGINAL ARTICLE

Periodontitis caused by Actinomyces spp. in a child with Ascaris lumbricoides and Trichocephalus trichiurus: a case report

Mariana Mundim Rocha Oliveira[1], Isabela Torga Mazzei[2], Mariana Tschoepke Aires[3], Analucia Mendes da Costa[4], Elgita Aparecida Diniz[5]

Keywords:
Periodontitis,
Ascaris lumbricoides,
Actinomyces.

Abstract

Actinomyces spp. is a gram-positive facultative anaerobic bacteria, normal to the oral cavity endogenous flora. Infections caused by Actinomyces spp., especially cervicofacial actinomycosis, are rare in children. This article aims to present a case of periodontitis caused by Actinomyces spp. in a 03 years old multi-parasitized child, and to discuss the eosinophilia interaction and the immune response to the parasites.

[1] Medical Student. Health School. Potiguar University, Natal, RN, Brazil.
[2] Medical Graduate. Varela Santiago Children's Hospital, Natal, RN, Brazil.
[3] Medical Graduate. Onofre Lopes University Hospital. Rio Grande do Norte Federal University, Natal, RN, Brazil.
[4] Master's Degree in Maternal Infant Health. Department of Pediatric Medical Residency. Varela Santiago Children's Hospital, Natal, RN, Brazil.
[5] PhD in Infectious and Parasitic Diseases. Department of Infectious Diseases. Rio Grande do Norte Tropical Medicine Institute. Rio Grande do Norte Federal University, Natal, RN, Brazil.

Correspondence to:
Nathalia Rayane Wanderley.
Hospital Infantil Varela Santiago, Residência de Pediatria. Av. Deodoro da Fonseca, nº 518, Centro.
Natal/RN - Brazil. CEP: 59.025-600. E-mail: nathaliaray.wanderley@gmail.com

INTRODUCTION

Actinomyces spp. is a gram-positive facultative anaerobic bacteria, normal to the oral cavity endogenous flora[1]. Current literature describes 47 species[2], and *Actinomyces israelii* is among the most prevalent ones[1] and can be found in mucous membranes, mainly in the oral cavity, colon and urogenital tract[3,4]. Infections caused by *Actinomyces spp.*, especially cervicofacial actinomycosis, are rare in children but they can affect any age, most frequently affecting girls in association with fever and pain[5].

Actinomyces spp. strains are predominant in periodontal tissue, both in physiological and inflammatory conditions[6]. Bacteria is usually established in stones, periodontal pockets, carious lesions, teeth and oral mucous membrane[7].

Diagnosis is given by the histopathological confirmation of sulfur granules, positive culture and/or isolation of the *Actinomyces spp.* species[5]. Periodontal lesions caused by infections by such agent are ideally treated with penicillin.

This article aims to present a case of periodontitis caused by *Actinomyces sp.* in a 3 years old multi-parasitized child, and to discuss the eosinophilia interaction and the immune response to the parasites.

CASE REPORT

A 3 years of age female child, born and living in the Northeast of Brazil, was admitted with ulcerative periodontal lesion in the upper gum (Figure 1), purulent, associated with claim of fever for two weeks.

Upon physical examination, patient presented a good general state, mild paleness, three centimeters hepatomegaly below the right costal margin and no skin or mucous membranes bleed. During hospitalization, the patient was submitted to a biopsy for culture of lesion.

Lab tests results were hemoglobin equal to 11.6 mg/dL; hematocrit equal to 36%; leukocyte count of 14,700/mm³ (25% of eosinophils, 35% of lymphocytes and 35% of segmenters); platelet count of 270,000/mm³; C-reactive protein lower than six; serum iron of 63 mcg/dL and stool test showed *Ascaris lumbricoides*, *Giardia lamblia*, *Endolimax nana* and *Trichocephalus trichiurus.* A skull CT scan was also performed and showed aspects of sinusitis, concha bullosa, deviated nasal septum and adenoid vegetation (Figure 2). Therapy was started with 8 ml of Albedanzole 40 mg/mL for five days, three days being administered at the hospital and the remaining at home.



Figure 1. Ulcerative periodontal lesion in the upper gum.



Figure 2. Computed tomography of the paranasal sinuses was also performed, showing aspects of sinusitis, bullous shell, deviated nasal septum and adenoid vegetation.

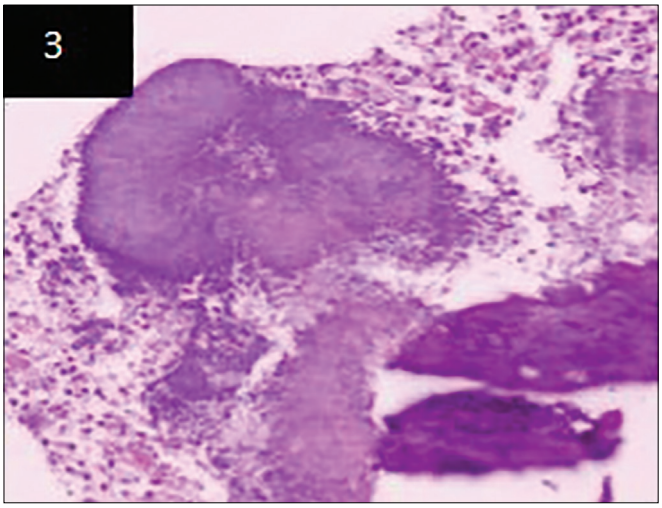

Figure 3. The biopsy showed bone tissue permeated by colonies of filamentous bacteria that suggested Actinomyces spp. and polymorphonuclear.

Thirteen days after hospital discharge, the biopsy showed bone tissue permeated with filamentous bacteria colonies that suggested *Actinomyces ssp* and polymorphonuclears (Figure 3). At that time, the patient was readmitted with two centimeters ulcerative lesions in both sides of upper gum, purulent discharge, without dental involvement, daily fever, pain after eating and enlargement of submandibular, anterior cervical and occipital lymph nodes, all with a fibroelastic appearance.

Treatment with a 5,000,000 UI dosage of intravenous Crystalline Penicillin every six hours was started. New lab tests were performed and their results were: hematocrit equal to 34.2%; leukocyte count of 18,200/mm³ (24% of eosinophils, 50% of lymphocytes, and 22% of segmenters; platelet count of 222,000/mm³; C-reactive protein lower than six; GOT: 41U/L; GPT: 12 U/L; sodium of 130 mEq/L and potassium of 4.5m Eq/L.

Patient clinical features improved with fever reducing since the beginning of therapy and ulceration regression.

Treatment plan is thirty days of crystalline penicillin followed by, at least, five months of amoxicillin.

DISCUSSION

The case presented sparks scientific interest as it introduces localized shapes of lesions by *Actinomyces spp.* in gingival region, which are extremely rare. In addition, the patient has no history of previous dental manipulation, traumatic lesions of oral mucosa, use of chlorhexidine gluconate oral rinse 0.12% nor poor oral hygiene that could justify the tissue destruction that caused the infection. The absence of such clinical features hampered the initial clinical suspicion and, therefore, the early diagnosis.

There was also no predisposing factors such as: male gender, diabetes mellitus, immunosuppression, alcoholism and malnutrition, which would corroborate to explain the cervicofacial actinomycosis pathophysiological mechanisms[8-12].

One of the things that caught the authors' attention in this case was the presence of intestinal parasitism by *Ascaris lumbricoides* and *Trichocephalus trichiurus* and 25% of eosinophils. Eosinophilia has several causes. In developed countries it usually occurs by eosinophilic enteropathy and allergic immune disorder, however, in tropical countries and underdeveloped regions, one of the main causes is intestinal parasitism.

There is, in fact, the possibility that the immune response deviation to Th-2 might have predisposed the *Actinomyces spp*. multiplication and dissemination, since Th-2 response stimulates IgE production and eosinophils and mastocytes activity, for combating against extracellular bacteria and helminths[13]. Thus, IgE would be blocking neutrophils action, benefiting pathological reactions by *Actinomyces spp*. Unfortunately, it was not possible to measure IgE levels in the reported case.

Although Th-1 and Th-2 responses act in a balanced way, seeking for immune homeostasis, it is well known that an immune response deviated to Th-2, in infections caused by intracellular agents, is adverse to the host[14] since it increases susceptibility to infections and these organisms' proliferation and dissemination.

Regarding the intestinal parasitism caused by *Ascaris lumbricoides* and *Trichocephalus trichiurus*, infections caused by such helminths - together with several environment changes, such as coinfections, climate, diet and comorbidities and with polymorphism of the immune response to the host genes - can worsen or improve allergies and autoimmunity[15-17].

In addition, immune response to helminths is usually controlled by Th-2 together with an extended compartment of regulatory T cells (Treg), that modulates and dampens inflammation - creating a harsh environment to helminths while restoring the damages caused by the parasites, as opposed to type 1 inflammatory response which is oriented to bacteria and viruses microorganisms[18-21]. As Tregs play a dual role in infections by helminths, protecting the host from excessive inflammatory response to the infection or reducing protective immunity; it allows for infections to become chronic[22-25].

Therefore, the authors believe that another condition that could explain the described periodontitis is the helminthiasis occurrence, since it would reduce the protective immunity provided by the Tregs and, thus, triggering the infection.

Child recovery at the end of the treatment was certainly due to the use of Penicillin. In addition, it is possible that the albedanzole therapy eliminated parasites and modified the inflammatory response.

Finally, we conclude that this intestinal parasitism was the main factor behind the actinomycosis' severity.

REFERENCES

1. Valour F, Sénéchal A, Dupieux C, et al. Actinomycosis: etiology, clinical features, diagnosis, treatment, and management Actinomycosis: etiology, clinical features, diagnosis, treatment, and management. Infect Drug Resist. 2014;7:183–97
2. Claesson R, Sjögren U, Esberg A, Brundin M, Granlund M, Actinomycesradicidentisand Actinomyceshaliotis, coccoid Actinomycesspecies isolated from the human oral cavity, Anaerobe (2017)
3. Bowden GHW. Actinomyces. in Topley and Wilson's microbiology and microbial infections, edsBalows A., Duerden B.I., (Edward Arnold, London, England), 1998; 9th ed. 2:445–462.
4. Hall V, Collins MD, Hutson RA, Inganäs E, Falsen E,.Duerden B.I. 2003. Actinomycesoricolasp. nov., from a human dental abscess. Int J SystEvol. Microbiol. 2003;53:1515-1518.
5. Thacker SA, Healy CM. Pediatric cervicofacialactinomycosis: an unusual cause of head and neck masses. J. Pediatr. Infect. Dis. Soc.2014;3: e15–9.
6. Socransky SS, Haffajee AD. Dental biofilms: Difficult therapeutic targets. Periodontol 2000 2002;28:12-55.
7. Kaplan I, Anavi K, Anavi Y, Calderon S, Schwartz-Arad D. The clinical spectrum of Actinomyces-associated lesions of the oral mucosa and jawbones: Correlations with histomorphometric analysis. Oral Surg Oral Med Oral Pathol Oral RadiolEndod 2009;108:738-46.
8. Wong VK, Turmezei TD, Weston VC. Actinomicosis. BMJ . 2011; 343: d6099.
9. Schaal KP, Lee HJ. Actinomycete infections in humans - a review. Gene. 1992;115(1–2):201–211.
10. Brown JR. Human actinomycosis. A study of 181 subjects. Hum Pathol. 1973;4(3):319–330.
11. Holm P. Studies on the aetiology of human actinomycosis.ActaPatholMicrobiolScand Suppl. 1951;91:172–173.
12. Weese WC, Smith IM. A study of 57 cases of actinomycosis over a 36-year period. A diagnostic 'failure' with good prognosis after treatment. Arch Intern Med. 1975;135(12):1562–1568.
13. CRUVINEL, Wilson de Melo et al. Sistema imunitário: Parte I. Fundamentos da imunidade inata com ênfase nos mecanismos moleculares e celulares da resposta inflamatória (Immune System: Part I: Fundamentals of innate immunity with emphasis on molecular and cellular mechanisms of inflammatory response). Rev. Bras. Reumatol. 2010, vol.50, n.4, pp.434-447.
14. MACHADO, Paulo R. L.; ARAUJO, Maria Ilma A. S.; CARVALHO, Lucas and CARVALHO, Edgar M. Mecanismos de resposta imune às infecções (Immune Response Mechanisms to Infections). An. Bras. Dermatol. 2004, vol.79, n.6, pp.647-662.

15. McKay DM. Not all parasites are protective. Parasite Immunol 37: 324–332, 2015.
16. Santiago HC, Nutman TB. Human helminths and allergic disease: the hygiene hypothesis and beyond. Am J Trop Med Hyg 95: 746–753, 2016.
17. Smits HH, Everts B, Hartgers FC, Yazdanbakhsh M. Chronic helminth infections protect against allergic diseases by active regulatory processes. Curr Allergy Asthma Rep 10: 3–12, 2010.
18. Grencis RK. Immunity to helminths: resistance, regulation, and susceptibility to gastrointestinal nematodes. Annu Rev Immunol 33: 201–225, 2015.
19. Gause WC, Wynn TA, Allen JE. Type 2 immunity and wound healing: evolutionary refinement of adaptive immunity by helminths. Nat Rev Immunol 13: 607–614, 2013.
20. Maizels RM, Yazdanbakhsh M. Regulation of the immune response by helminth parasites: cellular and molecular mechanisms. Nat Rev Immunol 3: 733–744, 2003.
21. Allen JE, Maizels RM. Diversity and dialogue in immunity to helminths. Nat Rev Immunol 11: 375–388, 2011.
22. D'Elia R, Behnke JM, Bradley JE, Else KJ. Regulatory T cells: a role in the control of helminth-driven intestinal pathology and worm survival. J Immunol 182: 2340–2348, 2009.
23. Sawant DV, Gravano DM, Vogel P, Giacomin P, Artis D, Vignali DAA. Regulatory T cells limit induction of protective immunity and promote immune pathology following intestinal helminth infection. J Immunol 192: 2904–2912, 2014.
24. Smith KA, Filbey KJ, Reynolds LA, Hewitson JP, Harcus Y, Boon L, Sparwasser T, Hämmerling G, Maizels RM. Low-level regulatory T-cell activity is essential for functional type-2 effector immunity to expel gastrointestinal helminths. Mucosal Immunol 9: 428–443, 2016.
25. Taylor MD, LeGoff L, Harris A, Malone E, Allen JE, Maizels RM. Removal of regulatory T-cell activity reverses hyporesponsiveness and leads to filarial parasite clearance in vivo. J Immunol 174: 4924–4933, 2005.