Residência RP Pediátrica
Publicação Oficial da Sociedade Brasileira de Pediatria
ISSN-Online: 2236-6814

Submitted on: 10/25/2018
Approved on: 02/04/2019

CASE REPORT

Cor triatriatum: a rare and asymptomatic case

Maina Tavares Zanoni[1], Valeria Cardoso Alves Cunali[1], Valquiria Cardoso Alves Chagas[1], Kellen Cristina Kamimura Barbosa Silva[1], Fabiane Mendes de Souza[1], Cynthia Lorena de Moura Araújo[1]

Keywords:
Heart Diseases,
Heart Defects,
Congenital,
Pediatrics,
Cor Triatriatum.

Abstract

Cor triatriatum is a rare congenital malformation, which can present isolated or associated with other anomalies, asymptomatic or cause complications and death. This article reports a case of a term newborn admitted in the neonatal intensive care unit because of early respiratory distress, with the finding Cor triatriatum on echocardiogram. This patient did not have hemodynamic repercussion, so the management was conservative. This defect occurs because of a failure in the common pulmonary vein resorption during embryonic heart formation, generating an atrium divided by a membrane. When present, the clinical manifestations result from pulmonary venous obstruction and pressure overload in the heart and indicate the need for surgical correction. Having knowledge of this disease is important to enable appropriate diagnosis and management.

[1] Federal University of the Triangulo Mineiro, School of Medicine - pediatrics - Uberaba - MG - Brazil.

Correspondence to:
Maina Tavares Zanon.
Universidade Federal do Triangulo Mineiro. Avenida Getúlio Guarita, nº 130, Nossa Senhora da Abadia, 2° Andar, Uberaba, MG, Brazil. CEP: 38025-440. E-mail: mainazanoni@gmail.com

INTRODUCTION

Cor Triatriatum is a rare congenital malformation characterized by a membrane that anomalously divides the atrium. It is usually diagnosed in childhood. Few cases are asymptomatic and found only in adulthood.

In most cases, this malformation is associated with other congenital heart changes. In newborns and children, the clinical manifestations are usually related to the presence of complications, such as pulmonary artery hypertension, and the diagnosis is made by echocardiography. In symptomatic cases, treatment consists of surgical correction.

This article aims to report a clinical case of Cor Triatriatum in the neonatal period. Because it is an uncommon disease in clinical practice, addressing the issue can contribute to scientific knowledge of the medical community.

DESCRIPTION

Full-term newborn (NB), female, born by caesarean section due to induction failure, with gestational age of 38 weeks and 4 days. Difficult extraction, as there was a change of position from cephalic to pelvic during labor. He was born depressed, requiring resuscitation maneuvers, with good response after two cycles of positive pressure ventilation (PPV). APGAR scores of 2 and 9 in the 1st and 5th minute respectively. Birth weight of 3,015 grams. The maternal history is of a healthy mother, with a normal prenatal risk.

In the first minutes of life, the newborn developed early respiratory distress, requiring orotracheal intubation and was transferred to the care of a multidisciplinary team in a neonatal intensive care unit (ICU). Due to presumed early sepsis, we ordered complementary tests and started her on ampicillin and gentamicin.

Laboratory tests showed signs of current infection without organ dysfunction. The chest X-ray showed no significant changes. The echocardiogram was performed at three days of life (figure 1). It showed a Cor Triatriatum on the left, a membrane with a large orifice, without obstruction to the flow of pulmonary arteries, mild tricuspid and mitral reflux with systolic pressure in the right ventricle of 46 mmHg, indirect signs of increased pulmonary artery pressure, which was not measured, and an ejection fraction of 73%. Normal pulmonary venous drainage, without other changes seen on ultrasound. We looked for other malformations using transfontanelle and abdomen ultrasound, but did not detect any.

The patient presented hemodynamic instability, requiring the use of vasoactive amines for six days. He remained with invasive ventilatory support for five days, tolerating gradual reduction until supplemental oxygen suspension. You completed the 10-day antibiotic regimen. She was discharged from the neonatal ICU at 12 days of age.

She remained for eight days in the pediatric ward, to progress to an oral diet. She kept a good general health condition, eupneic in ambient air, exclusive under breastfeeding, with good suction. He was referred for outpatient follow-up with a pediatrician and pediatric cardiologist, who requested a new six-month-old echocardiogram and maintained a conservative approach, without the need for continuous medication use.

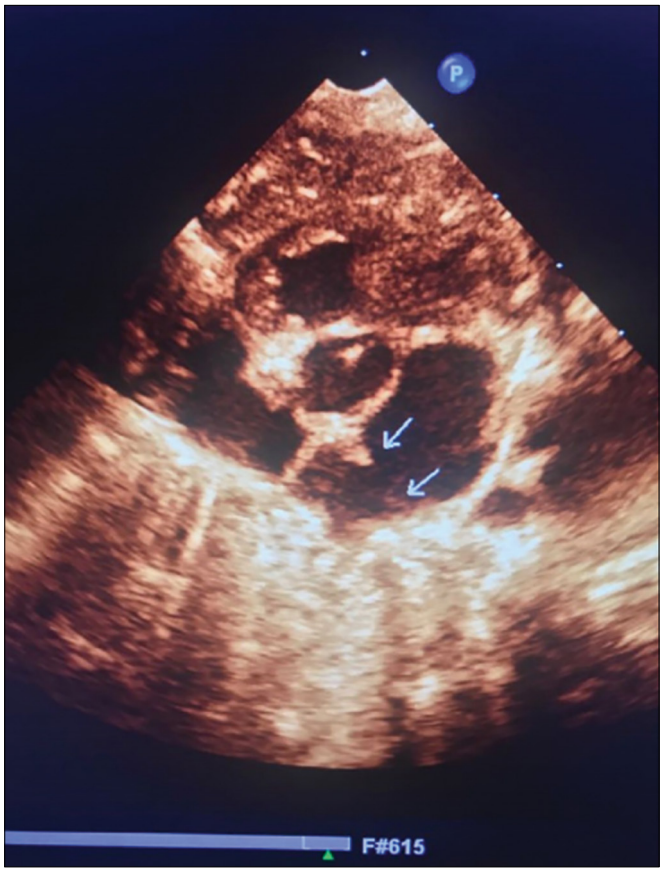

Figure 1. Image of the echocardiogram performed. Cor Triatriatum on the left, with a large orifice, without obstruction to the pulmonary artery flow. Arrows: Thin membrane on left atrial roof.

DISCUSSION

Color Triatriatum is a rare anomaly, accounting for 0.1% of congenital heart defects. A membrane divided the atria, which is more common on left than right[1]

This congenital malformation, initially described in 1863, is the result of a failure in resorption of the common pulmonary vein during embryonic heart formation[2]. It is often associated with other congenital cardiac abnormalities, such as: Interatrial Communication, Persistence of the Left Superior Vena Cava, Pulmonary Venous Return Anomalies, Fallot's tetralogy and Interventricular Communication[3,9]. In addition to other congenital abnormalities, such as: chromosomal alterations and respiratory diseases[4].

Depending on the degree of obstruction and association with other anomalies, the diagnosis may be earlier or later[5]. Cases with fenestrations with a diameter greater than 1

centimeter do not suffer hemodynamic changes and significant clinical repercussion until adulthood, as in the case reported above. However, in the presence of venous anomaly and/or minor fenestrations, the patient may develop symptoms related to pulmonary venous obstruction and pressure overload in the heart[6]. The onset and severity of symptoms depend essentially on the number and size of the fenestrations[3].

In cases of Cor Triatriatum associated with total anomalous pulmonary venous return, the prognosis is poor. About 75% of patients develop pulmonary edema, pulmonary hypertension, heart failure and death in the first months of life[7].

Cor Triatriatum is classified into three types. Type I consists of all four veins draining into the accessory chamber, which in turn communicates with the true chamber. Subtyping is based on the presence or absence of other connections with the accessory chamber. Type II indicates that the accessory chamber receives all four veins but does not communicate with the left atrium. Type III includes several subtypes according to the vein connections that do not connect to the accessory chamber[6].

Classic left Cor Triatriatum consists of a fibromuscular membrane dividing the left atrium into two chambers, one proximal, said accessory, which receives the pulmonary veins, and another distal, corresponding to the true left atrium, where the orifice of the atrial appendage and the mitral valve[8]. It is predominant in males and the main clinical manifestation is due to pulmonary hypertension, i.e., right ventricular enlargement, dyspnea, recurrent pulmonary diseases, developmental delay, retrosternal pain, physical disability and hemoptysis[5]. Changes in cardiac auscultation are usually not detected. When noticeable, there is hyperphonesis of the second sound in the pulmonary focus, left parasternal diastolic murmur and arrhythmias[7,9]. Increased cardiac chambers and long QT syndrome can be detected on exams[9].

Diagnosis is rare, especially in newborns. The discussion on the subject in the literature is limited[4,10]. Symptomatic and asymptomatic cases have been reported in adults and pediatric patients[2,3,5,11]. Most often, the diagnosis is late and an unexpected echocardiographic finding. In the reported case, because it was a premature infant with symptoms to clarify, echocardiography was performed and CorTriatriatum was a finding on examination. Echocardiography is considered the gold standard for diagnosis. Other imaging exams such as CT angiography and cardiac resonance may not be useful for detecting changes in cardiac anatomy[3,5].

Treatment in symptomatic patients is surgical. The first corrective surgery of this anomaly was performed in 1956 by Lewis[8]. When it generates hemodynamic repercussion, with heart failure and pulmonary congestion, its early diagnosis allows correction, which is most often performed urgently, and may prevent complications and death[10]. The most commonly used surgical procedure is the removal of the membrane that divides the atria, as well as the correction of other congenital malformations, if any[5]. When it does not produce symptoms, the treatment is expectant[1]. In the case described, due to the characteristics of the malformation, heart disease did not generate symptoms, allowing conservative management.

CONCLUSION

Cor Triatriatum is a congenital cardiac malformation, often identified late and asymptomatic. However, it may present as a significant defect or associated with other anomalies, evolving with complications and death. The case described was an echocardiogram finding, the main diagnostic test. It did not generate symptoms and therefore the treatment was conservative. Severe cases may require surgery. The case report presented is relevant because it is a rare pathology, little addressed in the medical literature. Knowledge about them allows early diagnosis and proper driving.

REFERENCES

1. Nassar PN, Hamadan RH. Cor triatriatum sinistrum: classification and imaging modalities. Eur J Cardiovasc Med. 2011 Jan;1(3):84-7.
2. Tasca R, Tasca MG, Amorim PA, Nascimento IC, Veloso OCG, Scherr C. Cor triatriatum em paciente adulta acompanhada durante a gestação. Arq Bras Cardiol. 2007 Mar;88(3):56-8.
3. Vasque RA Jr, Cunha AJB, Yared F, Masselli DB, Machado RL, Silva CES, et al. Cor Triatriatum em Paciente Adulto Assintomático. Arq Bras Cardiol: imagem cardiovasc. 2014; 27(2): 117-138.
4. Humpl T, Reineker K, Manlhiot C, Dipchand AI, Coles JG, McCrindle BW. Cor triatriatum sinistrum in childhood. A single institution's experience. Can J Cardiol. 2010 Ago/Set;26(7):371-6.
5. Işık O, Akyüz M, Ayık MF, Levent E, Atay Y. Cor triatriatum sinister: a case series. Turk Kardiyol Dern Ars. 2016 Jan;44(1):20-3.
6. Peng S, Xiao Y, Luo J, Chen R, Huang P, Liu P, et al. Cor triatriatum sinister: a rare underlying cause of pulmonary hemosiderosis. SpringerPlus. 2016;150:1-5.
7. Bolio-Cerdán A, Medina-Andrade MA, Romero-Cárdenas PR, Ruiz-González S, Luna-Valdez CM, González-Pena J. Cor triatriatum sinistrum: estratégia diagnóstica y terapêutica. Medigraphic Artemisa. 2007 Jan/Fev;64:29-34.
8. Halfman C, Thabet A, Blue R, Greenfield T. Cor triatriatum: case report of emergency department diagnosis. Clin Pract Cases Emerg Med. 2018 Aug;2(3):227-30.
9. Kehrl T, Dagen CT, Becker BA. Focused cardiac ultrasound diagnosis of Cor triatriatum sinistrum in pediatric cardiac arrest. West J Emerg Med. 2015 Sep;16(5):753-5.
10. Kadner A, Meszaros K, Mueller C, Schoenhoff F, Hutter D, Carrel T. Cor triatriatum sinister. Multimed Man Cardiothorac Surg. 2014 Mai;1(1).
11. Atik E, Tavares GMP. Cor triatriatum, sem manifestação clínica, em menina de 6 anos de idade. Arq Bras Cardiol. 2017 Mar;108(3):276-8.