Residência RP Pediátrica
Publicação Oficial da Sociedade Brasileira de Pediatria
ISSN-Online: 2236-6814

Submitted on: 12/11/2018
Approved on: 03/11/2019

CASE REPORT

Lemierre's syndrome in a systemic juvenile idiopathic arthritis patient under tocilizumab treatment

Larissa Elias Pinho[1], Carlos Nobre Rabelo Júnior[1], Marco Felipe Castro da Silva[1]

Keywords:
Lemierre's Syndrome,
Arthritis,
Juvenile,
Sinus Thrombosis,
Intracranial,
Immunosuppressive
Agents.

Abstract

Objective: To report a case of Lemierre's syndrome and briefly review the literature considering its rarity and the current presentation in a patient with systemic onset juvenile idiopathic arthritis under immunobiological medication. **Case report:** A 14-year-old boy previously diagnosed with systemic juvenile idiopathic arthritis using tocilizumab in monotherapy, presented oropharyngeal infection and poor response to first line antibiotics. Computed tomography and angiotomography of the cervical region showed improvement of abscess plus complete internal jugular vein thrombosis with sigmoid and transverse sinus extension. Broad-spectrum antibiotic was initiated in addition to full anticoagulation due to the extent and potential severity of the condition. He presented intracranial thrombosis resolution but maintenance of jugular vein thrombosis, with collateral veins development, and no further complications. **Discussion:** Lemierre's syndrome is a rare disorder, characterized by internal jugular vein thrombosis associated to history of recent oropharyngeal infection and its diagnosis hypothesis should not be overlooked in patients on immunosuppressive therapy, allowing early introduction of appropriate antibiotics and anticoagulation.

[1] Fortaleza General Hospital, Department of Pediatric Rheumatology - Fortaleza - Ceará - Brazil.

Correspondence to:
Larissa Elias Pinho.
Hospital Geral de Fortaleza. Rua Ávila Goulart, nº 900, Papicu, Fortaleza - CE. Brazil. CEP:60150-160. E-mail: larissaeliaspinho@gmail.com

INTRODUCTION

Juvenile idiopathic arthritis (JIA) is the main cause of chronic arthropathy in children and adolescents. Treatment includes synthetic or biologic disease-modifying antirheumatic drugs (DMARDs). In systemic juvenile idiopathic arthritis (SJIA), biologic DMARDs are prescribed as first or second-line therapy based on whether involvement is predominantly articular or extra-articular.

Infection is a potential complication in individuals on immunosuppressants and immunobiologicals. Biologic DMARDs etanercept, adalimumab, abatacept, tocilizumab, and canakinumab are prescribed to patients with JIA (Table 1). Anti-interleukin 1 and anti-interleukin 6 biologic DMARDs are prescribed to patients with SJIA.[1,2] Brazilian health authorities have cleared tocilizumab (anti-IL-6) and canakinumab (anti-IL-1) for use in the treatment of JIA.[3,4]

Lemierre's syndrome (LS) is characterized by septic thrombophlebitis of the internal jugular vein, a complication stemmed from infection in the oropharynx, ears, or nose. It is more common in younger male patients, and usually occurs in the second decade of life.[5-7] To our knowledge, there are no reports of cases of LS in individuals with JIA.

CASE REPORT

A 14-year-old male diagnosed with SJIA based on the International League of Associations for Rheumatology (ILAR)[8] criteria had been followed at the Pediatric Rheumatology Service since he was one year old. He had been in remission for two years on a prescription of monotherapy with tocilizumab. Two weeks before hospitalization, the patient had progressive odynophagia, fever, and a swollen neck. His workup showed leukocytosis and a high C-reactive protein level. Ultrasound examination found a neck abscess. The abscess was drained and the patient was started on ceftriaxone and oxacillin. His workup and clinical signs improved at first, but ten days later his neck was swollen again and his workup deteriorated. A computed tomography (CT) scan of the neck revealed a partially resolved abscess and complete thrombosis of the internal jugular vein extending into the sigmoid and transverse sinuses, later confirmed with neck and head CT angiography (Figures 1 and 2). Blood culture identified gram-negative elongated bacilli, although the species was not clear. The patient was prescribed broad-spectrum antibiotics (cefepime and metronidazole) and full anticoagulation with low-molecular-weight heparin. CT angiography performed two weeks later showed partial improvement from intracranial thrombosis and persistent complete thrombosis of the internal jugular vein. The symptoms subsided after six weeks of antibiotic therapy (four weeks on the drugs cited above and two weeks at the ward on amoxicillin-clavulanate). CT angiography of the neck and head performed six months later showed resolution of intracranial thrombosis and persistence of thrombosis in the internal jugular vein with development of collateral circulation. Anticoagulation was ceased six months later and the patient remained asymptomatic and complication-free 18 months into follow-up.

DISCUSSION

This paper reports the case of an adolescent with LS and SJIA that developed favorably after antibiotic and anticoagulant therapy. The diagnosis and treatment of LS can be challenging since it is a rare condition with little data on pediatric populations. This has been the only case of the disease seen in our service, in which more than a thousand patients, most of whom on immunosuppressants, are seen at any given time.

The incidence of LS decreased dramatically since the dissemination of antibiotics, to the point of earning the condition the "neglected disease" tag. However, increases in incidence have been observed within the last two decades, possibly as a consequence of increased microbial resistance to antibiotics, the publication of more studies on the disease,[5,9] and recommendations to decrease the use of antibiotics in ear and pharyngeal infections in pediatrics, since most have a viral etiology.[7] LS is a polymicrobial disease, involving gram-positive, gram-negative, and anaerobic bacteria. The bacteria more commonly associated with the condition is *Fusobacterium necrophorum*,[5,7] a challenging species to identify in common culture on account of its anaerobic properties,[6] whose morphology matched our patient's culture findings. Broad-spectrum antibiotics covering resistance to beta-lactams such as metronidazole, clindamycin, and piperacillin-tazobactam are

Table 1. Immunobiologicals cleared by ANVISA (Brazilian Health Surveillance Agency) to treat individuals with JIA.

Immunobiologicals	Mode of action	Side effects	Indications for JIA
Etanercept	TNF receptor fusion protein	Viral and bacterial infection, reactivation of latent tuberculosis infection, drug-induced lupus	JIA
Adalimumab	Human monoclonal antibody against TNF	Viral and bacterial infection, reactivation of latent tuberculosis infection, drug-induced lupus	Polyarticular JIA, enthesitis-related arthritis
Abatacept	CTLA-4 fusion protein	Viral and bacterial infection	Polyarticular JIA
Tocilizumab	Humanized monoclonal antibody against IL-6R	Viral and bacterial infection, dyslipidemia	Systemic and polyarticular JIA
Canakinumab	Human monoclonal antibody against IL-6R	Viral and bacterial infection	Systemic JIA

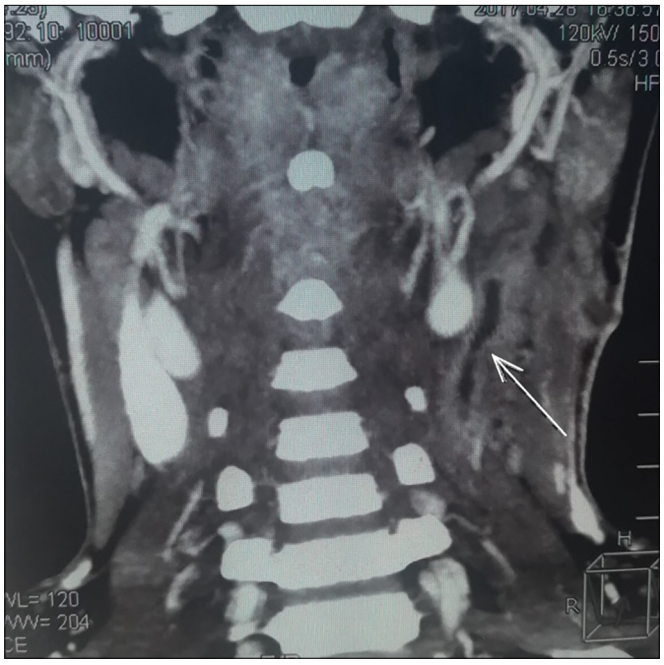

Figure 1. Neck contrast-enhanced computed tomography scan showing thrombosis in the left internal jugular vein (arrow).

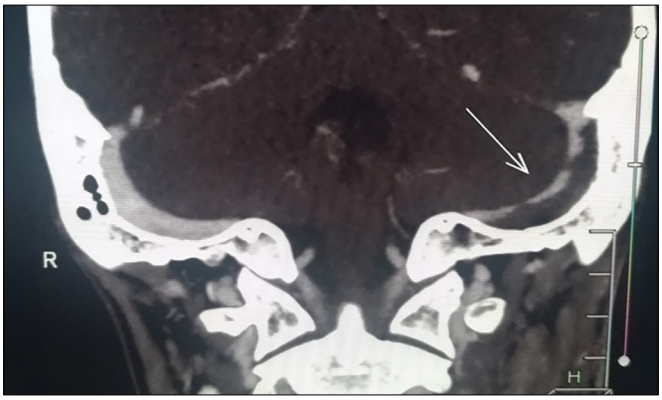

Figure 2. Contrast-enhanced computed tomography scan showing thrombosis in the left sigmoid sinus with extensive central venous thrombosis (arrow).

recommended.[5] Septic embolism with lung involvement[5,7] is a feared complication that causes cavitary infiltrate and empyema.[10] Primary oropharyngeal infection appears to be tied to worse progression, more significant embolism, and prolonged intensive care unit stays compared with other sites of primary infection.[9] There is no consensus on the use of anticoagulants on account of their questionable benefits.[5,10] Anticoagulants are prescribed to prevent lung complications such as respiratory failure and septic thrombophlebitis extending into the intracranial venous sinuses[10] based on personal experience or local protocols.[5] Considering the significant extent of thrombosis and the involvement of the central nervous system, anticoagulation was prescribed even though the patient did not present neurological symptoms. A recent study on pediatric LS found that 90.9% of the patients improved or had no imaging signs of thrombosis during follow-up (median of 3.4 months),[7] although it is unclear whether jugular vein rerouting was advantageous or presented lower long term morbidity and mortality.[9] Our patient progressed well, with complete improvement from clinical symptoms and partial thrombosis resolution based on imaging.

To sum up with, children on immunosuppressants are more susceptible to developing infection and related complications. LS is a condition to consider in patients with upper respiratory tract bacterial infection of atypical progression. Individuals with LS must be provided with ample antimicrobial protection to as to prevent potentially severe neurological conditions and lung complications.

REFERENCES

1. Beukelman T, Patkar NM, Saag KG, Tolleson-Rinehart S, Cron RQ, DeWitt EM, et al. 2011 American College of Rheumatology recommendations for the treatment of juvenile idiopathic arthritis: initiation and safety monitoring of therapeutic agents for the treatment of arthritis and systemic features. Arthritis Care Res (Hoboken). 2011;63(4):465-82.
2. Ringold S, Weiss PF, Beukelman T, DeWitt EM, Ilowite NT, Kimura Y, et al. 2013 update of the 2011 American College of Rheumatology recommendations for the treatment of juvenile idiopathic arthritis: recommendations for the medical therapy of children with systemic juvenile idiopathic arthritis and tuberculosis screening among children receiving biologic medications. Arthritis Care Res (Hoboken). 2013 Oct;65(10):1551-63-512.
3. Actemra® (tocilizumabe) [Internet]. Rio de Janeiro (RJ): Roche Químicos e Farmacêuticos S.A.; 2013; [cited 2018 may 23]. Available from: http://www.anvisa.gov.br/datavisa/fila_bula/frmVisualizarBula.asp?pNuTransacao=2183002013&pIdAnexo=1539068
4. Ilaris® (canaquinumabe) [Internet]. São Paulo (SP): Novartis; 2015; [cited 2018 may 23]. Available from: http://www.anvisa.gov.br/datavisa/fila_bula/frmVisualizarBula.asp?pNuTransacao=10367962015&pIdAnexo=2968120
5. Karkos PD, Asrani S, Karkos CD, Leong SC, Theochari EG, Alexopoulou TD, et al. Lemierre's syndrome: a systematic review. Laryngoscope. 2009 Aug;119(8):1552-9.
6. Bahall M, Giddings S, Bahall K. Lemierre's syndrome: forgotten, but not absent. BMJ Case Rep. 2017;bcr2017-221203. DOI: https://doi.org/10.1136/bcr-2017-221203
7. Rebelo J, Nayan S, Choong K, Fulford M, Chan A, Sommer DD. To anticoagulate? Controversy in the management of thrombotic complications of head & neck infections. Int J Pediatr Otorhinolaryngol. 2016;88:129-35.
8. Petty RE, Southwood TR, Manners P, Baum J, Glass DN, Goldenberg J, et al. International League of Associations for Rheumatology classification of juvenile idiopathic arthritis: second revision. J Rheumatol. 2004 Feb;31(2):390-2.
9. Schubert AD, Hotz MA, Caversaccio MD, Arnold A. Septic thrombosis of the internal jugular vein: Lemierre's syndrome revisited. Laryngoscope. 2015 Apr;125(4):863-8.
10. Phua CK, Chadachan VM, Acharya R. Lemierre syndrome-should we anticoagulate? A case report and review of the literature. Int J Angiol. 2013 Jun;22(2):137-42.