Residência RP Pediátrica
Publicação Oficial da Sociedade Brasileira de Pediatria
ISSN-Online: 2236-6814

Submitted on: 11/28/2018
Accepted on: 02/26/2019

CASE REPORT

A case of neonatal rhabdomyoma seen at HC-UFTM

Thaís Verginio Geraldelli Morais[1], Thainá Verginio Geraldelli[2], Giovanna Rossi Ferreira Gonçalves[3], Fabiana Galdino Barsam[4], José Geraldo Ferreira Gonçalves[5]

Keywords:
Early Diagnosis, Fetal Diseases, Rhabdomyoma.

Abstract

Heart tumors are a rare condition, with an incidence of approximately 0.01% in the general population. Rhabdomyomas are the most frequent tumors in the newborn and children. This paper aims to report a case of a 38-week and 6-day-old newborn with an intracardiac tumor without hemodynamic repercussion, in order to discuss the importance of fetal morphological ultrasound screening and echocardiography in the diagnosis and follow-up of cardiac tumors.

[1] Hospital de Clínicas da UFTM, Residencia de Unidade Intensiva Pediatrica - Uberaba - Minas Gerais - Brazil.
[2] UFT - Universidade Federal de Tocantins, Medicicina - Palmas - Tocantins - Brazil.
[3] UNIMAR - Universidade de Marília ABC, Medicina - Marilia - Sao Paulo - Brazil.
[4] Hospital de Clinicas UFTM, UTI Pediatrica - Uberaba - Minas Gerais - Brazil.
[5] Hospital de Clínicas da UFTM, Cardiologia - Uberaba - Minas Gerais - Brazil.

Correspondence to:
Thaís Verginio Geraldelli Morais
UFTM - Universidade Federal do Triângulo Mineiro. Rua Frei Paulino, nº 30, Nossa Senhora da Abadia. Uberaba - MG. Brazil. CEP: 38025-180. E-mail: thaisvgeraldelli@hotmail.com

INTRODUCTION

Rhabdomyomas (hamartomas) are the most common primary cardiac tumors in fetuses and children, representing over 60% of cases, followed by teratomas, fibromas, hemangiomas and myxomas.[1]

Approximately 90% of occurrences have multiple presentations and involve the ventricles more often than the atria (30%). Both ventricles are affected in the same frequency.[2,3]

Rhabdomyomas have generally benign evolution, with cases of regression still being reported in the prenatal period, particularly in the third trimester and progressive tumor shrinkage with complete resolution of more than 80% during childhood.[1,3,4]

Despite the low risk of prenatal complications, they are frequently associated with tuberous sclerosis (50% to 80%), which may change the prognosis of affected patients after birth.[1,3]

Diagnosis can be made, including in the fetus, using diagnostic imaging methods, mainly through ultrasound, echocardiography and magnetic resonance imaging.[1,3,4]

The treatment is most often expectant, without the need for pregnancy interruption or surgical approach. The latter being reserved for complicated cases with hemodynamic repercussions.[3,5]

OBJECTIVES

Discuss the importance of fetal morphological ultrasound screening and echocardiography in the diagnosis and follow-up of cardiac tumors.

CASE REPORT

RNT 38 weeks and 6 days of age, born by cesarean section, Apgar 9 and 9. Birth weight 3,310g.

Mother: 22 years old, diagnosed with congenital multiple arthrogryposis and stroke 8 months ago. G1P0A0, irregular prenatal care.

Negative serology.

Father with Bourneville tuberous sclerosis.

Fetal echocardiogram (last trimester): anatomically normal heart. Presence of two hyper refringent nodular images in the left ventricle, one below the aortic valve, suggestive of rhabdomyoma. Given the limit of test resolution, it was prudent to complement it with a transthoracic study of the newborn.

After birth, the newborn was well from the clinical point of view.

At 2 hours of age, a transthoracic echocardiogram was performed. The result was presence of a patent foramen ovale with a diameter of 2.3 mm; atria of normal diameter; normal ventricular atrium ratios, with the mitral and tricuspid valves having normal anatomical and functional aspects, with no change in blood flow dynamics.

Presence of four echo-dense and homogeneous nodules, located in the following regions: 1 - right ventricular outflow tract, approximately 6.3 mm x 8.1 mm in size; 2 - anterolateral left ventricular wall (7.8 mm x 6.2 mm); 3 - inferior left ventricular wall (4.4 mm x 4.3 mm). (Figures 1, 2, 3 and 4)

The case report was presented to the head of the cardiology department, who advised on an expectant approach, considering that the child was cardiologically stable, since the visualized nodules did not cause obstruction in the ventricular inlet or outflow tract, not altering heart valve dynamics and not inducing arrhythmias.

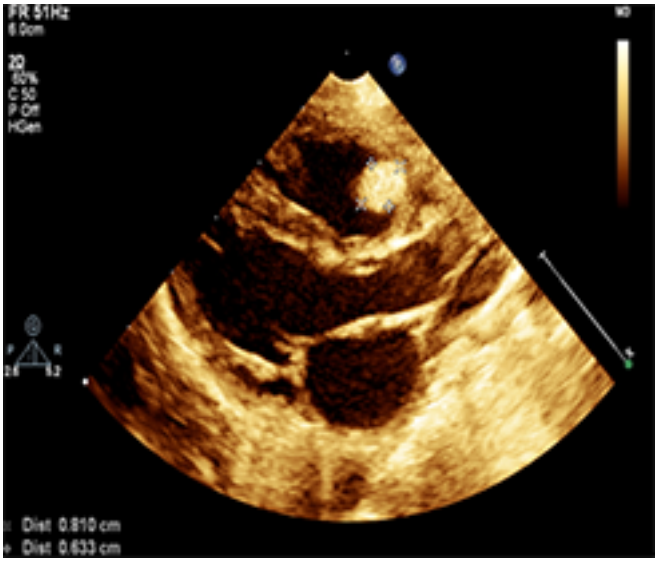

Figure 1. Tumor located in the right ventricle outflow tract.

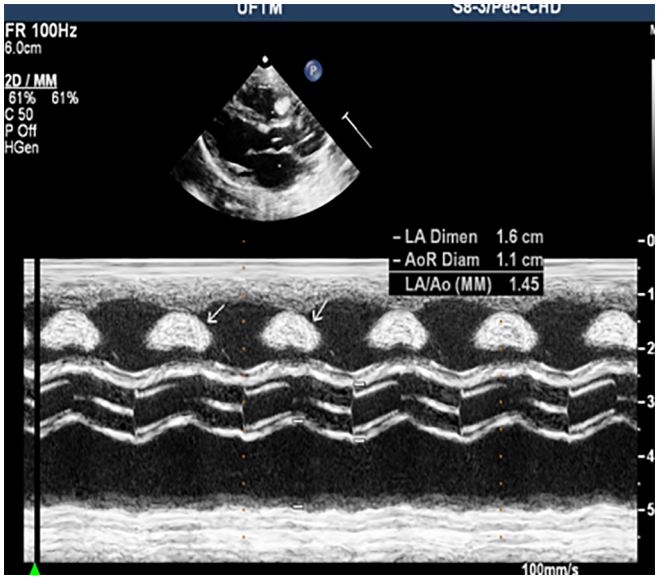

Figure 2. Tumor located in the right ventricle outflow tract.

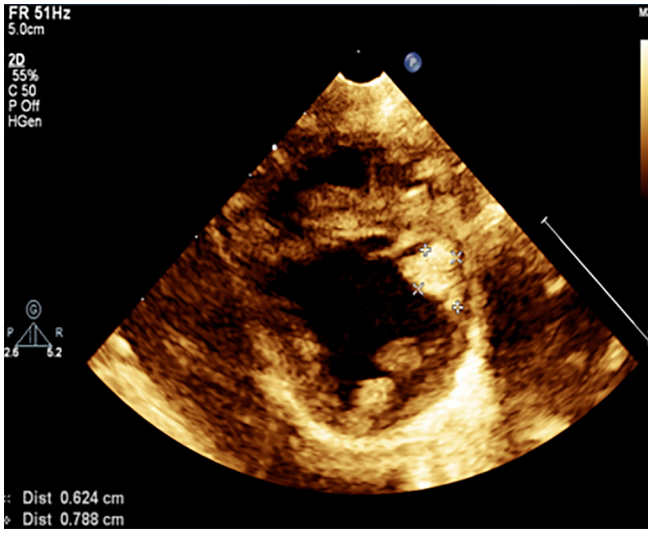

Figure 3. Tumors located in the anterolateral and inferior left ventricular wall

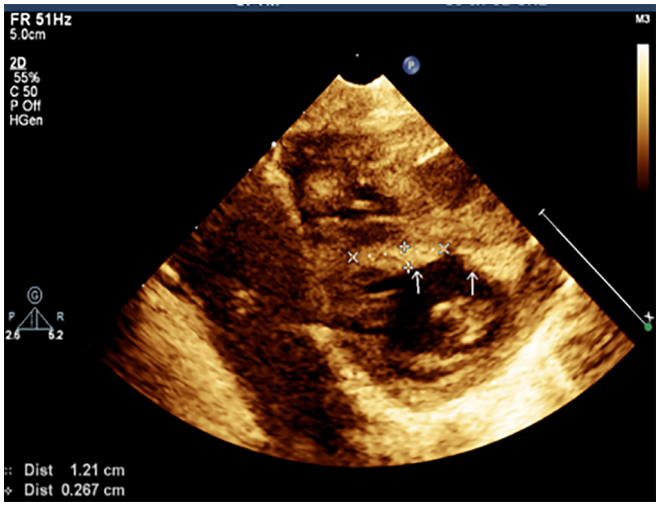

Figure 4. Tumors located in the anterolateral and inferior left ventricular wall

DISCUSSION

Primary heart tumors in children are rare. (apud Barbato 2012)[6]. described and incidence between 0.01% and 0.33% in autopsy findings; and (apud Barbato 2012)[6]. reported an incidence of 0.027 per 100 births, more than 90% being benign.[6]

Rhabdomyomas are the most common benign primary cardiac tumors in newborns and children, constituting 60 to 75% of cases, followed by teratomas, fibromas, hemangiomas and myxomas.[1,5]

They are presented as single, but usually there are multiple masses; they are hyper echogenic, of homogeneous texture, variable diameters and regular edges. The most common location is the ventricular myocardium (left and/or right), but they may originate in the atria, up to 50% of cases extend into the cardiac cavities and, more rarely, may be located in the interventricular septum, or on the atrial wall.[1,3].

In this case, the rhabdomyomas were in the right ventricular outflow tract, anterolateral and inferior left ventricular walls.

The definitive differential diagnosis of tumors is performed by biopsy, considered the gold standard; however, it is a high-risk invasive procedure and should be reserved for the most severe cases.[1]

In the case under discussion, the diagnosis of rhabdomyoma was based on echocardiographic findings.

Morphological obstetric ultrasound plays a fundamental role in the early detection of cardiac tumors in the fetus. They are usually detected in the second or third trimester of pregnancy, enabling the observation and morphological characterization of intracardiac masses in a non-invasive manner, also helping in the diagnosis of other primary heart tumors.[1,5]

The treatment is commonly expectant due to the possibility of spontaneous tumor regression even before birth, and the risk of complications is low. Tumor growth is often slow and spontaneous regression may occur possibly to apoptosis and loss of mitotic activity of tumor cells.[1]

In those cases where tumor (s) regression does not occur, the clinical picture will depend on the number of nodules, size and location, with more disturbances of heart rhythm, ventricular cavity obstruction, atrioventricular and/or semilunar valves, and because they are intramural, they rarely cause embolism.[1,6]

Arrhythmias are common complications and may occur in the prenatal and postnatal periods, often caused by compression or deformation of the electrical conduction pathways of the heart or due to the presence of tumor cells, acting as an anomalous conduction pathway.[1]

A cardiomyopathy called rhabdomyositis may occur, secondary to tumor infiltration into myocardial fibers and conduction tissue. It is a severe clinical condition and may progress to atrial arrhythmias, ventricular tachycardia and sudden death.[6]

In the present case, although four nodules were detected, they did not cause hemodynamically significant obstructions in the ventricular cavities, nor did they generate valve dysfunctions or cardiac rhythm disturbances. Therefore, we decided to follow it, only.

The association with other cardiac malformations is rare, but there are some cases described with Ebstein's anomaly, Fallot's tetralogy and left ventricular hypoplasia syndrome.[1,6]

Rhabdomyoma in the fetus may be the first signs of tuberous sclerosis, with other features such as mental retardation, epilepsy and facial angiofibromas.[6]

Tuberous sclerosis is an autosomal dominant genetic disease that predisposes to the formation of hamartomas in various organs and systems, especially in the heart, central nervous system, and kidneys.[1,4]

Finally, surgery is reserved only for patients with hemodynamic impairment due to mechanical obstructions and intractable arrhythmias caused by the tumor.[3,5]

CONCLUSION

This case report is interesting for pediatricians and neonatologists, especially to demonstrate the association of rhabdomyoma with tuberous sclerosis, as well as the good prognosis of cardiac tumors that involute in most cases. Genetic counseling is mandatory when there are family cases - case in point, with mandatory screening.

REFERENCES

1.Carvalho SRM, Marcolin AC, Cavalli RC, Crott GC, Mendes MC, Duarte G, et al. Rabdomiomas cardíacos fetais: análise de cinco casos. Rev Bras Ginecol Obstet. 2010;32(4):156-62.

2.Wage R, Kafka H, Prasad S. Cardiac rhabdomyoma in an adult with a previous presumptive diagnosis of septal hypertrophy. Circulation. 2008 Jun;117:469-70.

3.Karigyo CJT, Silva FBF. Tumores cardíacos: uma breve revisão da literatura. Rev Med Res. 2014 Jan/Mar;16(1):1-72.

4.Guimarães Filho HA, Araújo Junior E, Pires CR, Costa LLD, Nardozza LMM, Matar R. Diagnóstico pré-natal de rabdomioma cardíaco fetal pela ultrassonografia: relato de caso. Radiol Bras. 2009 Jun;42(3):203-5.

5.Rivera IR, Silva MAM, Gama HC, Cavalcanti RC. Tumores primários benignos do coração: mixoma e rabdomioma. Similaridades e diferenças: relatos de caso de duas malformações raras. Rev Bras Ecocardiogr Imagem Cardiovasc. 2010 Jul/Set;23(3):109-11.

6.Barbato A, Pinheiro EO, Cerri G, Cascudo MM, Machado MVL, Furtado M. Envolvimento tumoral do coração da criança e do feto. In: Croti UA, Mattos SS, Pinto Junior VC, Aiello VD, Moreira VM, eds. Cardiologia e cirurgia cardiovascular pediátrica. 2ª ed. São Paulo: Roca; 2012. p. 907-20.