Residência RP Pediátrica
Publicação Oficial da Sociedade Brasileira de Pediatria
ISSN-Online: 2236-6814

Submitted on: 02/20/2019
Approved on: 03/23/2020

CASE REPORT

Genital ambiguity in a 46,XY individual: case report

Jadi Colaço, Andressa Peche Tochetto[1], Amanda Milman Magdaleno[1], Carolina Perez Moreira[1], Tadiela Lodéa Rodrigues[2], Lionel Leitzke[3], Paulo de Jesus Hartmann Nader[1,4], Guilherme Guaragna Filho[4,5]

Keywords:
Disorders of Sex Development, Fetal Growth Retardation, Testis.

Abstract

Genital ambiguity is part of the disorders of sex development. Its prompt recognition and early and precise etiological investigation are fundamental to its proper management. A patient with ambiguous genitalia, born cesarean due to severe pre-eclampsia and oligohydramnios at 34 weeks and 2 days, 1505g, considered small for gestational age (SGA). Examination showed an 1.9cm falus, penoscrotal urethral meatus and bilaterally palpable gonads. In the investigation, he presented normal testosterone (T), androstenedione (A) and dihydrotestosterone (DHT); T/DHT ratio of 9.7 (<10) and T/A of 7.4 (>0.8) and karyotype 46,XY. It was decided for male sex assignment. Testosterone stimulus test was performed, showing penis enlargement of 1.5cm. Intrauterine growth restriction is a considerable risk factor for genital ambiguity in individuals 46,XY. This seems to be the etiology in this case, given its normal hormonal and cytogenetic evaluation and the response to the testosterone stimulus. Disorders of Sex Development, Fetal Growth Retardation, Testis.

[1] Brazilian Lutheran University (ULBRA), Medical School - Canoas - Rio Grande do Sul - Brazil.
[2] University Hospital of ULBRA, Psychology Service - Canoas - Rio Grande do Sul - Brazil.
[3] University Hospital of ULBRA, Pediatric Surgery Service - Canoas - Rio Grande do Sul - Brazil.
[4] University Hospital of ULBRA, Pediatric Service- Canoas - Rio Grande do Sul - Brazil.
[5] Federal University of Rio Grande do Sul (UFRGS), Medical School, Pediatric Department- Porto Alegre - Rio Grande do Sul - Brazil.

Correspondence to:
Jadi Colaço.
Universidade Luterana do Brasil (ULBRA). Av. Farroupilha, 8001 - São José, Canoas - RS, Brasil. CEP: 92425-020. E-mail: jadi.ulbra@gmail.com

Residência Pediátrica; 2020: Ahead of Print. DOI: 10.25060/residpediatr-2020.v10n3-104

This work is licensed under a Creative Commons Attribution 4.0 International License.

INTRODUCTION

Genital ambiguity is one of the clinical presentations of disorders of sex differentiation (DSD), formerly known as intersex or hermaphroditism. These are congenital conditions in which chromosomal, gonadal and/or anatomical sex development is atypical[1]. In this context, DSD with karyotype 46, XY is a quite challenging condition because, even with a range of possible etiological causes, 30 to 40% of these cases do not yet have a determined genetic cause[1,2].

In addition, ambiguous genitalia in DSD 46, XY can present in different degrees. As a result, the prompt recognition of this condition, as well as its early and accurate etiological investigation is essential for its proper management, avoiding inadequacies regarding the sex in which the child will be raised[1,3].

CASE REPORT

Patient born by C-section, with gestational age of 34 weeks and 2 days, due to severe preeclampsia, with intrauterine growth restriction (IUGR) and oligohydramnios. He had an Apgar of 8/9 at birth, 37.5 cm in length and weighed 1,505g, considered Small for Gestational Age (SGA) according to the Battaglia and Lubchenco's curve[4]. The mother had a previous diagnosis of obesity (body mass index of 43.3 kg/m^2) and type 2 diabetes mellitus, which was treated with metformin and insulin during pregnancy. Gestational ultrasound indicated that the fetus was female. Upon initial examination, the fetus had genital ambiguity with a 1.9 cm falus, with chordee, penoscrotal urethral meatus and complete fusion of the labioscrotal protrusions; however, with a bifid aspect and without wrinkling or pigmentation; there was partial penoscrotal inversion and normal-sized gonads, which were palpable bilaterally (figure 1A). The External Masculinization Score (EMS) according to Ahmed and Cols[5] was 5.5. In addition, he had a single umbilical artery. In the investigation by the interdisciplinary team, he presented hormonal dosages within the expected ranges for this mini-puberty period (table 1) and 46, XY karyotype. After evaluation, the assistant team, together with the parents, decided to register him in the male gender. In outpatient follow-up, we performed a stimulus test with intramuscular testosterone cypionate, at a monthly dose of 40mg for 3 consecutive months, showing hyperpigmentation and an increase in penis size (now measuring 3.4 cm, figure 1B). Which as a good response. At 1 year and 10 months, we ran a stimulus test with β-HCG 1500 IU for 3 consecutive days and samples were collected 24 hours after the last injection. The patient had an adequate testosterone response (greater than 150ng/dl, table 1).

DISCUSSION

Genital ambiguity is the most serious disorder within the DSD spectrum, being classified as a medical emergency[1,3]. It is a rare condition, with its real global prevalence being controversial[3]. Depending on the cause, DSD can have repercussions throughout life, affecting not only the process of sexual differentiation, but also pubertal development in adolescence and fertility in adult life[1]. Recognition and management of ambiguous genitalia must occur immediately upon birth, the initial measure is the provisional filing of the civil registry and to explain the condition to the family. In this context, hormonal and cytogenetic exams are very important for the proper etiological diagnosis and consequent sex definition for the approval of the civil registry and surgical correction[1,6].

In the presented case, the karyotype testing did not identify chromosomal abnormality; thus, the patient was classified as a DSD 46, XY, as proposed by the 2006 consensus[1]. The etiological definition of genital ambiguity in these individuals

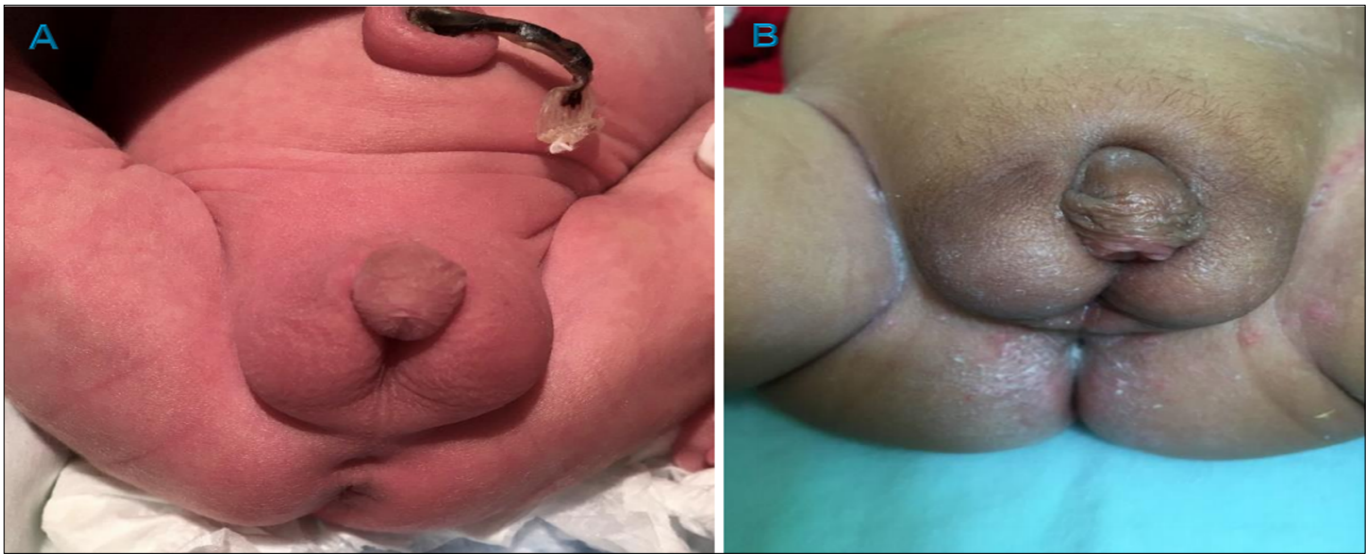

Figure 1. Individual's genitalia before the use of testosterone cypionate (A) and afterwards (B).

Table 1. Hormonal dosages in research.

	4 days of life	46 days of life	After β-HCG (660 days of life)
FSH (mUi/mL)*	1.45	3.99	
LH (mUi/mL)**	5.05	9.99	
Testosterone (ng/dL)	179.0	156.0	221.0
DHT (pg/mL)†	82.0		228.0
Androstenedione (ng/mL)	2.4		0.3
T/DHT§ ratio	21.83		9.7
T/A§§ ratio	0.746		7.4

*Follicle-Stimulating Hormone; **Luteinizing Hormone; †Dihydrotestosterone; §Testosterone/Dihydrotestosterone Ratio; §§ Testosterone/Androstenedione ratio.

is complex, since male sexual differentiation depends on a greater number of events than in females[3]. Among the most frequent causes of DSD 46, XY, the type 2 5α-reductase (D5αR2) deficiency stands out. In these patients, there is impaired testosterone (T) conversion to dihydrotestosterone (DHT); the type 3 17-β-hydroxysteroid dehydrogenase (D17βHD3) deficiency, which affects the conversion of androstenedione (A) to T; and the Partial Androgen Insensitivity Syndrome (PAIS), in which the problem is found in the androgen receptor. In addition to these, idiopathic cases also draw attention, incorporating a significant portion of the cases in which IUGR seems to have an important relationship with its cause[3].

In our case, hormonal measurements were performed during mini-puberty (first 3-4 months of life), as well as the stimulus test with β-HCG, as recommended by the consensus[1,6]. In this context, with the testosterone values within the normal range, as well as the palpable and topical gonads, the diagnosis of XY gonadal dysgenesis was discarded. Evaluating the relationship between the various androgens dosed after the stimulus test with β-HCG, the T/A ratio was greater than 0.8, excluding D17βHD3, and the T/DHT ratio was below 10, strongly suggesting that it was not D5αR2[7,8]. Furthermore, the patient presented a very good response to the testosterone stimulus (1.5 cm increase in penis size), which strongly signals against the PAIS hypothesis[9,10]. However, it is important to emphasize that molecular analysis remains the most accurate method for diagnosing the mentioned causes, but it is expensive and restricted to a few centers[11].

Therefore, with this hormonal profile, considering that during pregnancy there were factors that precipitate placental failure (oligohydramnios, preeclampsia and single umbilical artery) and the patient was born SGA, the most likely is that the condition is due to IUGR[2,12]. Studies suggest that placental insufficiency in the first trimester of pregnancy (when the entire sexual differentiation process occurs), leads to an inadequate HCG secretion, essential to stimulate fetal Leydig cells during this period, resulting in insufficient production of testosterone and, for that reason, DHT[12–14]. The latter is essential to induce differentiation in the male external genitalia[11].

On the other hand, in addition to the IUGR, the mother had diabetes during pregnancy. Within this framework, studies suggest that diabetes during gestation can also generate placental dysfunction, affecting the fetal hormonal balance[15]. However, it is unlikely that this disease is linked to the main etiology of the condition, because in these cases newborns have macrosomia, being considered Large for Gestational Age (LGA).

The relevance of this case lies not only in its rareness, but also in the difficulty of its management. The psychosocial consequences related to DSD with inadequate approach can be catastrophic. To avoid this, it is necessary that the individual with DSD and his family are followed-up by a multidisciplinary team experienced in this subject[1,3,6].

REFERENCES

1. Lee PA, Houk CP, Ahmed SF, Hughes IA, International Consensus Conference on Intersex organized by the Lawson Wilkins Pediatric Endocrine Society and the European Society for Paediatric Endocrinology. Consensus Statement on Management of Intersex Disorders. International consensus conference on interesex. Pediatrics. 2006 Ago;118(2):e488-500.
2. Poyrazoglu S, Darendeliler F, Ahmed SF, Hughes I, Bryce J, Jiang J, et al. Birth weight in different etiologies of disorders of sex development. J Clin Endocrinol Metab. 2017 Mar;102(3):1044-50.
3. De Paula G, Barros BA, Carpini S, Tincani BJ, Mazzola TN, Guaragna MS, et al. 408 cases of genital ambiguity followed by single multidisciplinary team during 23 years: etiologic diagnosis and sex of rearing. Int J Endocrinol. 2016 Nov;2016:4963574.
4. Battaglia FC, Lubchenco LO. A pratical classification of newborn infants by weight and gestacional age. J Pediatr. 1967 Ago;71(2):159-63.
5. Ahmed SF, Khwaja O, Hughes IA. The role of a clinical score in the assessment of ambiguous genitalia. BJU Int. 2000;85(1):120-4.
6. Lee PA, Nordenström A, Houk CP, Ahmed SF, Auchus R, Baratz A, et al. Global disorders of sex development update since 2006: perceptions, approach and care. Horm Res Paediatr. 2016;85(3):158-80.
7. Ahmed S, Iqbal A, Hughes IA. The testosterone: androstenedione ratio in male undermasculinization. Clin Endocrinol (Oxf). 2000 Dez;53(6):697-702.
8. Mendonça BB, Batista R, Domenice S, Costa EM, Arnhold IJ, Russell DW, et al. Steroid 5α-reductase 2 deficiency. J Steroid Biochem Mol Biol. 2016 Out;163:206-11.
9. Burstein S, Grumbach MM, Kaplan S. Early determination of androgen--responsiveness is important in the management of microphallus. Lancet. 1979;2(8150):983-6.
10. Ishii T, Hayashi M, Suwanai A, Amano N, Hasegawa T. The effect of intramuscular testosterone enanthate treatment on stretched penile length in prepubertal boys with hypospadias. Urology. 2010;76(1):97-100.
11. Ahmed SF, Bashamboo A, Lucas-Herald A, McElreavey K. Understanding the genetic aetiology in patients with XY DSD. Br Med Bull. 2013;106:67-89.
12. Chen MJ, Macias CG, Gunn S, Dietrich J, Roth DR, Schlomer B, et al. Intrauterine growth restriction and hypospadias: is there a connection?. Int J Pediatr Endocrinol. 2014 Out;2014(1):20.
13. Toufaily MH, Roberts DJ, Westgate MN, Hunt AT, Holmes LB. Hypospadias, intrauterine growth restriction, and abnormalities of the placenta. Birth Defects Res. 2018;110(2):122-7.
14. Yinon Y, Kingdom JC, Proctor LK, Kelly EN, Salle JL, Wherrett D, et al. Hypospadias in males with intrauterine growth restriction due to placental insufficiency: the placental role in the embryogenesis of male external genitalia. Am J Med Genet A. 2010 Jan;152A(1):75-83.
15. Arendt LH, Lindhard MS, Henriksen TB, Olsen J, Cnattingius S, Petersson G, et al. Maternal diabetes mellitus and genital anomalies in male offspring: a nationwide cohort study in 2 Nordic countries. Epidemiology. 2018 Mar;29(2):280-9.