Residência RP Pediátrica
Publicação Oficial da Sociedade Brasileira de Pediatria
ISSN-Online: 2236-6814

Submitted on: 06/28/2020
Approved on: 07/01/2020

CASE REPORT

Radiological findings in a school-age child and an adolescent with COVID-19

Luiz Felipe Queiroz Bichara Chicri[1], Bruna Mello Modugno Nunes[1], Maria de Fatima Pombo Sant'Anna[1]

Keywords:
Chest Radiography, Preschool, Coronavirus Infections, Tomography.

Abstract

Cases report of two pediatric patients - 6 and 14 years - with radiological manifestations caused by SARS-CoV-2. The most important alterations were: peripheral and round shape infiltrations. Both were hospitalized and improved.

[1] Martagão Gesteira Institute of Pediatrics and Childcare, Pediatric Pulmonology - Rio de Janeiro, Rio de Janeiro - Brazil.

Correspondence to:
Luiz Felipe Queiroz Bichara Chicri
Instituto de pediatria e puericultura Martagão Gesteira
Rua Bruno Lobo, 50 - Cidade Universitária da Universidade Federal do Rio de Janeiro, Rio de Janeiro - RJ, Brazil. CEP: 21941-912. E-mail: lfchicri@gmail.com

Residência Pediátrica; 2020: Ahead of Print.
DOI: 10.25060/residpediatr-2020.v10n3-361

This work is licensed under a Creative Commons Attribution 4.0 International License.

INTRODUCTION

Infection by SARS-CoV-2 produces inflammatory response consistent with the host's innate and adaptive immune systems. The viral load to which patients are exposed and the degree of lung injury also affect the severity of involvement. Some studies have described the immature nature of the innate and adaptive immune system of children and the ensuing lower level of production of cytokines as a protective factor. However, the decreased susceptibility to severe disease observed in pediatric patients has not been entirely explained[1].

Diagnosis is based chiefly on clinical and epidemiological findings. Additional workup is recommended for unstable patients requiring hospitalization[2-4].

As in other viral respiratory conditions, X-ray findings range from inexistent to mild in the early stages of COVID-19. Patients present first with low-density infiltrates, while consolidations appear in later in the course of the disease. When indicated, chest computed tomography (CT) scans allow for enhanced visualization. The main alterations are peripheral irregular ground glass opacities; round-shaped peripheral consolidations appear less often; reversed halo sign; mosaic perfusion; and mild irregular opacity, affecting preferentially the subpleural area, the inferior lobes, and more than one lobe bilaterally[1-3,5].

Case #1:

A girl aged six years with chronic encephalopathy presented with signs of respiratory infection developing for four days, without wheezing but with signs of respiratory effort. Her oxygen saturation level was 88%. Chest x-ray images (Figure 1) revealed a diffuse interstitial pattern, while CT scans showed consolidation in the middle third of the right lung (Figure 2) and unilateral peripheral nodular consolidations in the right lung (Figure 3). The patient was admitted to the intensive care unit and was discharged more than 15 days later after improving from her condition. She tested positive for infection by SARS-CoV-2.

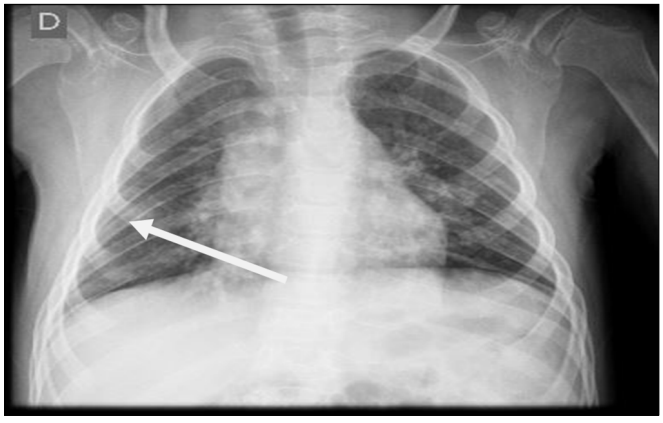

Figure 1. Chest X-ray: diffuse interstitial infiltrate and hilar and paracardiac hypotransparency.



Figure 2. Chest CT: consolidation in the middle third of the right lung.

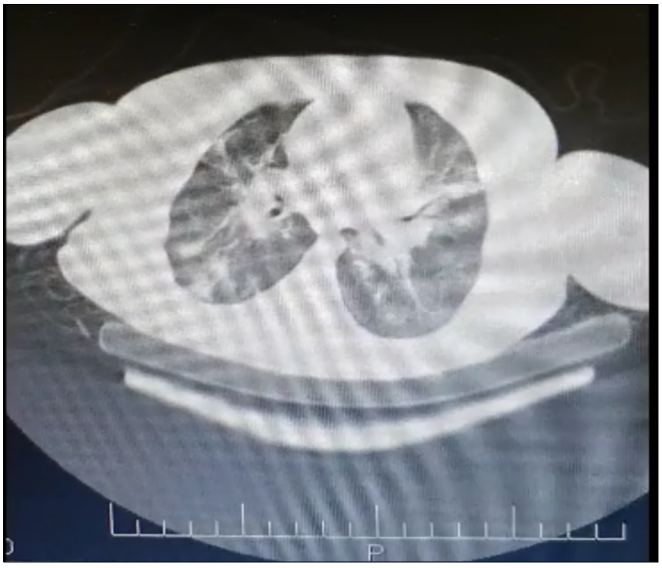

Figure 3. Chest CT: peripheral nodular consolidations in the right lung.

Case #2:

A 14-year-old adolescent with asthma under control was brought to our service after having difficulty breathing for three days, He presented with mild wheezing and coughing. His oxygen saturation level was 89%. The patient was admitted to the intensive care unit and was discharged five days later after improving from his condition. His CT scans (Figures 4 and 5) had alterations in the form of ground glass infiltrates located primarily in the subpleural area. His PCR test was positive for SARS-CoV-2.

DISCUSSION

Imaging alterations described for COVID-19 in the literature usually become evident on the fourth day of disease. CT scan alterations may progress rapidly in infected children

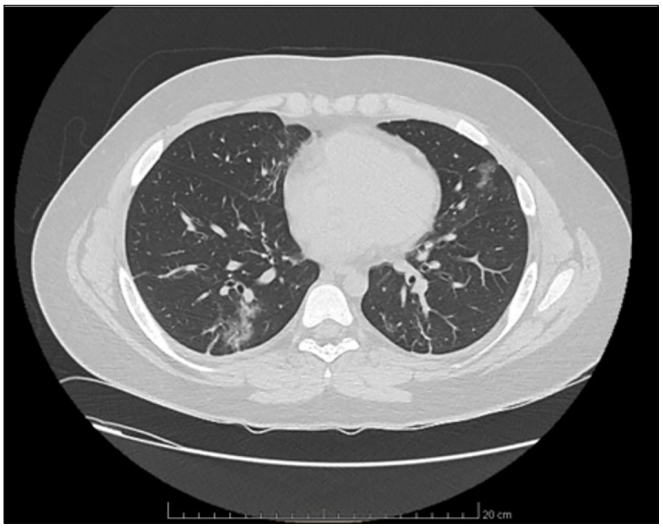

Figure 4. Chest CT: infiltrated in subpleural frosted glass on the right.



Figure 5. Chest CT: infiltrated in subpleural frosted glass on the right.

from multiple bilateral irregular ground glass opacities and/or peripheral infiltrates in the middle third of the lungs. Unilateral and bilateral nodular consolidations and the reversed halo sign have been described. Air bronchogram may be seen from the fifth to the eighth day of disease, and denser consolidations with parenchymal bands from the ninth to the thirteenth day of disease. These alterations may persist for months after the patient has recovered clinically[2,4,5].

Chest x-rays may come out normal or present unilateral or bilateral lobar subpleural hypotransparency[3,4].

CONCLUSION

The radiological findings seen in the cases reported herein are consistent with the ones described in international literature, in which children and adults were described as having similar images. However, after analyzing the images of 34 children with COVID-19 seen in four hospitals in China, Zhang et al. described mostly irregular high-density opacities and only a few cases of ground glass opacity in CT scans. The lower prevalence of severe cases of COVID-19 among pediatric patients calls for the organization of additional studies to establish the radiological findings more frequently seen in this population[1,5].

REFERENCES

1. Sociedade Brasileira de Pediatria. COVID-19 em crianças: envolvimento respiratório [Internet]. Rio de Janeiro (RJ): SBP; 2020; [Acesso em: 2020, Junho, 20]. Disponível em: https://www.sbp.com.br/imprensa/detalhe/nid/covid-19-em-criancas-envolvimento-respiratorio/
2. Zhang C, Gu J, Chen Q, Deng N, Li J, Huang L, et al. Clinical and epidemiological characteristics of pediatric SARS-CoV-2 infections in China: a multicenter case series. PLoS Med. 2020 Jun;17(6):e1003130. DOI: https://doi.org/10.1371/journal.pmed.1003130
3. Araujo Filho JAB, Sawamura MVY, Costa NA, Cerri GG, Nomura CH. Pneumonia por COVID-19: qual o papel da imagem no diagnóstico?. J Bras Pneumol. 2020 Mar;46(2):e20200114. DOI: https://dx.doi.org/10.36416/1806-3756/e20200114
4. Chate RC, Fonseca EKUN, Passos RBD, Teles GBS, Shoji H, Szarf G. Apresentação tomográfica da infecção pulmonar na COVID-19: experiência brasileira inicial. J Bras Pneumol. 2020 Mar/Abr;46(2):e20200121. DOI: https://dx.doi.org/10.36416/1806-3756/e20200121
5. Farias LPG, Strabelli DG, Sawamura MVY. Pneumonia por COVID-19 e o sinal do halo invertido. J Bras Pneumol. 2020 Mar/Abr;46(2):e20200131. DOI: https://dx.doi.org/10.36416/1806-3756/e20200131