Residência RP Pediátrica
Publicação Oficial da Sociedade Brasileira de Pediatria
ISSN-Online: 2236-6814

Submitted on: 09/01/2020
Approved on: 09/09/2020

INTERACTIVE CLINICAL CASE

Pulmonary manifestation of a common, but frequently neglected disease: what is your diagnosis?

Adriana Paiva de Mesquita[1], Alexandre Aredo Castiglione[2], Silvia Montesanto[3], Marcela Rocha[4], Solange David[5], Daniela Rabelo[6], Patricia Torre[7], Adriane Cruz[7], Juliana Riscado[8], Miriam Capetti[9], Tatiana Fazecas[10]
Organizer: Sandra Mara Amaral*

16-year-old male patient, resident in Pavuna, RJ. Main complaint: fever, vomiting, and abdominal pain.

Medical history

In April 2019, he started with an acute condition with fever (not measured), abdominal pain and vomiting. He was medicate with symptomatic drugs. In 48 hours there was worsening and the patient had pain in the calves, a drop in his overall health condition, jaundice, and cough with hemoptysis. Hospitalization was indicated, with a dose of ceftriaxone, venous hydration and symptomatic drugs.

On April 29 he was transferred to a referral hospital for infectious diseases. The patient reported that the condition started after having plunged into a ditch near his residence, full of water after heavy rains.

Physical exam

W: 56Kg, H: 173cm, BMI: 19.3, O_2 saturation in ambient air: 97%, AxT: 38.3 ° C, BP: 130x80mmHg. The patient was prostrated, jaundiced 3+/4, hydrated and with good capillary perfusion. BR: 20bpm, lung auscultation with decreased breath sounds and snoring in both hemi-chests. Normal heart auscultation HR: 88bpm. Flabby abdomen with palpable liver at 2cm RCB. Normal peristalsis. Pain on palpation of lower limbs.

Initial laboratory tests (see Table 1).

1. Given the clinical picture, which antibiotic would be the first choice for the treatment of this patient?

A. Ceftriaxone.
B. Ciprofloxacin.
C. Crystalline penicillin.
D. Azithromycin.
E. Vancomycin.

Mild cases of leptospirosis may be treated with ampicilin, amoxycilin, erythromycin, and cephalosporin. Severe cases must be hospitalized and treated with high doses of crystalline penicillin 200-250000UI/kg/day for 7-14 days[1].

[1] Head of the Pediatric Pulmonology Service Hospital Municipal Jesus/Prof Auxiliar de Saúde da Criança and Adolescent UNESA.
[2] Hebiatrician at Hospital Municipal Jesus.
[3] Pediatrician at Hospital Municipal Jesus.
[4] Pediatrician at the HMJ Adolescent Infirmary.
[5] Doctor in Medicine by UFRJ/ Assistant Professor of Health for children and adolescents UNESA.
[6] Pediatric Pulmonologist at Hospital Municipal Jesus.
[7] Pediatric Infectologist Hospital Municipal Jesus.
[8] R4 of Pediatric Pulmonology at Hospital Municipal Jesus.
[9] Pediatric Radiologist at HMJ. 10 Head of the Pediatric Radiology Service at HMJ.
[10] Head of the Pediatric Radiology Service at HMJ.
* Pediatrician. Retired. Federal Hospital of State Servants. Rio de Janeiro - RJ.

Correspondence to:
Adriana Paiva de Mesquita.
Hospital Municipal Jesus. Rua Oito de Dezembro, nº 717, Vila Isabel, Rio de Janeiro, RJ, Brazil. CEP: 20550-200. E-mail: dricapneumo@gmail.com

DOI: 10.25060/residpediatr-2021.v11n1-02

This work is licensed under a Creative Commons Attribution 4.0 International License.

Table 1. Insert description.

Hematocrit %	32.6
Hemoglobin g/dl	10.6
Leukocytes/mm^3 w/differential %	11800 – 0/0/0/0/1/79/10/10
Platelets/mm^3	61900
PCR mg/dl	195
Urea mg/dl	69
Creatinine mg/dl	1,6
Na mEq/l	133
K mEq/l	3,3
Glucose mg/dl	126
Total bilirubin mg/dl	9,79
Indirect bilirubin mg/dl	5,7
Total bilirubin mg/dl	4,1
Total proteins g/dl	6,2
TGP U/l	93
TGO U/l	252
Alkaline phosphatase U/l	334
LDH U/l	785
Amylase U/l	104

The chest X-ray showed an infiltrate in the lingual of lung and lower lobes with an oval, hyperaerated image, identified only in the lateral view, which may correspond to the cavity by a specific process. Normal cardiac silhouette. Free costophrenic sinuses. X-ray and computed tomography (CT) images are missing (Figure 1).

The high-resolution chest computed tomography showed (Figure 2):

- Small areas with sparse and bilateral ground glass attenuation, predominantly peripheral and more evident in the anterior segments of the right upper lobe and in the middle lobe, with the rest of the pulmonary parenchyma with attenuation values within normal limits;
- No bronchiectasis nor pleural effusion;
- Normal trachea and bronchi;
- No mediastinal masses nor hilar lymph node enlargements;
- Aorta and pulmonary arteries with normal course and gauges;
- Normal heart volume.

Serologies for toxoplasmosis, rubella, hepatitis A and B were negative. Serology for cytomegalovirus (CMV) was reagent only for IgG. The purified protein derivative (PPD) was non-reactor. Sputum BAAR screening was negative in 2 samples.

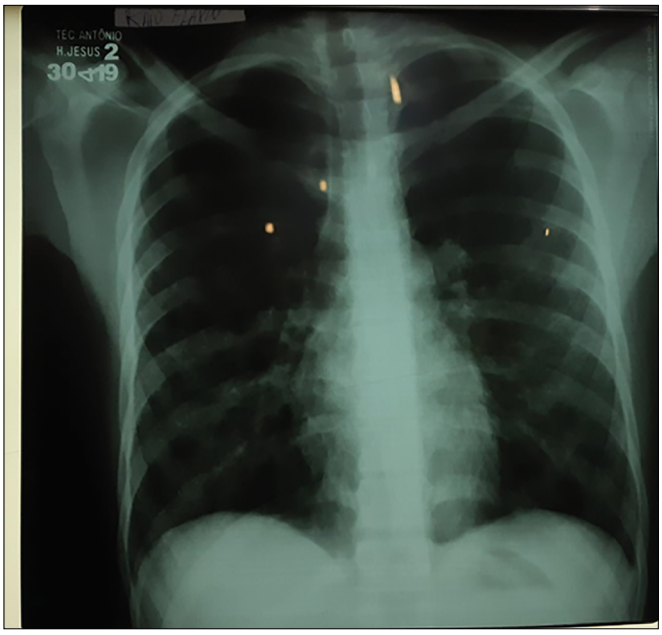

Figure 1. Chest X-ray: infiltrate in the lingula and lower lobes.



Figure 2. Chest tomography: Small areas with bilateral sparse ground-glass attenuation.

Progress

The patient improved with penicillin, being discharged on the 14th day. Outpatient review in 1 month with clinical and radiological improvement (Table 2).

The microscopic agglutination test (MAT) was positive, confirming the diagnosis of leptospirosis.

2. About the epidemiology of leptospirosis, it can be said that:

A. Pathogenic leptospira species were isolated from bats and pinnipeds.

Table 2. Insert description.

	2/05	03/05	7/05	08/05	10/05
Urea mg/dl	69		40	26	31
Creatinine mg/dl	1,6		0,6	0,8	0,9
Na mEq/l	133		136	135	140
K mEq/l	3,3		4,18	3,5	4,9
Glucose mg/dl	126				
Total bilirubin mg/dl	9,79		16,6	4,66	2,73
Indirect bilirubin mg/dl	5,7				
Direct bilirubin mg/dl	4,1		9,1	3,0	2,1
Total proteins g/dl	6,2			7,3	
TGP U/l	93		99	110	
TGO U/l	252		233	63	
Alkaline Phosphatase U/l	334		384	376	502
Gamma-glutamyltransferase				90	
LDH U/l	785			610	
Amylase U/l	104				
Leukocytes /mm^3 c/ differential %		13200-5/0/0/1/63/17/14		14600 0/6/0/0/3/59/22/10	10100 0/7/0/0/1/55/23/14
Hematocrit %		34,9		34,1	
Hemoglobin g/dl		11,1		10,8	
Platelets / mm^3		143000		541000	754000
TAP		10,3		12,4	
PTT		27		28,8	
INR		0,93		1,12	

B. Human-to-human transmission has not been described.

C. Leptospira is only isolated from homeothermic animals.

D. Leptospira colonizes the renal glomeruli of the reservoirs.

E. NOA.

Small mammals, especially rodents, are the main reservoirs, but large herbivores and domestic animals, such as dogs, are important additional sources of infection. Leptospires have also been isolated from bats and pinnipeds such as seals, sea lion, walruses, and others[2].

Leptospires have already been isolated in poikilothermic, such as toads and frogs, and it is possible that amphibians play a role in the circulation of leptospires in the environment[2].

Although rare, inter-human transmission can occur during sex and during lactation. When it occurs in pregnancy, it can result in miscarriage or stillbirth[2].

After penetrating the host, through hematogenous dissemination, leptospira reaches the peritubular glomeruli and capillaries, and from there they reach the renal tubules, where they colonize the brush border of the proximal tubules, and can persist for a long time[2,3].

3. What manifestation is considered a landmark of the immune phase of the anicteric form?

A. Cardiac arrhythmia.
B. Renal failure.
C. Pneumonitis.
D. Hepatic cysts.
E. Aseptic meningitis.

Ninety percent or more of patients have the anicteric form of leptospirosis. Often the definitive diagnosis is not made, because jaundice and azotemia are not present[4].

The anicteric disease can be biphasic, with an initial septicemic phase characterized by fever, chills, malaise, headache, severe myalgia, abdominal pain, and prostration, lasting 4 to 7 days. The 2nd (immune) phase, which begins in the 2nd week, is characterized by fever, uveitis, rash, headache, and aseptic meningitis, which is the hallmark of this phase[4].

Persistent or recurrent headache after the end of the septicemic phase indicates the onset of meningitis. Hemorrhagic complications are usually associated with the icteric disease only, but conjunctival suffusions or conjunctival hemorrhage accompanied by photophobia and eye pain can be present in the anicteric form and are useful diagnostic signs[4].

Some anicteric patients do not have biphasic disease and remain asymptomatic after the 1st week[4].

4. What is the correct statement in relation to laboratory tests for leptospirosis?

A. Leptospira can be isolated from blood, cerebrospinal fluid and urine in the first week of illness
B. The microscopic agglutination test is the gold standard with a response obtained within 24 hours
C. The dual path platform (DPP) is a rapid test for diagnostics[5].
D. Leukopenia is the predominant finding in the blood count.
E. Creatine phosphokinase elevation occurs in all stages of the disease.

Blood cultures should be collected as early as possible after the patient's presentation. Leptospiremia occurs before the onset of symptoms and drops at the end of the 1st week of acute illness, after defervescence and clinical improvement. Other samples that can be used for culture in the 1st week of illness are the cerebrospinal fluid (CSF) and the peritoneal dialysate[2,4].

Urine should be cultured after the 2nd week of symptoms. Leptospiruria usually occurs in the immune phase of the disease, it can last up to 1 month and it is not affected by antibiotic therapy[2,4]. The microscopic agglutination test (MAT) is considered the gold standard for diagnosis, but it does not enable early diagnosis of the disease.

The dual path platform is an assay that uses high concentrations of recombinant immunoglobulin-like protein as an antigen. It has similar sensitivity to IgM-ELISA and high specificity. It can be done using the blood obtained by finger pricking as a sample. It is a reliable test for the early diagnosis of human leptospirosis, especially in severe cases[5].

The leukogram may be normal or show leukocytosis, sometimes with leukemoid reaction (up to 70,000 leukocytes/mm^3).[6] Thrombocytopenia and anemia are common. The presence of leukopenia in the context of anemia and thrombocytopenia may suggest bone marrow suppression[2].

Creatine phosphokinase levels are increased only in the 1st stage of the disease[6].

5. Among the abdominal manifestations of leptospirosis in children we can mention:

A. Acousculous cholecystitis.
B. Enterocolitis.
C. Peritonitis.
D. Subphrenic abscesses.
E. Intestinal obstruction.

Gastrointestinal symptoms are common and include nausea, vomiting, diarrhea and abdominal pain[2]. Abdominal pain may be due to acutely cholecystitis and/or pancreatitis. It is important to remember that decreased kidney function can raise the level of pancreatic enzymes when the clearance is less than 50ml/min[2].

6. What are the tomographic manifestations of pulmonary leptospirosis?

A. Frosted glass opacity.
B. Airspace nodules.
C. Crazy-paving.
D. Septal thickening.
E. All of the above.

The lungs can be affected in the anicteric and icteric forms. Severe pulmonary impairment in leptospirosis consists primarily of hemorrhagic pneumonitis. In advanced cases, adult respiratory distress syndrome and diffuse alveolar hemorrhage can occur with significant mortality[7].

The diffuse alveolar hemorrhage syndrome (DAHS) consists of anemia, due to bleeding from the pulmonary microvasculature to the alveolus, hemoptysis, and bilateral alveolar opacity. It is interesting to note that in papers on DAHS, leptospirosis in general is not mentioned in the differential diagnosis, although it is a disease with a high incidence and significant morbidity[7].

Von Ranke et al. (2016)[7] published an article about 16 patients with pulmonary leptospirosis and diffuse alveolar hemorrhage. The most common HRCT findings were ground-glass opacity and airspace nodules. Consolidations, crazy-paving pattern, and interlobular septal thickening were also reported. Bilateral pleural effusion was found in 2 patients.

CONCLUSIONS

Leptospirosis is a common, largely neglected disease. Although the majority of cases are mild, it can be severe, leading to the involvement of several organs, resulting in fatality. Anicteric forms, mainly, can be confused with other infectious conditions such as dengue. The presence of hemorrhagic suffusions is an important diagnostic clue.

The epidemiological history of the practice of aquatic recreational sports, certain professions, onset of the condition after heavy rains and floods can also contribute to increase suspicion.

REFERENCES

1. Aygün FD, Avar-Aydin PÖ, Çokuğraş H, Camicioğlu Y. Different clinical spectrum of leptospirosis. Turk J Pediatr. 2016;58(2):212-5.
2. Haake DA, Levett PN Leptospirosis in humans. Curr Top Microbiol Immunol. 2015;387:65-97.
3. Brito T, Silva AMG, Abreu PAE. Pathology and pathogenesis of human leptospirosis. Rev Inst Med Trop S Paulo. 2018;60:e23.
4. Nieves DJ. Leptospirosis. In: Cherry J, Demmler-Harrison GJ, Kaplan SL, Steinbach WJ, Hotez P, eds. Feigin and Cherry's textbook of pediatric infectious diseases. 8ª ed. Philadelphia: Elsevier; 2019. v. 2. p. 1256-66.e5.

5. Nabity AS, Hagan JE, Araujo G, Damião AO, Cruz JS, Nery N, et al. Prospective evaluation of accuracy and clinical utility of the dual path platform (DPP) assay for the point-of-care diagnosis of leptospirosis in hospitalized patients. Plos Negl Trop Dis. 2018;12(2):e0006285. DOI: https://doi.org/10.1371/journal.pntd.0006285

6. Fort GG. Leptospirosis. In: Ferri FF, ed. Ferri's clinical advisor. Philadelphia: Elsevier; 2020. p. 213.e15.

7. Von Ranke FM, Zanetti G, Escuissato DL, Hochhegger B, Marchiori E. Pulmonary leptospirosis with diffuse alveolar hemorrhage: high-resolution computed tomographic findings in 16 patients. J Comput Assist Tomogr. 2016 Jan/Fev;40(1):91-5.