Residência RP Pediátrica
Publicação Oficial da Sociedade Brasileira de Pediatria
ISSN-Online: 2236-6814

Submitted on: 03/12/2021
Approved on: 03/19/2021

DIAGNOSTIC CHALLENGE

Diagnostic challenge

Juliana Machado de Oliveira Caldas[1], Victoria Orenbuch[1], Leonardo Rodrigues Campos[2], Ivete Martins Gomes[3], Claudete Araújo Cardoso[4], Katia Lino[2], Alessandro Severo[5], Clarissa Canella[5,6]

Keywords:
Rheumatology,
Pediatric,
Radiology,
Tuberculosis,
Arthritis,
Reactive,
Infectous Disease.

Abstract

The patient, a 10-year-old female, was referred to the rheumatology clinic with a previous history of fever (39ºC), loss of appetite and polyarthritis of wrist, knees, and ankles. Symptoms were relieved only after using NSAIDs. After 6 months, the patient returned to our hospital with a 7-month history of weight loss and chronic arthritis (claudication and morning stiffness of 15 minutes) on ankles. Physical exam revealed suggestive signs of chronic arthritis with exuberant swelling and tenosynovitis of both ankles. Magnetic resonance imaging of ankles showed bilateral and symmetrical tibiotalar arthritis of extensors, flexors, and fibularis tendons. Right ankle synovial biopsy revealed no granulomas. Which is the most probably diagnostics?

[1] Federal University of Rio de Janeiro, Medical Student - Niteroi - Rio de Janeiro - Brazil.
[2] Antonio Pedro University Hospital, Pediatric Rheumatology Department- Niteroi - Rio de Janeiro - Brazil.
[3] Antonio Pedro University Hospital, Pediatric Infectology Service - Niterói - Rio de Janeiro - Brazil.
[4] Medical School, Federal University of Rio de Janeiro, Maternal-Children Department - Niteroi - Rio de Janeiro - Brazil.
[5] Antonio Pedro University Hospital, Radiology and Image Diagnostics Department - Niteroi - Rio de Janeiro - Brazil.
[6] CDPI, Image Diagnostics Clinic - Rio de Janeiro - Rio de Janeiro - Brazil.

Correspondence to:
Juliana Machado de Oliveira Caldas.
Universidade Federal Fluminense. Rua Marquês de Paraná, nº 303, Centro, Niterói, RJ, Brazil. CEP: 24220-000. E-mail: julianamocaldas@gmail.com

DOI: 10.25060/residpediatr-2021.v11n1-585

This work is licensed under a Creative Commons Attribution 4.0 International License.

DIAGNOSTIC CHALLENGE

A 10-year-old female patient referred to the rheumatology clinic with a previous history of fever (39°C), hyporexia and polyarthritis of the wrists, knees and ankles. Symptoms improved only with the use of NSAIDs. After six months, the patient returned to the clinic with a seven-month history of unmeasured weight loss and chronic arthritis (claudication and morning stiffness for 15 minutes) in the ankles. On clinical examination, she had signs suggestive of chronic arthritis with severe edema and tenosynovitis in both ankles. Magnetic resonance imaging of the ankles showed bilateral and symmetrical tibiotalar arthritis and of the extensor, flexor and peroneal tendons. Right ankle synovial biopsy revealed no granulomas. Which are the most probable diagnostics?

A) Dismissed diagnosis of TB, as the biopsy did not reveal granuloma
B) Rheumatoid arthritis
C) Myofascial Syndrome
D) Poncet's Disease
E) Polymyositis/juvenile dermatomyositis

Ankle tenossinovitis in the poncet disease

Poncet's disease or Poncet's arthropathy is a rare manifestation of tuberculosis infection without local invasion by the bacillus, and it is considered an immunological reaction to the bacillus protein[1,2]. The most typical clinical presentation is acute polyarthritis[3]. This case, in particular, illustrates a rare form of presentation of inflammatory tenosynovitis in a patient with a concomitant diagnosis of pulmonary tuberculosis, a 10-year-old teenager who was seen at the pediatric rheumatology clinic with a history of fever, hyporexia and polyarthritis in the wrists, knees and ankles[4].

In an emergency department, she was initially diagnosed with rheumatic fever due to the presence of acute polyarthritis associated with an increase in C-reactive protein (78.6 mg/L - reference value up to 10mg/L) and anti-streptolysin O (400 IU/mL - reference value <200 IU/ml) and was medicated with amoxicillin for 10 days; however, the patient maintained daily fever. Symptoms partially improved only with the use of non-hormonal anti-inflammatory drugs. After 6 months, the patient was referred to the pediatric rheumatology clinic with chronic hyporexia and oligoarthritis (>6 weeks of evolution) in the ankles, elbow and right wrist. On clinical examination, she had signs of chronic arthritis (pain, swelling, heat, and limited movement) in her ankles (figure 1 A). New laboratory tests showed ANF of 1:320, negative rheumatoid factor and alpha-1-acid glycoprotein of 171 mg /dL (reference value 44-113 mg/dL). She had an 18 mm PPD reaction (figure 1 B).

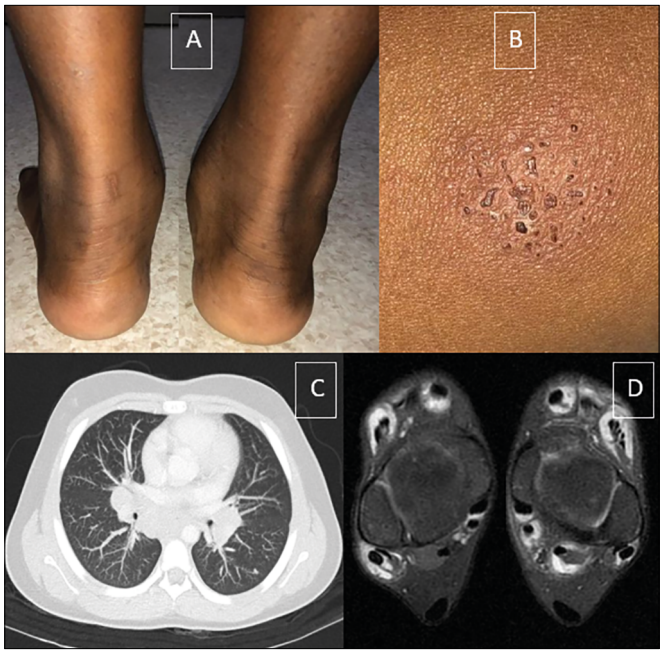

Figure 1. (A) Physical examination showing edema and signs of chronic arthritis in both ankles. (B) Strongly reactive tuberculin test (PPD). (C) Chest CT showing an infiltrative lesion in the posterior mediastinum, with bilateral hilar extension and multiple mediastinal and hilar lymph node enlargement. (D) Ankle MRI showing tenosynovitis of the extensor, flexor and fibularis tendons.

A chest CT scan revealed an infiltrative lesion in the posterior mediastinum, with bilateral hilar extension and multiple mediastinal and hilar lymph node enlargement, suggesting pulmonary tuberculosis (figure 1 C). Her ankle MRI showed bilateral and symmetrical tibiotalar arthritis and significant tenosynovitis of the extensor, flexor and fibular (figure 1 D). Right ankle synovial biopsy revealed absence of granulomas and her synovial fluid culture was negative for mycobacteria. The patient was treated with isoniazid, rifampicin, ethambutol and pyrazinamide and the symptoms completely resolved after two months of treatment.

REFERÊNCIAS

1. Sasaki H, Inagaki M, Shioda M, Nagasaka K. Poncet's disease with high titers of rheumatoid factor and anti-citrullinated peptide antibodies mimicking rheumatoid arthritis. J Infect Chemother. 2015 Jan;21(1):65-9.
2. Malaviya AN, Kotwal PP. Arthritis associated with tuberculosis. Best Pract Res Clin Rheumatol. 2003 Abr;17(2):319-43.
3. Silva I, Mateus M, Branco JC. Poncet's disease: a symmetric seronegative polyarthritis with enthesopathy refractory to the therapy. Acta Reumatol Port. 2013 Jul/Set;38(3):192-5.
4. Lugo-Zamudio GE, Barbosa-Cobos RE, González-Ramírez LV, Delgado-Ochoa D. Tuberculous rheumatism "Poncet's disease". Case report. Cir Cir. 2016 Abr;84(2):169-72.